

# Female genital tract tuberculosis presenting as ovarian cancer

Malihe Hasanzadeh, Hamid Reza Naderi<sup>1</sup>, Azamossadat Hoseine Hoshyar<sup>2</sup>, Shima Shabane<sup>3</sup>, Soodabeh Shahidsales<sup>4</sup>

Women Health Research center, Associate professor, Department of Gynecology Oncology, Ghaem Hospital, Mashhad University of Medical Sciences, Mashhad, Iran. <sup>1</sup>Surgical Oncology Research Center, Assistant professor in Infectious Diseases, Mashhad University of Medical Sciences, Mashhad, Iran. <sup>2</sup>Resident of Obstetrics and Gynecology, Ghaem Hospital, Mashhad University of Medical Sciences, Mashhad, Iran. <sup>3</sup>Medical student, Mashhad University of Medical Sciences, Mashhad, Iran. <sup>4</sup>Cancer Research Center, Omid Hospital, Faculty of Medicine, Mashhad University of Medical Sciences, Mashhad, Iran

**Background:** Tuberculosis (TB) is still a major worldwide concern. There is no pathognomonic clinical feature or imaging findings for definite diagnosis of extra pulmonary TB. Therefore, TB involvement of Gastrointestinal or Genitourinary tract can be easily confused with peritoneal carcinomatosis and advanced ovarian carcinoma. Our aim is to emphasize the importance of considering the disease based upon the epidemiologic clues of the patients, while interpreting the positive results for a suspicious ovarian malignancy. **Cases:** This paper illustrates 8 cases of ovarian or peritoneal tuberculosis, whose initial diagnoses were malignant processes of the GU tract. **Conclusion:** Tuberculosis (TB) should be always being considered in the differential diagnosis of advanced ovarian cancer, especially in the regions that are endemic for the disease.

**Key words:** Ovarian cancer, peritoneal tuberculosis, tuberculosis

**How to cite this article:** Hasanzadeh M, Naderi HR, Hoseine Hoshyar A, Shabane S, Shahidsales S. Female genital tract tuberculosis presenting as ovarian cancer. *J Res Med Sci* 2014;19:184-9.

## INTRODUCTION

The incidence of tuberculosis (TB) cannot be measured directly. In 2011, there were an estimated 8.7 million incident cases of TB globally. An estimated 20 million people are alive today as a direct result of TB care and control, according to the WHO Global Tuberculosis Report 2012.<sup>[1]</sup>

TB is still frequently observed in third-world countries like Africa and Asia.<sup>[2]</sup>

Tuberculosis of the upper genital tract is a rare disease in the developed world. However, it is a frequent cause of chronic pelvic inflammatory disease (PID) and infertility in other parts of the world. TB should be always considered in the differential diagnosis of a pelvic mass among immigrants from developing countries, especially those from Asia, the Middle East and Latin America, as well as the HIV positive patients.<sup>[3]</sup>

Tuberculosis involvement of the genitourinary (GU) or gastrointestinal (GI) tract, peritoneum, lymph nodes or viscera, constitutes up to 12% of extra pulmonary TB<sup>[4]</sup> and its nonspecific signs and symptoms may be similar to GI or ovarian cancers.

This paper illustrates 8 cases of ovarian or peritoneal tuberculosis, whose initial diagnoses were malignant processes of the GU tract. Our aim is to emphasize the importance of considering the disease based upon the epidemiologic clues of the patients, while interpreting the positive results for a suspicious ovarian malignancy.

## CASE SERIES

### Case A

A 20-year-old primiparous woman with abdominal and pelvic pain was referred to the department of gynecology at Ghaem University Hospital, Mashhad, Iran in July 2000.

She complained of anorexia, nausea, vomiting and urinary symptoms (dysuria and frequency) since few weeks before presentation. She had lost about four kilograms of weight since two months ago and she had a history of fever since the previous week. She had no personal or family history of TB. Upon examination, her vital signs were normal and she had no remarkable physical finding, except for a firm, fixed and tender mass in the right adnexa. Otherwise, the abdominal examination was normal and the patient had no ascites. An ultrasound study showed a 13 × 6 cm, multi-septated,

**Address for correspondence:** Dr. Malihe Hasanzadeh, Department of Gynecology oncology, Women Health Research center, Ghaem Hospital, Mashhad University of Medical Sciences, Mashhad, Iran. E-mail: hasanzademofradm@mums.ac.ir

**Received:** 07-06-2012; **Revised:** 25-09-2012; **Accepted:** 20-11-2012

mixed echogenic mass in the right adnexa and mild free fluid suggestive of a malignant process. Her biochemical profile and complete blood counts were in the normal range. There was no abnormality in chest X-ray, and her tuberculin skin test (TST) was negative.

Based on her clinical and imaging findings which suggestive of ovarian cancer, a diagnostic laparotomy was planned. The operation revealed dense adhesions between pelvic organs, and multiple biopsies were performed. Finally, histopathological investigation revealed necrotizing granulomatous changes consistent with TB with no malignant cells.

#### Case B

A 20-year-old primiparous woman was admitted to the department of gynecology at Ghaem University Hospital, in March 2003. She complained of painful abdominal distension and weight loss of approximately nine kilograms since the previous year. She had irregular menstruation and hypomenorrhea. Her past medical history was not remarkable, except for a pulmonary TB in her brother two years earlier, for which he completed the treatment course.

On admission, her vital signs were normal but the physical examination demonstrated a palpable pelvic mass (22 × 24 cm) with no tenderness. Ultrasound showed multiple myoma in the uterus and a large, multi-septated mass with internal echoes in the left ovary which suggested mucinous cystadenocarcinoma. Her biochemical profile, complete blood counts and chest X-ray were normal. She had a negative TST.

Upon laparotomy, one could not enter the abdominal cavity. There were disseminated nodules covering the peritoneum of the parietal wall. During surgery, we cannot find ovarian mass and biopsy specimens of peritoneal nodules were taken. Pathologist reported chronic granulomatous inflammation suggestive of tuberculosis. The patient was treated with standard, anti-tuberculosis treatment. One year later, she had no signs of the disease.

#### Case C

A 20-year-old virgin girl was referred to the department of gynecology at Ghaem University Hospital, in May 2005. She complained of abdominal pain and distention, as well as ten kilograms weight loss since 4 months ago. Before admission, she received multiple courses of antibiotic therapy, regarding her complaints of fever, sweat and cough.

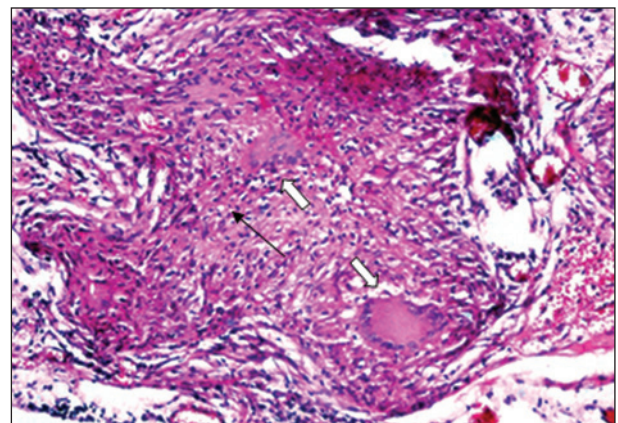
She had hypomenorrhea. Her past medical history and family history of TB were negative. Physical examination revealed ascites without any palpable masses. Ultrasound study revealed a 48 × 54 cm cystic mass with internal

echogenicity in the left adnexa and massive ascetic fluid. Laboratory tests showed leucopenia (WBC =  $3.2 \times 10^9 \text{ l}^{-1}$ ) and no anemia (Hgb =  $132 \text{ g l}^{-1}$ ). The CA-125 level was elevated to 44 units per ml (normal range: 0-35 units per ml). Cytopathological study of the ascetic fluid showed no malignant cells. The acid fast staining of the ascetic fluid was also negative. Her chest X-ray and tuberculin skin test were normal. Regarding the clinical findings, an exploratory laparotomy was performed which showed abundant amount of intense adhesions between omentum, transverse colon, abdominal wall and pelvic organs. Transverse colon was ruptured due to severe adhesions and therefore got repaired and some biopsies were taken. Histological examination confirmed necrotizing granulomatous inflammation consistent with tuberculosis [Figure 1]. Hence, the standard anti-tuberculosis treatment was prescribed. At follow-up 2 years after the last visit, she reported that all of her previous symptoms were resolved.

#### Case D

On Jan 2009, A 47-year-old menopausal woman (gravid 8, para 8) was admitted to the department of gynecology at Ghaem University Hospital, with the complaints of gross hematuria and weight loss. She suffered from diabetes since 15 years ago. Upon physical examination, there was a palpable, firm, fixed and non-tender mass in the left lower quadrant, and ascites was also noticeable, also. An ultrasound study showed a 22 × 26 cm cystic mass with internal echoes, as well as moderate ascites. Lab tests showed anemia (Hgb =  $55 \text{ g l}^{-1}$ ), Leukocytosis (WBC =  $15.4 \times 10^9 \text{ l}^{-1}$ ), serum creatinine level = 3.1, CA-125 = 15 units per ml. Her chest X-ray was normal and TST was negative.

Regarding the hemorrhagic diathesis of the patient, a cystourethroscopy was performed. Further, an exploratory laparotomy showed a 3 × 4 cm mass adhered to the bladder, and biopsy specimens were taken. Pathological analysis showed mucosal ulceration with considerable



**Figure 1:** Fibro connective tissue with granulomatous inflammation (note the epithelioid [thin arrow] and multinucleated Langhans-type giant cells [white arrows] — H and E stain ×400)

inflammatory response. Ten days later, she developed a productive cough not responding to conventional antibiotic therapy. She had dehiscence and purulent discharge from incision site that was culture positive for E-coli. Follow-up chest X-ray showed pleural effusion and consolidation in the right lung. Upon further evaluation, cystoscopy was successfully performed which revealed findings suggestive of bladder tuberculosis. The patient was discharged with anti-tuberculosis standard therapy. One year later, she had no symptoms, and her CXR and abdominal ultrasound were normal.

#### Case E

A 16-year-old virgin girl with the complaints of abdominal pain and weight loss was referred to the department of gynecology at Ghaem University Hospital, in July 2009. Her symptoms began six months ago and she lost over 10 kilograms of weight during this period. Her past medical history was not remarkable, except for the diagnosis of TB in her brother and sister, for which they had been treated one year ago. On admission, her vital signs were normal, but a 7 × 8 cm non-tender firm mass was found upon physical examination. Ultrasound showed a 39 × 116 cm cystic and multi-septated mass with irregular and thickened wall in the right adnexa suggesting an ovarian cancer. She had no abnormality on chest X-ray and TST was negative. CA-125 level was 509 units per ml. Based on the clinical findings and Lab test results, an exploratory laparotomy was performed. There were severe adhesions. The frozen section examination of biopsy materials was strongly suspicious for TB. Standard anti-tuberculosis drugs were started and the patient was discharged from hospital. Upon her visit one year later, the abdominal mass was disappeared. She had no complaints and her ultrasound study was normal.

#### Case F

A 15-year-old virgin girl from Afghanistan with the complaints of fever and continuous discharge from the incision site of a previous laparotomy was referred to the department of gynecology at Ghaem University Hospital, in Dec 2009.

The laparotomy had been performed four months before because of a pelvic mass, whose pathological study only revealed mild lymphocytic infiltration. She was diagnosed with diabetes one year ago, for which she was receiving insulin. Her mother had been treated for TB in the past years. She had fever (T = 38.8°C oral) and her physical examination demonstrated mild abdominal tenderness and small amount of discharge from the incision site, for which intravenous ceftriaxone was started. Ultrasound disclosed a 30 × 25 cm cystic lesion with thick septa in the left ovary. Laboratory studies showed

leukocytosis (WBC =  $15.7 \times 10^9 \text{ l}^{-1}$ , neut:85%) and anemia (Hct = 23.7, Hgb = 74  $\text{g l}^{-1}$ ). TST was negative and her chest X-ray was normal. The discharge culture isolated E-coli. Based on the clinical picture, her family history of TB and the initial pathological study which reported lymphocytic infiltration, an infectious diseases subspecialty consult was done and standard anti-tuberculosis drugs were started.

Two months later, the patient returned with the complaints of recurring abdominal pain. Ultrasound study revealed the ovarian cyst became larger and multi-loculated. A laparotomy was performed and a benign cyst with no signs in favor of malignancy was detected. Hence, anti-tuberculosis treatment was continued.

Two months later, she underwent resection and intestinal anastomose, because of intestine cutaneous fistula at the incision site. Again, the pathology report was negative for malignancy. The patient decided to stop her follow-up.

#### Case G

A 29-year-old nulligravid woman was admitted to the department of gynecology with abdominal distension and hypogastric pain in Sep 2009. She reported losing about 14 kilograms of weight since 2 months ago. Her obstetric history included primary infertility of 5 years duration, as well as amenorrhea during the last 18 months. Her family history was unremarkable. Laboratory tests revealed a normal CBC, an ESR of 54 mm per hour and a CA-125 level of 424 units per ml. Abdominal ultrasonography revealed a massive ascites and abundant adhesions between the right ovarian surface and the pelvic wall. The abdominopelvic computed tomography showed no mass or lymphadenopathies. Based on her clinical and laboratory findings, the patient underwent a laparoscopic examination which was unsuccessful because of her rigid abdominal wall, so a laparotomy was performed which showed abundant pelvic adhesions. Pathology report was consistent with TB and the patient was prescribed standard anti-tuberculosis drugs. Upon a visit one year later, she had no sign of the disease.

#### Case H

A 45-year-old multiparous Afghan woman was referred to the department of gynecology with the complaint of abdominal distention in Oct 2010. Her past medical history was unremarkable, except for a treated TB in her son one year ago. On admission, her vital signs were normal. Her TST was 15×15 mm. Laboratory tests showed anemia (Hgb = 89  $\text{g l}^{-1}$ ) with normal CBC. CA-125 level was 505 units per ml. Her Chest X-ray was normal. An abdominal ultrasound showed large and heterogeneous ovaries, as well as ascites and peritoneal



seeding suggestive of ovarian cancer. CT-scan revealed ascites, peritoneal seeding and plural effusion [Figure 2]. Polymerase chain reaction (PCR) test for mycobacterium tuberculosis DNA in peritoneal fluid was negative, and cytopathological study showed no malignant cells. An exploratory laparotomy was performed which showed peritoneal seeding and loose adhesions [Figure 3]. Pathology results demonstrated chronic granulomatous peritonitis consistent with tuberculosis and the patient treated accordingly [Figure 1].

## DISCUSSION

Tuberculosis is still a major worldwide concern. There is no pathognomonic clinical feature or imaging findings for definite diagnosis of extra pulmonary TB. Therefore, TB involvement of GI or GU tract can be easily confused with peritoneal carcinomatosis and advanced ovarian carcinoma.<sup>[5]</sup> Pelvic TB can be caused by reactivation of the organism (spread via blood stream, lymphatic system

or direct from the involved abdominal organs such as intestines) or rarely by venereal transmission. Patients have diverse symptoms including pelvic pain, infertility, fever, abnormal uterine bleeding, ascites and pelvic mass. CA-125 level, a tumor marker for ovarian cancer may also increase in TB. Although the presence of a pelvic mass associated with ascites, high CA-125 levels and peritoneal seeding strongly suggests pelvic malignancies, we should always consider the possibility of miliary tuberculosis, tuberculosis peritonitis or ovarian TB with peritoneal seeding, to prevent unnecessary surgery and starting appropriate and timely therapy.

Ovarian tuberculosis occurs in 15-25% cases and most often results from direct extension from fallopian tubes. In such cases, ovary may be surrounded by adhesions or may be the site of tubo-ovarian cyst formation or tubo-ovarian mass with adhesions surrounding them. In patients with hematogenous spread caseating granulomas may be seen in the parenchyma of ovary.<sup>[6]</sup>

Some factors which may be helpful for the diagnosis of TB include:

- Patient's race and geographic location (our patients were mostly from Afghanistan or its borderlines, or had a history of travelling to those areas).
- Personal or family history of TB, which is always suggestive<sup>[14]</sup>, four of our patients, had a history of TB in their first degree relatives.
- Patient's age. TB mostly occurs at reproductive ages (20-40) while ovarian cancer happens at older ages. The peak incidence of invasive epithelial ovarian cancer is at 56 to 60 years of age.<sup>[7]</sup> In our study, 5 patients (out of 8) were about 20 years old and all of patients were in reproductive ages.
- Weight loss is uncommon in advanced ovarian cancer. The most common clinical symptoms of pelvic

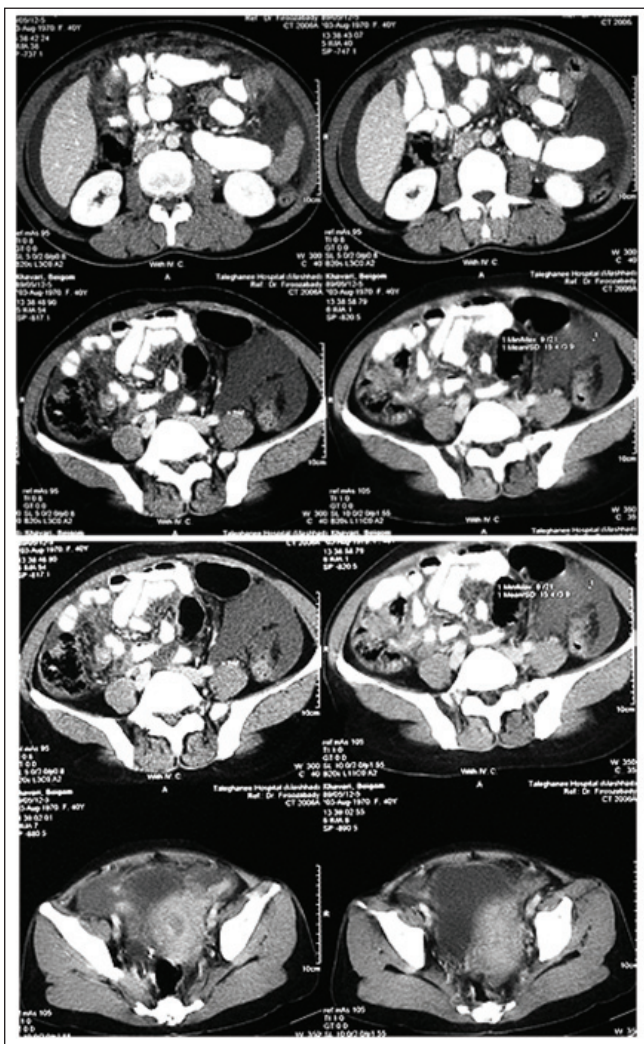


Figure 2: Large and heterogeneous ovaries, ascites and peritoneal seeding

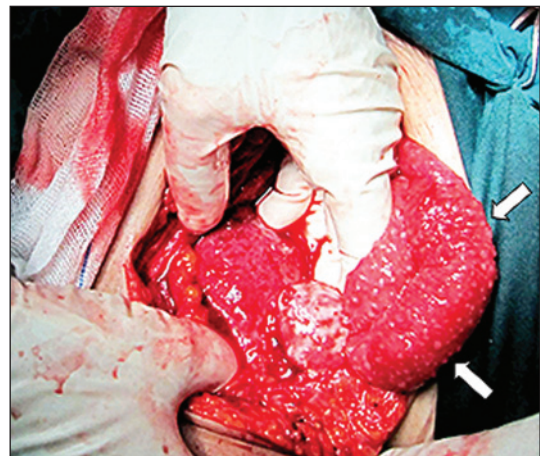


Figure 3: Miliary micro nodules (white arrows) all over the peritoneal cavity, the ovary and uterus and the other abdominal organs

tuberculosis include pelvic pain, general malaise, low-grade fever, weight loss, menstrual irregularity, and infertility. The failure of fever to subside with high doses of broad-spectrum antibiotics is a classic feature of pelvic tuberculosis. All of 8 cases had weight loss. Two cases had low fever and one cases had infertility. The clinical symptoms and signs of pelvic tuberculosis should direct the clinician to the diagnosis. However, the disease is so uncommon that it is seldom encountered in the gynecologist's usual practice; therefore, the clinical index of suspicion is generally low. In many cases, the clinical presentation is obscure and the diagnosis is delayed. The incidence of tuberculosis is rising in the world and gynecologists need to be aware that tuberculosis may be present in an atypical manner.<sup>[8]</sup>

- Non-invasive methods such as tuberculin skin test, chest radiographs or acid-fast staining and culture of the aspirated fluid from peritoneal cavity are usually insufficient to provide the diagnosis of peritoneal or pelvic TB.<sup>[5,9]</sup>

Performing a CXR before surgery may be helpful and should certainly be done. Nonetheless, none of our patients had an abnormal chest X-ray. Tuberculin skin test, CBC and sputum staining are usually not helpful, as in our patients.

In the presence of ascites or fluid in the pelvic cavity, staining and culture of the material might be helpful but usually give negative results, such as our presented cases. Some recently published studies argue that a positive PCR assay or high adenosine deaminase (ADA) level in aspirated fluid is diagnostic for TB.<sup>[5,10]</sup>

CA-125 which is a marker for malignant non mucinous ovarian cancer is nonspecific at premenopausal age, considering its increased levels in non-malignant disorders such as TB,<sup>[11,12]</sup> endometriosis, myoma, cirrhosis, hepatitis, and pancreatitis. However it has a high specificity (98%), sensitivity of 58% and a PPV of about 2% at postmenopausal ages.<sup>[3]</sup> CA-125 can be increased in peritoneal TB.

Hence, in a case of pelvic mass with high CA-125 level at reproductive ages, non-malignant disorders such as TB should always be considered.

Regarding the young age of our case, increased levels of CA-125 marker could not be diagnostic for a malignant process. A definite diagnosis of tuberculosis is established by pathology report of the specimens obtained by biopsy and frozen section, which is not always successful and may be associated with several complications.

Interestingly, all of our patients responded well to anti-tuberculosis therapy with favorable outcome, except for

case F whose symptoms relapsed and worsened after an initial response. It should be noted that some patients with tuberculosis experience a paradoxical reaction after receiving anti-tuberculous drugs. This phenomenon is much more common among HIV positive patients with tuberculosis for whom antiretroviral treatment is started. However, it is estimated that 2% of HIV-negative patients and 7% of HIV-infected patients not on antiretroviral, also experience the reaction. Patients have typically been responding to tuberculosis therapy but develop recurrent, new, or worsening manifestations such as fever, cough, lymph node enlargement, or roentgen graphic abnormalities. This phenomenon is a part of immune reconstitution inflammatory syndrome, and it is thought to be caused by robust peripheral blood T-cell responses to purified protein derivative, and increased pro-inflammatory cytokines. Although symptoms are usually self-limited and last a median of two months, morbidity can be substantial, and mortality can occur but is rare.<sup>[13]</sup> Unfortunately, our patient was not cooperative to tolerate the symptoms and decided to stop returning for further follow-up [Table 1].

## SUGGESTION

A meta-analysis should be performed on patients diagnosed with peritoneal and pelvic TB. According to the epidemiological clues of our cases, we emphasize the value of detailed history taking from the patients, with regard to their age, race and nationality, geographic location of living, social situation, and family history for widening the range of differential diagnoses to include those pathologic agents which have the ability of mimicking the signs and symptoms of the other pathologic processes.

## CONCLUSION

Tuberculosis (TB) should be always being considered in the differential diagnosis of advanced ovarian cancer, especially in the regions that are endemic for the disease.

## ACKNOWLEDGEMENTS

The authors wish to thank Mrs. Akram Moshtagh for her invaluable help in data collection.

## ABBREVIATIONS

WBC: White blood cell count; Hgb: Hemoglobin; CA-125: Cancer antigen-125

Neut: Neutrophils; Hct: Hematocrit; CBC: Complete blood count

ESR: Erythrocyte sedimentation rate

**Table 1: Demographic, clinical and paraclinical aspects of the patients**

Title/Case	Case A	Case B	Case C	Case D	Case E	Case F	Case G	Case H
Age	20	22	20	47	16	15	29	45
Parity	PP	PP	Virgin	Gravid 8	Virgin	Virgin	Nulligravid	Multiparous
Race	Afghan	Iranian (From a city in Border of Afghanistan)	Afghan	Iranian (From a city in Border of Afghanistan)	Iranian	Afghan		Afghan
Symptoms	Pelvic pain+Urinary symptoms	Abdominal pain+distension	Abdominal pain+distension	Gross Hematuria+Weight loss	Abdominal Pain+Weight loss	Fever+Discharge	Abdominal pain+distension	Abdominal pain+distension
Weight loss	+	+	+	+	+	+	+	-
Fever	-	-	+	-	-	+	-	-
Past Medical History	-	Irregular menses	Hypomenorrhea	Diabetes	-	Diabetes	Infertility	-
Familial History	-	+(brother)	-	-	+(brother)	+(mother)	Amenorrhea	+(son)
Ascites	-	+	Massive	+	-	+	Massive	+
Chest X-Ray	Normal	Normal	Normal	Normal	Normal	Normal	Normal	Normal
C.B.C	Normal	Normal	Leukopenia	Anemia	WBC+anemia	WBC+anemia	Normal	Anemia
CA125 (u/ml)	-	200	44	15	509	99	424	505
Ultrasound	130x60mm multiseptated adnexal mass+mild free fluid	220x240 mm Multiseptated mass+internal echo	48x54mm cystic mass+massive ascites	220x260mm cystic mass+ascites	39x116 mm cystic+multiseptated mass	30x35mm cystic mass+thick septa	Massive ascites and right ovary adhesions	Large, heterogeneous ovaries, ascites and peritoneal seeding
Primary Diagnosis	Ovarian cancer	Mucinocyst adeno carcinoma	Ovarian cancer	Ovarian cancer	Ovarian cancer	Ovarian cancer	Ovarian cancer	Tuberculosis

**REFERENCES**

- World Health Organization (2012). Global tuberculosis report 2012, chapter 2: The burden of disease cause by TB. P: 8, ISBN 9789241564502. Available from: [http://www.who.int/entity/tb/publications/global\\_report/2012/pdf/chapter2.pdf](http://www.who.int/entity/tb/publications/global_report/2012/pdf/chapter2.pdf) Retrieved 2012.[ Last accessed on 2012 Nov 5].
- Sachan R, Patel ML, Gupta P, Verna AK. Genital tuberculosis with variable presentation: A series of three cases. . BMJ Case Report 2012 BMJ Case Reports2012; doi:10.1136/bcr-2012-006665
- Rock J, Jones HW. TeLindes operative gynecology. 10<sup>th</sup> ed, Vol. 30. Philadelphia: Lippincott Williams and Wilkins; 2008. p. 677-8.
- Uzunkoy a, HarmaM, Harma M. Diagnosis of abdominal tuberculosis: Experience from 11 cases and review of the literature. World J Gastroenterol 2004;10:3647-9.
- Adali E, Dulger C, Kolusari A, Kurdoglu M, Yildizhan R. Pelvic-peritoneal tuberculosis simulating peritoneal carcinomatosis: High clinical suspicion and a minimally invasive procedure. Arch Gynecol Obstet 2009;280:867-8.
- Kumar S. Female Genital Tuberculosis. In: Tuberculosis. 2<sup>nd</sup> ed. India: Jaypee Brothers Medical Publishers; 2009. p. 452-3.
- Berek JS. Berek and Novak's Gynecology. 14<sup>th</sup> ed, Vol. 35. Philadelphia: Lippincott Williams and Wilkins; 2007. p. 1457-9.
- Pina C, Teixeira M, Cruz D, Ferreira E, Mesquita M, Torgal A. CASOS CLÍNICOS/SÉRIE DE CASOS, Pelvic Tuberculosis, The Great Simulator of Gynaecologic Malignancies. Arquivos De Medicina2008 22:45-8.
- Tinelli A, Malvasi A, Vergara D, Martignago R, Nicolardi G, Tinelli R, *et al.* Abdominopelvic tuberculosis in gynaecology: Laparoscopic and new laboratory findings. Aust N Z J Obstet Gynaecol 2008;48:90-5.
- Tewari M, Sahoo SP, Shukla HS. Abdominal Tuberculosis. In: Tuberculosis. 2<sup>nd</sup> ed. India: Jaypee Brothers Medical Publishers; 2009. p. 288.
- Simsek H, Savas MC, Kadayifci A, Tatar G .Elevated serum CA 125 concentration in patients with tuberculosis peritonitis: A case-control study. Am J Gastroenterol 1997;92:1174-6.
- Thakur V, Mukherjee U, Kumar K. Elevated serum cancer antigen 125 levels in advanced abdominal tuberculosis. Med Oncol 2001;18:289-91.
- Fitzgerald DW, Sterling TR, Haas DW. Mycobacterium tuberculosis. In: Mandell, Douglas, and Bennett's Principles and Practice of Infectious Diseases. 7<sup>th</sup> ed. Philadelphia: Churchill Livingstone; 2009. p. 250.
- Yassae F, Farzaneh F. Familial Tuberculosis Mimicking Advanced Ovarian Cancer. Infect Dis Obstet Gynecol 2009;2009:736018.

Source of Support: Nil, Conflict of Interest: None declared.