

Unusual case of adult hemophagocytic syndrome

Babak Tamizifar, Golnaz Samadi¹, Maryam Rismankarzadeh²

Department of Internal Medicine, School of Medicine, ¹Resident of Internal Medicine, Department of Internal Medicine, Alzahra Hospital, ²General Physician, Isfahan University of Medical Sciences, Isfahan, Iran

Hemophagocytic syndrome (HPS) is an uncommon manifestation in systemic lupus erythematosus (SLE). Clinical features of HPS include fever, pancytopenia, abnormal liver enzyme, hepatosplenomegaly, lymphadenopathy, and coagulation disorder. HPS comprises primary and reactive forms. Herein, we describe a case of untreated SLE with HPS as one of the first manifestations of systemic Lupus.

Key words: Autoimmunity, hemophagocytic syndrome, hemophagocytosis, systemic lupus erythematosus

How to cite this article: Tamizifar B, Samadi G, Rismankarzadeh M. Unusual case of adult hemophagocytic syndrome. *J Res Med Sci* 2014;19:178-80.

INTRODUCTION

Hemophagocytic syndrome (HPS) is a rare disorder that is characterized by the activation of non-neoplastic macrophages or histiocytes leading to prominent hemophagocytosis in bone marrow and other reticuloendothelial systems.^[1,2]

Clinical presentations of HPS include fever, cytopenia, abnormal liver enzyme elevation, hepatosplenomegaly, lymphadenopathy, and coagulation disorder.

HPS includes primary (hereditary) and reactive forms. Primary HPS is detected mostly in infants. Reactive HPS occurs in situations such as infections, malignant lymphomas, autoimmune diseases, and administration of certain drugs.^[1] In general, HPS is an unusual but serious complication of systemic disease. Systemic lupus erythematosus (SLE) is the most common underlying disease for HPS in adult.^[2]

We report a case of a previously healthy 25-year-old woman that developed hemophagocytosis with fulfilled diagnostic criteria for SLE. There are only few cases reported in the literature.

The patient presented with pancytopenia related to increasing hemophagocytic activity of histiocytes in the bone marrow.

However, elevated anti-dsDNA antibody titer and reduced C3 level continued for a month after high dosage of steroid therapy.

CASE PRESENTATION

A 25-year-old woman admitted to our hospital (2012, Isfahan, Iran) complaining of prolonged fever without specific pattern that he had had for three weeks and did not respond to multiple courses of antimicrobial treatment after initial sepsis work up in another hospital (according to her medical discharge sheet). She also had a history of generalized maculopapular rash prominent on distal part of both her hands without pruritis or arthralgia. She did not report weight loss, sweating, productive coughs, and dysuria. She did not smoke cigarettes and did not use alcohol or illicit drugs, traveling to foreign countries or animal contact. She had a history of Raynaud's phenomenon during cold weather and history of well-controlled hypothyroidism. She was admitted in another hospital about six weeks ago due to evaluation for multiple cervical and axillary lymphadenopathies. All investigation results in her previous admission, including tuberculin test, sputum smear for tuberculosis, frequent blood and urine cultures were negative. The result of her cervical lymph node resection was not available.

On admission to our hospital her oral temperature was 39°C, blood pressure 105/70 mmHg, heart rate 110 beats per minute and respiratory rate 26 breaths per minute. She appeared severely ill. The results of auscultation of the heart and lungs were normal. An abdominal examination revealed a liver span of 11 cm in the right mid-clavicular line; the spleen was not palpable. Other physical examination did not show any abnormalities except posterior cervical and axillary lymphadenopathy. She also had arthritis on her metacarpal and knee joints

Address for correspondence: Dr. Babak Tamizifar, Department of Internal Medicine, School of Medicine, Isfahan University of Medical Sciences, Isfahan, Iran. E-mail: tamizib@med.mui.ac.ir

Received: 28-03-2013; **Revised:** 14-05-2013; **Accepted:** 26-05-2013

of her both extremities. Her initial laboratory findings revealed severe pancytopenia: hemoglobin 8 g/dl (normal range between 12 and 16 g/dl), leukocyte count 3000 per cubic millimeter (52% neutrophils, 31% lymphocytes) (normal range: 30%-55%), and platelet count 10,000 per cubic millimeter (normal range: 150,000-400,000). Ferritin level was 10,180 U/ml (normal range below 200). Erythrocyte sedimentation rate (ESR) 65 mm/h (normal range below 30 mm/h) and C-reactive protein (CRP) 100 mg/dl (normal range below 8).

Serum complement C3 and C4 levels were both decreased to 320 and 10mg/l (normal ranges 900-1800 and 100-400, respectively). Kidney function tests were normal. Coagulation tests on admission disclosed: Prothrombin time (PT) 15.5 s (normal <13 s) and activated PTT (aPTT) 35.2 s (normal below 28 s).

AST 84 U/l, (normal 0-40 U/l); LDH 1549 U/l (normal 114-240 U/l); ALT 67 U/l, (normal 0-40 U/l). Direct Coombs test was positive. Viral markers for hepatitis B, hepatitis C, cytomegalovirus, Epstein-barr virus antibodies, and human immunodeficiency virus were all negative. Other laboratory findings, including urinalysis, urine, and blood cultures, had negative results. Her chest radiography (CXR) revealed mild pleural effusion in her both lungs. Peripheral blood smear showed hypochromic red blood cells with mild anisocytosis and minimal reduction in white blood cells and platelets counts. Her abdominopelvic sonography showed mild ascites, mild bilateral pleural effusion, and mild hepatosplenomegally. On the secondary day of her admission, she had two episodes of tonic-clonic seizures. But lumbar puncture result and brain computed tomography scanning (CT scan) and magnetic resonance imaging (MRI) all were normal.

Finally after 6 weeks, report of right axillary lymph node resection showed HPS. Repeated rheumatologic tests showed ANA 1:160 (normal range <1:80), Anti-ds DNA antibody 125 IU/ml (normal range <12). Both anticardiolipin and β -2 glycoprotein-1 antibodies titers were normal. Patients showed a severe hemophagocytosis in her bone marrow biopsy, while normal in bone marrow aspirate [Figure 1].

After establishing the diagnosis of SLE, a twice daily dose of 50 mg of prednisolone was orally administered promptly that was added with 400 mg hydroxychloroquine. Within 24 h after starting the prednisolone and hydroxychloroquine, the fever had subsided completely. Her fever markedly improved and all of the laboratory findings returned to normal values within the next two weeks.

The patient was discharged 15 days after completion of the initial therapy in a clinically improved state by using

a maintenance dose of 30 mg of prednisolone, 200 mg hydroxychloroquine, and valproate sodium 500 mg per day. She was contacted four months after hospitalization and reported no difficulties.

DISCUSSION

Risdall *et al.* first explained a distinct clinical syndrome involving depression of the blood cell counts, hemophagocytosis, and histiocytosis that all were defined as HPS.^[3]

Besides Wong *et al.* reported six cases of HPS among 250 SLE patients.^[4] Lupus-associated HPS is a secondary HPS which can be classified into two types: Lupus-specific HPS in untreated lupus flare, which has no signs of infection involving acute severe pancytopenia; and infection-related HPS, which occurs in immunosuppressed SLE patients and has a close associated with viral infection.^[1-3]

In a case series retrospective analysis of coexistence of HPS and SLE patients, Qian *et al.* reports that about 60% of HPS patients presented during or before lupus flare up and mortality rate was about 21%.^[1] The prognosis was better in patients with lupus specific HPS than those with infection-related HPS.^[2,5] As they mentioned "As no evidence of infection had been found in these patients, it strongly indicated HPS could be triggered by lupus activity itself," so in our patient the most probable diagnosis was lupus specific HPS. Cytological studies including bone marrow aspiration and biopsy demonstrating hemophagocytosis are the diagnostic basis for HPS diagnosis.

There have been several reports concerning the risk factors for poor prognosis in patients with HPS including of infection and high CRP level, absence of lymphadenopathy, thrombocytopenia (<50,000 d/l), and corticosteroid therapy

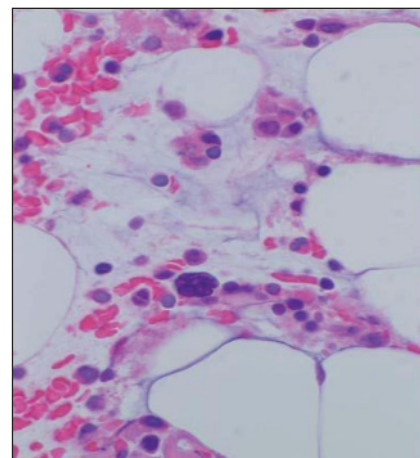


Figure 1: Bone marrow aspiration showed hemophagocytic syndrome

at the time of HPS diagnosis.^[3,6] But none of these proposed prognostic factors were related to increase mortality in our patient.

Physicians should recognize the clinical entity; accurate diagnosis, intensive therapy, and sufficient supported cares are critical in improving patient's prognosis.

REFERENCES

1. Qian J, Yang CD. Hemophagocytic syndrome as one of main manifestations in untreated systemic lupus erythematosus: Two case reports and literature review. *Clin Rheumatol* 2007;26:807-10.
2. Fukaya S, Yasuda S, Hashimoto T, Oku K, Kataoka H, Horita T, *et al.* Clinical features of haemophagocytic syndrome in patients with systemic autoimmune diseases: Analysis of 30 cases. *Rheumatology* 2008;47:1686-91.
3. Risdall RJ, McKenna RW, Nesbit ME, Krivit W, Balfour HH Jr, Simmons RL, *et al.* Virus associated hemophagocytic syndrome. A benign histiocytic proliferation distinct from malignant histiocytosis. *Cancer* 1979;44:993-1002.
4. Wong KF, Hui PK, Chang JK, Chan TW, Ha SY. The acute lupus hemophagocytic syndrome. *Ann Intern Med* 1991;114:387-90.
5. Emmenegger U, Schaerb DJ, Larroche C., Nefteld KA. Hemophagocytic syndromes in adults: Current concepts and challenges ahead. *Swiss Med Wkly* 2005;135:299-314.
6. Kaito K, Kobayashi M, Katayama T, Otsubo H, Ogasawara Y, Sekita T, *et al.* Prognostic factors of hemophagocytic syndrome in adults: Analysis of 34 cases. *Eur J Haematol* 1997;59:247-53.

Source of Support: Nil, Conflict of Interest: None declared.