

Ultrasound surface probe as a screening method for evaluating the patients with blunt abdominal trauma

Mohammad Nasr-Esfahani, Mohsen Kollahdouzan, Mehrnoosh Shafiei¹

Departments of Emergency Medicine, ¹Surgery, Isfahan University of Medical Sciences, Isfahan, Iran

Background: Blunt abdominal trauma is one of the causes of mortality in emergency department. Free fluid in the abdomen due to intra-abdominal blunt trauma can be determined by the surface probe of ultrasound. Since the importance of this free fluid in hemodynamic stable patients with blunt trauma is associated with the unknown outcome for surgeons, this study was performed to evaluate the role of ultrasound surface probe as a screening method in evaluating the patients with blunt abdominal trauma. **Materials and Methods:** A descriptive-analytical study was done on 45 patients with blunt abdominal trauma and hemodynamic stability. The patients were evaluated twice during the three-hours, including repeated ultrasound surface probe and clinical examinations. Computerized tomography was also performed. The patients were divided based on the amount of the free fluid in the abdomen during the evaluations into two groups: Fixed or increased, and decreased free fluid. The results of the different evaluated methods were compared using the sensitivity and specificity. **Results:** From 17 patients with CT abnormalities, free fluid increased in 14 patients (82.4%). Free fluid was decreased in three patients who were discharged well from the surgery service without any complication. Surface probe in prognosis detection had a sensitivity of 82.4% and specificity of 92.9%. The percentage of false positive and negative ultrasound compared with CT scan was 7.1% and 17.6%. Also, positive and negative predictive value of the ultrasound with surface probe was 87.5% and 89.7% respectively. **Conclusion:** The use of the ultrasound with surface probe in the diagnosis of free fluid in blunt abdominal trauma in hemodynamic stable patients can be considered as a useful screening method.

Key words: Blunt abdominal trauma, CT scan, ultrasound surface probe

How to cite this article: Nasr-Esfahani M, Kollahdouzan M, Shafiei M. Ultrasound surface probe as a screening method for evaluating the patients with blunt abdominal trauma. *J Res Med Sci* 2014;19:23-7.

INTRODUCTION

Blunt abdominal trauma, is a common clinical issue of these days in the world because of the rapid increase in the amount of motor vehicle accidents.^[1-2] Immediate evaluation of the patients' abdomen affected with blunt abdominal trauma is a critical and controversial issue in the emergency for the physicians. Blunt abdominal trauma forms a high percent of trauma cases and considering the place of important organs of the body inside the abdomen, if the organs were injured and ruptured without timely diagnosis, this condition can lead to irreversible conditions and even death.^[3,4]

Diagnosis of blunt trauma based on physical examination may be unreliable because of the patients' consciousness status changes, drug effects, and other associated damages.^[5] Other procedures such as DPL (Diagnostic Peritoneal Lavage), computerized tomography scan (CT) and FAST (Focused Assessment with Ultrasound for Trauma) can be used in the patients with blunt trauma.^[6-11]

DPL offers information about the presence or absence of peritoneal fluid in the abdomen, but it is an invasive procedure with the possible complications such as vascular injury, bowel perforation, bladder perforation or wound complications with an incidence of about 1-9%.^[5] Besides, if done, this approach leads to a reduction of accuracy in the subsequent processes such as ultrasound or CT scan because of the presence of air or fluid in the abdominal cavity.^[5,12]

Abdominal CT scan is the gold standard in abdominal evaluation, but there are some barriers in the use of CT scan, which is not seen on ultrasound, and they include the risk factors of artifact during the patient movement, renal poisoning, X-ray exposure, and need to move the patients.^[13-15] As a result, ultrasound is introduced as a useful tool in the evaluation of abdominal trauma since 1990, and even some studies regarding the specificity of ultrasound from 70% to about 100% which is better than physical examination and DPL.^[16] (1) Rose *et al.*, in a prospective study of 280 patients reported that 52% of the control group (not examined by ultrasound

Address for correspondence: Dr. Mehrnoosh Shafiei, Department of Emergency Medicine, Isfahan University of Medical Sciences, Isfahan, Iran.
E-mail: m_shafiei2087@yahoo.com

Received: 29-05-2013; **Revised:** 11-07-2013; **Accepted:** 07-08-2013

in the Emergency Department), eventually needed a CT scan compared with 36% of the cases who used ultrasound examination, concluding that routine use of ultrasound in the evaluation of the patients with blunt abdominal trauma reduces the need for CT scans.^[17-19]

FAST is a screening technique for the detection of free intra-peritoneal fluid of the patients with blunt abdominal trauma, which in many cases is used as a substitute for peritoneal lavage.^[20] The most common protocol is the evaluation of para hepatic sites, para splenic, para colic gutters, pelvis and also pericardial bleeding check.^[9] To check the fluid collection, curvilinear array probe with frequency of 3.5-5 MHZ is suitable for that the increasing frequency (surface probe) allow to more surface area visible.^[21] In FAST protocol of emergency medicine, it does not mention to use the surface probe (linear array probe 6-10 MHZ). However, this study seems necessary and critical regarding the high prevalence and high importance of blunt abdominal trauma in order to avoid losing time in the detection of intra-abdominal trauma and avoiding repeated para-clinical evaluations and the necessity of quick decision making in the process of timely surgery and discharging. Although in this regard, clinical examination is considered the most important technique in the evaluation of trauma patients, in many cases it is not enough as the only action.^[22]

Ultrasound, as a screening tool is inexpensive, accurate, simple and accessible, being used in the emergency department.^[23] Free fluid in the abdomen, due to intra-abdominal blunt trauma can be determined by surface probe of ultrasound. Since the importance of this free fluid in hemodynamic stable patients with blunt trauma is associated with the unknown outcome for surgeons, this study was performed to evaluate the role of ultrasound surface probe as a screening method in evaluating the patients with blunt abdominal trauma.

MATERIALS AND METHODS

This descriptive-analytical study was performed on the patients with blunt abdominal trauma admitted to University Referral Hospital, Al-Zahra (A. S.), and emergency section from Feb 2011 to Feb 2012. The study population consisted of all patients with blunt abdominal trauma.

The patients with hemodynamic stability; and negative FAST and positive interloop fluid results were included. The patients with history of pregnancy, free fluid in the abdomen such as ascites; intra-abdominal infections; prior DPL, peritoneal dialysis, and penetrating abdominal trauma were not also included. Co incidence trauma of the pelvis

or hip fracture, and those died before the completion of the research process as well as the patients with GCS <15 were excluded from the study because of unreliable abdominal examination.

After admission of the patients to the emergency department, initial emergency managements and clinical evaluation (history and clinical examination) were performed. FAST was done by an emergency medicine physician on admission. If the initial FAST was negative, the patients underwent ultrasound in radiology department. If interloop fluid was reported, the initial FAST was considered as false results and the patient entered into the study. The patients were monitored for three hours in the emergency department, being checked for vital signs, abdominal examination and repeated blood tests including the hemoglobin and hematocrit levels on admission and after 3 hours. Based on radiologist report on free fluid in the abdomen during three evaluations, they were categorized into two groups including the decreased and fixed or increased fluid. Both groups were provided with surgical consultation and their remedy process was followed by the project executor. This included the investigation of the patients' need for surgery, surgical mortality record, CT scan and its findings, checking Hb drop of more than 2 units during the evaluation.

All other information including the age and gender were recorded in the specific check list designed for this purpose. The obtained data finally were analyzed using the SPSS software, version 20. Chi-square and t-tests was performed for statistical analysis.

RESULTS

In this study, 45 patients with blunt abdominal trauma were studied. Mean (SD) age was 29.3 ± 15.2 years, with the range of 14-70 years. Most of the patients were male (82.2%).

The patients examined for abdominal tenderness twice; the result of the first and second examinations was negative in 27 patients (60%) and 31 patients (69.9%) respectively ($P=0.34$).

Abdominal ultrasound results showed that in 16 patients (35.6%), the free fluid had increased during 3 hours evaluation, and in 29 patients (64.4%) it was decreased.

The frequency percentage of the people with general agreement between the first examination and ultrasound is 77.8% which includes 12 cases with the existence of fluid and 23 cases with the lack of fluid. Kappa agreement test was performed on the mentioned data and it also showed that the general agreement between the first examination and ultrasound was 0.53, which is statistically significant

($P < 0.001$). Results regarding the agreement between examinations and ultrasound have been shown in Table 1.

The mean (SD) systolic blood pressure of the patients was 112.9 ± 14.3 mm Hg in the first examination and 108.8 ± 19.1 mm Hg in the second examination ($P = 0.17$). Mean (SD) pulse rate in the first and second examination was, 94.2 ± 19.1 and 94 ± 15.3 times per minute respectively ($P = 0.86$).

In the CT scan investigation, most of the patients had splenic rupture (50%) [Figure 1].

Comparison of CT scan and ultrasound of the patients showed that from 17 patients with CT abnormalities, in 14 patients (82.4%) the free fluid level had increased, and in 3 patients, the free fluid was decreased. Those with decreased free fluid were discharged well from the surgery service. In two patients with normal CT, the liquid levels were increased one patient had a rupture of the intestines which were diagnosed during surgery. The second patient was under serial evaluation of surgeon and discharged well from surgery service.

Based on these results, ultrasound with surface probe showed sensitivity level of 82.4% and specificity of 92.9%. Positive and negative predictive value of ultrasound with surface probe was also 87.5% and 89.7% respectively with $LR^+ = 11.53$ (95% CI = 2.98-44.6) and $LR^- = 0.19$ (95% CI = 0.07-0.53). The results are shown in Table 2.

The study of hemoglobin level in the patients with increased free fluid showed that in 6 patients (37.5%) decreased hemoglobin level was observed and in 10 patients (62.5) the level was not changed. ($P = 0.001$).

The findings of the CT scan, ultrasound and hemoglobin level is shown in terms of surgery in Table 3. According to this table, hemoglobin level decrease, ultrasound findings, and results of the CT scan findings, were significantly different in terms of the findings of the surgery.

A significant difference in the serial examination based on the CT scan was observed. Based on Kappa test, an agreement degree of 0.63 was obtained between the examination and CT scan ($P < 0.001$). Despite the negative serial examination in 4 patients (23.5%), the CT scan result was positive in these patients.

DISCUSSION

The purpose of this study was to determine the role of ultrasound surface probe as a screening method in evaluating the patients with blunt abdominal trauma.

Table 1: Frequency distribution of the clinical results of the patients in two times examinations and abdominal ultrasound report

Ultrasound clinical examination (Abdominal tenderness)		Positive Number (percent)	Negative Number (percent)	Kappa	P
First	Positive	12 (75)	6 (20.)	0.53	<0.001
	Negative	4 (25)	23 (79.3)		
Second	Positive	13 (81.2)	1 (3.4)	0.8	<0.001
	Negative	3 (18.8)	28 (96.6)		

Positive ultrasound means increased or fixed and negative ultrasound means decreased abdominal free fluid based on serial evaluations

Table 2: Frequency distribution of computerized tomography (CT) scan and abdominal ultrasound in determining the free fluid

Ct Scan	Abnormal number	Normal number	Total number
Positive	14 (82.4)	2 (7.1)	16 (35.6)
Negative	3 (17.6)	26 (92.9)	29 (64.6)
Total	17 (100)	28 (100)	45 (100)

Positive ultrasound means increased or fixed and negative ultrasound means decreased abdominal free fluid based on serial evaluations

Table 3: Distribution of hemoglobin level, abdominal ultrasound and computerized tomography (CT) results in terms of performing the surgery in evaluated patients

Variables	Surgery Level	Yes	No	P
Hemoglobin level	Decreased (two units)	4 (57.1%)	2 (5.3%)	0.003
	Normal	3 (42.9%)	36 (94.7%)	
Free fluid existence in ultrasound result	Fixed or increased	7 (100%)	9 (23.7%)	<0.001
	Decreased	0 (0)	29 (76.3%)	
CT scan	Abnormal	6 (85.7%)	11 (28.9%)	0.008
	Normal	1 (14.3)	27 (71.1)	

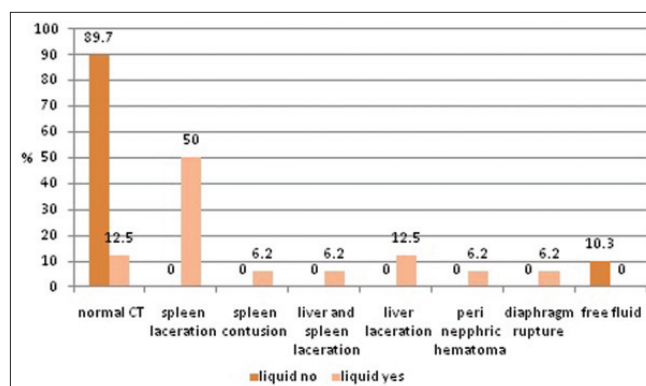


Figure 1: The Frequency percentage of reported free liquid changes in ultrasound based on their results of the abdominal CT Scan
Liquid no: Liquid decreased in abdominal ultrasonography
Liquid yes: Liquid fixed or increased

Nowadays trauma is a major cause of the patients referred to emergency sections all around the world, especially in the developing countries. Determining injury level in order to take timely medical treatment is of high importance. In order to determine the type and extent of damage, the use of CT scans are very helpful, but due to lack of CT scans in all medical care centers ultrasound is one of the tools that are more available and is also easier to work comparing CT scan.

In this study, most of the patients were male and young. The result of the first examination was positive in 40% of the patients and negative in 60%. Also, in the second examination 31.1% was positive and 68.9% negative, but there was no significant difference between the first and second examination results. Also, the results of abdominal ultrasound showed that 35.6% of the patients had fixed or increased abdominal free fluid, while in 64.4% it was decreased. According to this study, despite the negative serial examination in 4 patients (23.5%), CT scan results were abnormal. Therefore, regarding the findings from the physical examination it cannot be judged correctly about the intra-abdominal trauma and lack of it. However, examination is usually the first step to determine the severity of injury to the patient.

In the CT scan investigation, most of the patients had splenic rupture similar to other study (11).

Comparison of CT scan and ultrasound of the patients showed that from 17 patients with CT abnormalities, in 14 patients (82.4%) the free fluid level had been fixed increased, and in 3 patients it was decreased who had previously free fluid in CT and then were discharged from the surgery section fully recovered. This is while 2 patients with normal CT free fluid levels had increased. One patient was a case with rupture of the intestines surgically diagnosed, and the second one was discharged from surgery service fully recovered.

Based on these results, ultrasound with surface probe had a high sensitivity and specificity. Also based on the results, positive and negative predictive value of ultrasound with surface probe was 87.5% and 89.7%.

Moreover, 37.5% of the patients with increased fluid levels had decreased levels of hemoglobin which may be determinant factor for prognosis. In the patients with increased free fluid in ultrasound by surface probe 82.4% had also abnormal findings in CT scan, whereas in the patients with positive results of serial clinical examination, 76.5% had abnormal CT findings. Therefore, we may confirm that free fluid observation in ultrasound is worthwhile. In this connection the results of a study by Bakker *et al*, used ultrasound as an initial method

of screening in 1,149 patients' ultrasound had a high negative predictive value.^[24] Also, Lee, *et al*, performed for 6 years on 4,029 patients showed that ultrasound has 85% sensitivity, 96% specificity, and 95% precision. And they concluded that in positive FAST cases and the patients with low blood pressure in blunt abdominal trauma, there is a need for therapeutic laparotomy without the need for CT scan use.^[25]

So, the general conclusion of this study could be that using ultrasound with surface probe in the investigation of free fluid in blunt abdominal trauma patients has an acceptable value in the patients screening.

ACKNOWLEDGE

Isfahan University of Medical Sciences, Research Project Number: 390337.

REFERENCES

1. Poletti PA, Mirvis SE, Shanmuganathan K, Takada T, Killeen KL, Perlmutter D, *et al*. Blunt abdominal trauma patients: Can organ injury be excluded without performing computed tomography? *J Trauma* 2004;57:1072-81.
2. Lansink KW, Cornejo CJ, Boeijs T, Kok MF, Jurkovich GJ, Ponsen KJ. Evaluation of the necessity of clinical observation of high-energy trauma patients without significant injury after standardized emergency room stabilization. *J Trauma* 2004;57:1256-9.
3. Nishijima DK, Simel DL, Wisner DH, Holmes JF. Does this adult patient have a blunt intra-abdominal injury? *JAMA* 2012;307:1517-27.
4. Isenhour JL, Marx J. Advances in abdominal trauma. *Emerg Med Clin North Am* 2007;25:713-33, ix.
5. Kornezos I, Chatziioannou A, Kokkonouzis I, Nebotakis P, Moschouris H, Yiarmenitis S, *et al*. Findings and limitations of focused ultrasound as a possible screening test in stable adult patients with blunt abdominal trauma. *Eur Radiol* 2010;20:234-8.
6. Hoff WS, Holevar M, Nagy KK, Patterson L, Young JS, Arrillaga A, *et al*. Practice management guidelines for the evaluation of blunt abdominal trauma: The East practice management guidelines work group. *J Trauma* 2002;53:602-15.
7. Stephan PJ, McCarley MC, O'Keefe GE, Minei JP. 23-Hour observation solely for identification of missed injuries after trauma: Is it justified? *J Trauma* 2002;53:895-900.
8. Fakhry SM, Watts DD, Luchette FA. Current diagnostic approaches lack sensitivity in the diagnosis of perforated blunt small bowel injury: Analysis from 275,557 trauma admissions from the EAST multi-institutional HVI trial. *J Trauma* 2003;54:295-306.
9. Dittrich K, Abu-Zidan FM. Role of Ultrasound in Mass-Casualty Situations. *Int J Dis Med* 2004;2:18-23.
10. Shanmuganathan K. Multi-detector row CT imaging of blunt abdominal trauma. *Semin Ultrasound CT MR* 2004;25:180-204.
11. Lynn KN, Werder GM, Callaghan RM, Sullivan AN, Jafri ZH, Bloom DA. Pediatric blunt splenic trauma: A comprehensive review. *Pediatr Radiol* 2009;39:904-16.
12. Rozycki GS, Shackford SR. Ultrasound, what every trauma surgeon should know. *J Trauma* 1996;40:1-4.
13. Mayo JR, Aldrich J, Muller NL. Radiation exposure at chest CT: A statement of the Fleischner Society. *Radiology* 2003;228:15-21.

14. Frush DP. Review of radiation issues for computed tomography. *Semin Ultrasound CT MR* 2004;25:17-24.
15. Salimi J, Mutamedi M. Detection of intra-abdominal injury in trauma patients: Our experience with diagnostic peritoneal lavage. *Acta Med Iran* 2004;42:122-4.
16. Hsu JM, Joseph AP, Tarlinton LJ, Macken L, Blome S. The accuracy of focused assessment with sonography in trauma (FAST) in trauma patients: Experience of an Australian major trauma service. *Injury* 2007;38:71-5.
17. Ross JS, Levitt MA, Porter J. Does the presence of ultrasound really affect computed tomographic scan use? A prospective randomized trial of ultrasound in trauma. *J Trauma* 2001;51:545-50.
18. Dolich MO, Varela JE, Compton RP, Kenney KL, Cohn SM. Ultrasounds for blunt abdominal trauma. *J Trauma* 2001;50:108-12.
19. Zheng YX, Chen L, Tao SF, Song P, Xu SM. Diagnosis and management of colonic injuries following blunt trauma. *World J Gastroenterol* 2007;13:633-6.
20. Nural MS, Yordan T, Guven H, Baydin A, Bayrak IK, Kati C. Diagnostic value of ultrasonography in the evaluation of blunt abdominal trauma. *Diagn Interv Radiol* 2005;11:41-4.
21. Nino-Murcia M, Brooke Leffrey R. Gastrointestinal tract and peritoneal cavity in: New York London MC. In: Gahan JP, Goldberg BB, Editors. *Diagnostic Ultrasound*. USA: Informa; 2008. p. 264-7.
22. Beck D, Marley R, Salvator A, Muakkassa F. Prospective study of the clinical predictors of a positive abdominal computed tomography in blunt trauma patients. *J Trauma* 2004;57:296-300.
23. Körner M, Krötz MM, Degenhart C, Pfeifer KJ, Reiser MF, Linsenmaier U. Current role of emergency US in patients with major trauma. *Radiographics* 2008;28:225-42.
24. Bakker J, Ginters R, Mali W, Leenen L. Sonographyultrasound as the primary screening method in evaluating blunt abdominal trauma. *J Clin Ultrasound* 2005;33:155-63.
25. Lee BC, Ormsby EL, McGahan JP, Melendres GM, Richards JR. The utility of sonographyultrasound for the triage of blunt abdominal trauma patient to exploratory laparotomy. *AJR Am J Roentgenol* 2007;188:415-21.

Source of Support: Nil, **Conflict of Interest:** None declared.