

Double tibial osteotomy for bow leg patients: A case series

Khalilollah Nazem, Arash Fouladi, Mozhdeh Chinigarzadeh

Department of Orthopedics, Isfahan Medical University, Isfahan, Iran

Background: High tibia osteotomy (HTO) is a common surgical operation for correction of genu varum deformity. In some patients, there are concurrent tibia vara and genu varum (bow leg). This study aimed to consider the possibility of better correction of bow leg deformity after double level tibial osteotomy (DLTO). **Materials and Methods:** A case series of 10 patients of genu varum in addition to tibia vara (bow leg) deformity who were referred to orthopedic ward of an academic hospital of Isfahan- Iran during 2009–2011 were included in the study. The mean age was 17.3 ± 3.1 years and all of them underwent DLTO. The results of treatment have been assessed based on clinical and radiological parameters before and after surgery. **Results:** The mean pre- and post operative values for Tibia-Femoral Angle, Medial Proximal of Tibia Angle (MPTA), and Lateral Distal of Tibia Angle (LDTA) were $18.13 \pm 3.05^\circ$ vs. $3.93 \pm 0.66^\circ$, $79.13 \pm 3.4^\circ$ vs. $89.7 \pm 1.8^\circ$ and $96.40 \pm 1.8^\circ$ vs. $88.73 \pm 3.0^\circ$ respectively ($P < 0.05$). Improvement of all radiological parameters was meaningful. Seventy three percent of patients had normal mechanical axis of limb after surgery. The remaining cases had varus deformity in distal femur that was corrected by valgus supracondylar osteotomy in an additional operation. Limited range of motion (ROM) near knee and ankle was not observed. **Conclusion:** DLTO correct bow leg deformity in the point of alignment of limb and paralleling of knee and ankle joint more effectively. This method can be used in metabolic and congenital bow leg which deformities are present in throughout of the lower limb. We described this technique for the first time.

Key words: Bow leg, double tibial osteotomy, genu varum, limb alignment, osteotomy, tibia

How to cite this article: Nazem Kh, Fouladi A, Chinigarzadeh M. Double tibial osteotomy for bow leg patients: A case series. J Res Med Sci 2013;18:1092-6.

INTRODUCTION

Deformity of the tibia and fibula is common. In this way, physiologic and developmental genu varum is extreme common pediatric deformities.^[1]

The most common etiology of genu varum is physiologic bowing resulting slower correction of varus angulation to neutral alignment.^[1] Presence of genu varum after 2 years of birthday can be considered abnormal.^[1-3] Pathologic etiologies include tibia vara, physeal disturbance (secondary to trauma, infection and tumor), metabolic bone disease, generalized skeletal dysplasia and focal fibrocartilage dysplasia.^[1,2]

The majority of patients with pathologic genu varum doesn't respond to non operative treatment and frequently need surgery.^[4] In this way, osteotomy is a well-established procedure for correction deformity.^[5] However, it is difficult to identify which patient and what amount of varus angulation benefit from osteotomy.^[6] Nevertheless the most important indications for surgical intervention are severe symptomatic genu varum, existence of some

medical conditions (i.e. abnormal gait, considerable limb dismorphic appearance, mild to moderate medial compartment osteoarthritis, lateral thrust) and progressive genu varum that not respond to conservative treatment.^[5]

The main object of corrective osteotomy in varus or valgus deformity of knee is obtaining near normal mechanical axis of lower limb, tibia and femur. In patients with bow leg who have tibia vara in addition to genu varum in tibia and fibula correction of genu varum by only high tibial osteotomy (HTO) could not be correct this axis completely. If we correct mechanical axis of limb by over correction of genu varum using open or close HTO, remaining deformities of lower limb are not acceptable cosmetically.

In the review of literature, HTO or supramaleolar osteotomy had been accessed alone but there aren't any studies that evaluate combination of these techniques. Therefore, this study aims to evaluate osteotomy at two levels, proximal and distal part of tibia, in patients with genu varum in addition to bow leg deformity which are not possible to correct at one level.

Address for correspondence: Dr. Mozhdeh Chinigarzadeh, Department of Orthopedics, Alzahra Hospital, Isfahan Medical University, Isfahan.
E-mail: dmchinigar@yahoo.com

Received: 30-09-2012; **Revised:** 14-01-2013; **Accepted:** 01-08-2013

MATERIALS AND METHODS

Between 2009 and 2011, 10 non consecutive patients (five females, five males included 15 lower extremity) have been studied. The inclusion criteria were genu varum in addition to bow leg. They all treated with double level tibial osteotomy (DLTO). There were no exclusion criteria. Five patients were operated on bilaterally. All cases parents filled and signed informed consent before surgical intervention. Correction of deformity was assessed based on changes in radiographic parameters following surgery. Limb alignment was measured by alignment view from the hip joint to the feet in the *anteroposterior* (AP) and lateral standing position before and 3 months after surgery. Also, mechanical axis, which is one of the main radiographic parameters for evaluating limb alignment, was considered for comparison. Normal mechanical axis crosses tibial plateau through middle third on AP standing view.

After completing sample volume and augmentation of data, data analysis was conducted by Statistical Package for Social Sciences (SPSS).

Surgical procedures

In a uniform designed procedure, the patients were positioned supine on the operating table under general or spinal anesthesia. Sterile smartch band was used as tourniquet. After determination of the level of osteotomy, at first the border of middle and distal third of the fibula (safe zone) was obliquely osteotomied. The tibial osteotomy was performed in a way medial open wedge or lateral closed wedge procedure. Based on decision that was taken before surgery, we used medial open wedge in proximal and lateral closed wedge in distal part of the tibia. Skin incision was made by anterior approach and periosteum is opened longitudinally and osteotomy was made at level of tibial tubercle or slightly proximal to it. In some cases, for better fixation, tibial tuberosity was osteotomied incompletely and HTO was done more inferiorly. Notably, it was important the lateral cortex remained intact as a hinge to maintain the stability of the level of osteotomy. The defect was closed by corticocancellus autologous bone graft (iliac) or allograft and the site of osteotomy was fixed by small T-plate. In two cases, after filling of the defect by auto graft (Press fit), the osteotomy sites were very stable and fixation was not needed. With short anterior longitudinal incision on the distal tibia, supra maleolar region was exposed subperiosteally. Open medial wedge or internal closed wedge was removed from supra maleolar region. In this osteotomy, we kept opposing cortex intact to prevent complete fracture of osteotomy site if it was necessary to fix it with cross pins. After surgery the alignment of limb was checked by extra medullary devices from hip to plafond. Then the smartch band was deflated and hemostasis was done. Finally, incision was closed [Figures 1-3].

We immobilized the limb in a long leg posterior splint and switched it to long leg cast 1-2 weeks later (after wound healing) for 4-8 weeks depending on fixation of osteotomy sites. After removal of cast, physiotherapy was done by active and passive range of motion (ROM) of knee and ankle and strengthening of muscles with partial weight bearing of limbs. After 3 months, the patients were relieved from crutches.

Results from this study were analyzed with SPSS 16. As there were little cases, we decided to use Willcoxon as a nonparametric test to compared pre and post operative measures.

RESULTS

Mean age of the participants was 17.3 ± 3.1 years. As shown in Table 1, mean pre and post operation Medial Proximal of Tibia (MPT) angle was 79.13 ± 3.4 and 89.7 ± 1.8 , respectively. Moreover, mean pre operative Lateral Distal of Tibia (LDT) angle was 96.40 ± 1.8 , and after that was $88.73 \pm 3.0^\circ$. Mean pre and post operative tibio femoral (varus) angle was 18.13° and $3.93^\circ \pm 0.66$, respectively.

In all of our patients, the leg mechanical axis crossed tibial platua through medial third before operation and after operation. Eleven legs (73%) had normal mechanical axis.

In three patients, mechanical axis crossed through medial third, and only in one patient, the mechanical axis was still medial to tibial plateau [Figures 4-6].

In two patients in which (four limbs) there were severe concurrent tibio femoral and hip deformity, as in one of them tibio femoral angle in two legs was 25° and 30° before surgery and later changed to 8° and 15° , respectively, after operation. These four limbs were candidate for correcting osteotomy in mentioned areas because of femur and hip deformity.

Non union or infection was not seen among the cases. There was one case of delayed union (5 months after surgery) that improved without any treatment.

DISCUSSION

Untreated pathologic genu varum result in none resolving and sometimes progressive varus deformity that produces

Table 1: Radiographic parameters before and after surgery

Variable	Before	After	P
MPTA	79.13 ± 3.4	89.70 ± 1.8	<0.001
LDTA	96.40 ± 1.8	88.73 ± 3	<0.001
TFA	18.13 ± 3.05	3.93 ± 0.66	<0.001

MPTA = Medial proximal of tibia angle, LDTA = Lateral distal of tibia angle, TFA = Tibiofemoral angle

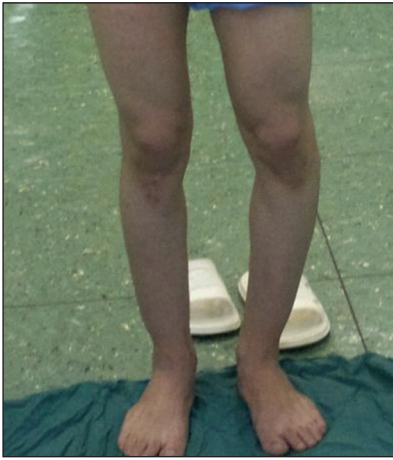

Figure 1: A 20 years boy with bilateral bow leg. Right leg (after operation) and left leg (before operation)

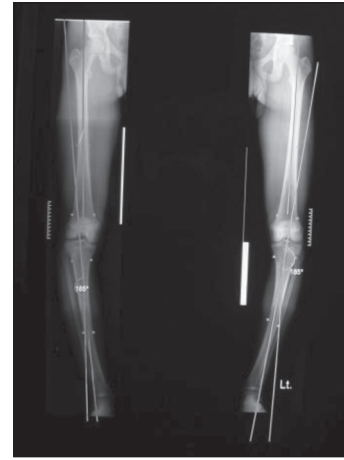

Figure 2: Alignment view before op

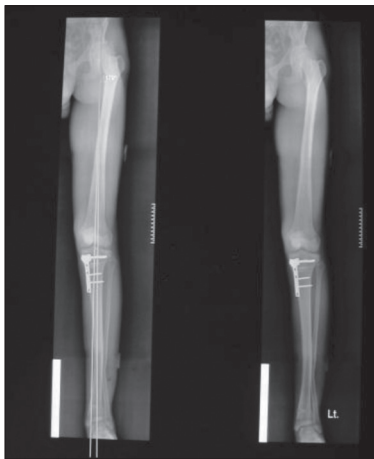

Figure 3: Alignment view after op

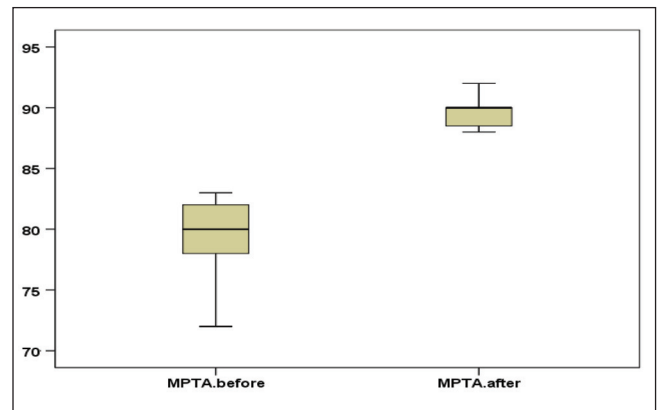


Figure 4: Distribution of MPTA (Medial Proximal of Tibia Angle) indexes before and after operation

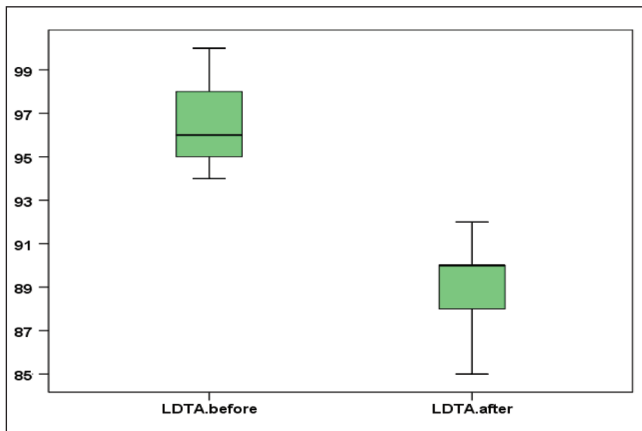


Figure 5: Distribution of double level tibial osteotomy (LDTA) indexes before and after operation

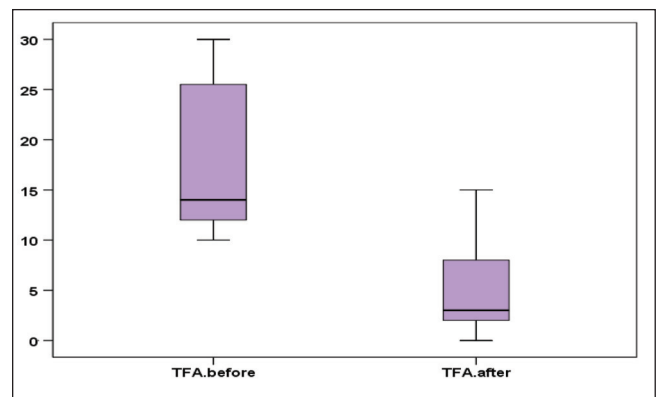


Figure 6: Distribution of TFA (Tibu Femoral Angle) indexes before and after operation

joint deformity, laxity and growth retardation which can be corrected only with complex surgical procedures. Therefore, surgical treatment is crucial to achieve permanent and durable correction and to avoid joint incongruity, limb shortening, and persistent angulation.^[1]

In young adult controversy exist yet regarding the effect of angular deformity on the ultimate outcome of joint, limb and exact risk of osteoarthritis. Parker *et al.*, using magnetic resonance imaging (MRI) in 50 patients found that subjective improvement in quality of life and pain relief was noted but there was not reported significant articular recovery following osteotomy.^[7]

Biomechanic studies have proved that valgus and varus deformity increased load on lateral or medial aspect of tibio femoral joint. Because hip, knee, and ankle joint have closed functional relationship together and malalignment in one of them can result malfunctioning of the others.^[5]

Sharmol *et al.*, observed 2,958 knees with varus or valgus deformity without osteoarthritis during 50 months they reported that 1,370 knees showed osteoarthritic changes and varus malalignment had greater risk of osteoarthritis comparing to valgus.^[8]

High tibial osteotomy was historically started by Langenbeck in 1845 and has been widely accepted since Coventry who first performed osteotomy proximal to the tuberosity in 1965.^[9]

Now-a-days, tibial osteotomy has an established place in the treatment of patient with varus knee.^[10]

The principle of correcting malalignment is to transfer load to the relatively normal compartment of the knee relief symptoms and suppress disease progression.^[9]

Although osteotomy in various studies resulted pain relief and quality of life improvement,^[7,9,10] but we should consider that the rate of complication in HTO is as high as 30-40% in several resources. Therefore, the main point is selecting the suitable patient for osteotomy.

According to previous publication, the ideal candidates are patients with age less than 60 years and isolated medial compartment involvement with normal knee ROM and stable ligamentous structure.^[12,13] The patients presented in our service were young people more than 14 years and young adult who suffered from genu varum and also bowing of proximal and distal part of the tibia.

Up to now many studies have been performed for severe limb malalignment such as osteotomy at distal of femur and proximal of the tibia.^[14,15]

Sara Gaglia *et al.*, recommended two level osteotomy around the knee joint for severe varus deformity more than 10° angle and then established that two level osteotomy may prevent joint obliquity.^[16] Several studies found two level osteotomy in tibia vara one near the joint surface and the other at tibial tubercle level, improve the general limb alignment.^[17,18]

Osteotomy at multiple levels is applied for corrective treatment in metabolic disease and also osteogenesis imperfecta.^[19] Bachhal *et al.*, made osteotomy for osteoarthritis of the medial compartment of the knee and attained to desired alignment.^[20] Osteotomy at two levels is accompanied with

more technical problem and complication. In cases in which osteotomy is made around the knee, it's usually accompanied with restricted knee ROM.

Ignoring the technique of osteotomy, the goal is accessing normal alignment and joint orientation.^[21] In most of our cases, deformity was related to a known underlying metabolic disease. Considering deformity in the whole of limb length, effective correction and accessing the favorable joint orientation was impossible just by one level osteotomy.

Investigating articles and references, no study has been found in which simultaneous osteotomy at two level-proximal and distal part of tibia was conducted to correct limb deformity. We innovatively used double tibial osteotomy including proximal part of the tibia and supra maleolar osteotomy.

Performing supra maleolar osteotomy other than proximal of tibia has the following benefits.

1. Supra maleolar osteotomy provides better correction of limb deformity that is impossible just by proximal level osteotomy.
2. In case of osteotomy with closed wedge in proximal and open wedge in distal area, we are able to use of proximal graft for distal correction and vice versa.
3. It's not producing more morbidity for patient who underwent this technique.
4. Because osteotomy in our study was done at two levels, it was not seen any complication such as limited ROM near knee and ankle that was usually seen in osteotomy around single joint like knee.

All of the cases mentioned a considerable improvement cosmetically in their limb and in cases that had deformity in both leg there were interested in being operation for the other affected limb. The results of this study showed that the mentioned parameters had considerable improvements after operation.

Following the surgery, there occurred an almost favorable correcting in varus angle and changed from mean varus angle correction $18.13 \pm 3.05^\circ$ to $3.93 \pm 0.66^\circ$ after surgery.

In two patients, there were severe simultaneous tibio femoral and hip deformities. After surgery, varus angle were changed to 8° and 15°. These patients were candidate for correcting osteotomy in mentioned area because of femor and hip deformity. Most part of high varus angle were related to more proximal level deformities which are not covered in our research, and in these four limbs, tibia related deformities was corrected with two level osteotomy and we obtained near to normal LDFA and MPFA after surgery despite primary deformity. Because of mentioned explains, mean varus angle remaining after surgery is accountable.

Although we obtained an almost favorable result following two level osteotomy but because of limited number of cases, it is not possible to define definite comprehensive guideline.

It seems that we can use standard double tibial osteotomy in patients with varus deformity more than 10°, in patients with genu varum in addition to bowing of middle and distal part of the tibia and in patient with increasing LDTA angle. To further development of this procedure, a long term study with more cases is recommended.

REFERENCES

- Herring JA. Tachdjian pediatric orthopaedics, 4th ed. USA: Sanders ELSEVIER; 2007. p. 973-96.
- Canale ST, James HB. Campbell's operative orthopaedics, 11th ed. USA: Mosby ELSEVIER; 2007.
- Cahuzac JP, Vardon D, Sales de Gauzy J. Deformities of lower limbs in the frontal plane in children. *Ann Pediatr (Paris)* 1993;40:230-6.
- Brooks WC, Gross RH. Genu varum in children: Diagnosis and Treatment. *J Am Acad Orthop Surg* 1995;3:326-35.
- Wolcott M, Traub S, Efirid C. High tibial osteotomy in the young active patient. *Int Orthop* 2010;34:161-6.
- Shim JS, Lee SH, Jung HJ, Lee HI. High tibial open wedge osteotomy below the tibial tubercle: Clinical and radiographic results. *Knee Surg Sports Traumatol Arthrosc* 2013;8:57-63.
- Parker DA, Beatty KT, Giuffre B, Scholes CJ, Coolican MR. Articular cartilage changes in patient with osteoarthritis after osteotomy. *Am J Sports Med* 2011;39:1039-45.
- Sharma L, Song J, Dunlop D, Felson D, Lewis CE, Segal N, *et al.* Varus and valgus alignment and incident and progressive knee osteoarthritis. *Ann Rheum Dis* 2010;69:1940-5.
- Ramsey DK, Snyder-Mackler L, Lewek M, Newcomb W, Rudolph KS. Effect of anatomic realignment on muscle function during gait in patient with medial compartment knee osteoarthritis. *Arthritis Rheum* 2007;57:389-97.
- Jackson IP, Waugh W. The technique and complication of upper tibial osteotomy. *J Bone Joint Surg Br* 1974;56:230-45.
- Kvan S, Smith B, Black A. Tibial wedge osteotomy: Complication of 300 surgical procedure. *Aust Vet J* 2002;87:438-44.
- Yanasse RH, Cavallari CE, Chaud FL, Hernandez AJ, Mizobuchi RR, Laraya MH. Measurement of tibial slope angle after medial opening wedge high tibial osteotomy: Case Series 2009;127:34-9.
- Hui C, Salmon LJ, Kok A, Williams HA, Hockers N, van der Tempel WM, *et al.* Long term survival of HTO for medial compartment osteoarthritis of the knee. *Am J Sports Med* 2011;39:64-70.
- Maccathy JJ, Maclyn NR. Double osteotomy for treatment of severe Blount disease. *J Pediatric Ortho* 2009;29:155-90.
- Iveson JM, Longton EB, Wright V. Comparative study of tibial (single) and tibiofemoral (double) osteotomy for osteoarthritis and rheumatoid arthritis. *Ann Rheum Dis* 1997;36:319-26.
- Saragadlia D, Mercier N, Colle PE. Computer assisted osteotomies for genu varum deformity: Which osteotomy for which varus? *Int Orthop* 2010;34:185-90.
- Bar-On E, Weigl DM, Becker T, Katz K. Treatment of severe blount disease by an intra articular and a metaphyseal osteotomy using the taylor spatial Frame. *J Child Orthop* 2008;2:457-61.
- Do TT. Clinical and radiographic evaluation of bowlegs. *Curr Opin Pediatr* 2001;13:42-6.
- Abolsaad M, Abdelrahman A. Modified soffield-millar operation: Less invasive surgery of lower limb in osteogenesis imperfecta. *Int Orthop* 2009;33:527-32.
- Bachhal V, Sankhala SS, Jindal N, Dhillon MS. High tibial osteotomy with adynamic axial fixator: Precision in achieving alignment. *J Bone Joint Surg Br* 2011;93:897-903.
- Babis GC, An KN, Chao EY, Rand JA, Sim FH. Double level osteotomy of the knee: A method to retain joint-line obliquity. Clinical results. *J Bone Joint Surg Am* 2002;84:1380-8.

Source of Support: Nil, **Conflict of Interest:** None declared.