

Case Report**A Case of the Rare Orofaciodigital Syndrome, Type I***E. Usefian*, F. Khozeime DDS*****ABSTRACT**

Oral-Facial-Digital Syndrome (OFDS) is a general term for several apparently distinctive genetic disorders. One of these is OFDS type I (OFDS-I) which has rarely been reported in Asian countries. Here, we present an 18 year old patient with OFDS type I, who referred to Isfahan University of Medical Sciences' Dental Clinic.

Key words: Oral-facial-digital syndrome, X-linked Genetic Disease, pathology, Renal failure

JRMS 2005; 10(4): 231-235

Oral-Facial-Digital Syndrome (OFDS) is a general term for several apparently distinctive genetic diseases¹. One of these is OFDS type one (OFDS-I) which was described by two French dentists Papillon-Léage E and Psaume Jean in 1954. For this reason, the syndrome was also named Papillon - Leage and Psaume Syndrome^{2, 3}. Gorlin et al, first reported this condition in the English literature⁴. Similar cases have been reported under a variety of names since 1860. Until now more than 200 cases have been reported⁵ and review articles suggested an incidence of 1/50000 to 1/250000 live births^{4,6}. It occurs in approximately 1.5/1000 patients with cleft lip, cleft palate, or both⁷. It has X linked dominant (XLD) inheritance with prenatal mortality in homozygous males whereas the other types of OFDS show autosomal recessive (AR) inheritance^{8,9}.

The most common feature of OFDS-I syndrome is a distinctive face with frontal bossing, nasal alar cartilage hypoplasia with flattening of nasal tip, broad nasal root, and hypertelorism. Oral findings include lobulated tongue, cleft lip and palate, numerous hyperplastic

frenulas (lingual, buccal, labial), lobulated tongue with hamartomatous growths, narrow upper lip, and dental anomalies. Hand malformations consist of brachydactyly (shortening), syndactyly (fusion), clinodactyly (curvature) and rarely polydactyly (extra fingers). Mild mental retardation and adult onset bilateral polycystic kidneys have also been reported^{2, 7, 10}. Cutaneous abnormalities include numerous milia, especially over the face and pinna, a patterned type of alopecia, and sparse, fine or coarse, dry lusterless hair⁷. OFDS-I is the most common pattern of OFDS and the only type in which skin lesions occur¹¹. The report of this syndrome in Asian countries is extremely rare¹².

Case Report

The patient, an 18-year-old girl, referred to Isfahan dental faculty's clinic for dental rehabilitation in October 2002. She was born full-term to healthy, not intermarried parents. Her mother had uneventful pregnancy with no perinatal complications. Her mother had experienced two spontaneous abortions already.

*Student of Dentistry, Isfahan Dental Students Research Committee (IDSRC), Isfahan University of Medical Sciences, Isfahan, Iran.

**Assistant Professor, Department of Oral Medicine, Faculty of Dentistry, Isfahan University of Medical Sciences, Isfahan, Iran.

Correspondence to: Ehsan Usefian, Isfahan Dental Student Research Committee (IDSRC), Faculty of Dentistry, Isfahan University of Medical Sciences, Isfahan, Iran. E-mail: usefian@dnt.mui.ac.ir

On clinical examination, the patient had multiple congenital abnormalities of the face, mouth, and extremities.

Oral cavity examination showed a partial pseudocleft of the upper lip extending through the vermilion, which had already been corrected (Figure 1), superior gingival cleft, lateral notching of alveolar ridge of upper and lower jaws, high arch palate, absence of teeth number 7, 8, 10, 22, 23, 24, 26, and impaction of tooth, tooth No 21 not erupted, malformation and malposition of the teeth and hypoplastic teeth (Figure 2,3), She had very short rami and flat midface due to zygomatic hypoplasia and increased cranial base angle (normal, $m=131\pm 4.5$) (Figure 4). Her tongue seemed to be partially lobulated. Physical examination revealed the following facial abnormalities: frontal bossing, ocular hypertelorism, abnormal eye movement, hypoplasia of alae nasi, low set ears (Figure 1), and some surgical defects of previous cystic millia removal and partial cleft of upper lip. Her nose was deviated to left (Figure 1). Dermatological examination revealed facial milia, numerous large milia in the hands and right foot, some of which had previously become cystic and had been removed surgically (Figure 5). She had rough, very dry, brittle and frequently suffered skin. The sweating was normal. She had 2-3 finger skin syndactyly of the left hand which had been previously corrected. Other features were brachydactyly of 1st and 3rd fingers of the right foot and clinodactyly of the 3rd and 5th fingers of the right hand, nail hypoplasia was observed on her right hand fingers (Figure 6). No abnormalities were seen on left foot but in right foot she had a cystic millia that had been corrected surgically when she was 16 years old. The presence of PCKD (Poly Cystic Kidney Disease) was not revealed by sonographic examination in this patient (Figure 6).

Discussion

Oral-facial-digital syndrome (OFDS) consists of a group of heterogeneous genetic disorders with different patterns of inheritance representing a spectrum of anomalies of the palate,

cranium, hands and feet. At least 11 types of this syndrome have so far been described¹³.

The facial abnormalities frequently observed in OFDS-I are nasal alar cartilage hypoplasia, frontal bossing, hypertelorism or dystopia canthorum with broad nasal bridge, and micrognathia with hypoplasia of the mandible ramus¹⁴⁻¹⁶. Clefts of the jaw and tongue in the area of the lateral incisors and canines, other malformations of the face and skull, malformation of the hands (specifically syndactyly, clinodactyly, brachydactyly and occasionally postaxial polydactyly) and mental retardation are also its features. Others include small nostrils, lobulated tongue with hamartomas, peculiarly irregular and asymmetric clefts of the palate, aberrant hyperplastic oral frenula, transient multiple milia on pinnae, and spotty alopecia. The abnormal oral frenula appear to lead to the clefting of jaw, tongue and upper lip. Orofaciodigital syndrome is one of the classic syndromes involving supernumerary teeth¹⁷ and demonstrating both hyperdontia and hypodontia (Others are Crouzon's disease, Down's syndrome and Hallermann-Streiff syndrome)^{18,19}. Its dermatologic findings include multiple milia, most commonly observed on the face, scalp, auricles, and back of the hands. These lesions tend to be present in large numbers and generally have a prolonged persistence. They may resolve spontaneously after the first year of life leaving pitted scars. They are very important because of their usefulness in making an early diagnosis, allowing adequate genetic counseling^{7,10}. Patchy alopecia has been reported in 65% of cases. The hair is rough, dry, and brittle. Numerous broken hairs are seen just above the scalp line. The hairs vary in diameter but have no specific abnormalities. The skin is frequently very dry and scales are more conspicuous on the upper part of the face and on the scalp. Their nails and sweating are normal.

The sex ratio (F:M) in affected siblings probably differs significantly from 1:1 to 2:1. Furthermore, an excessive number of abortions in affected siblings are thought to occur. X-linked dominant inheritance is suggested,

with the trait being lethal in the homozygous males.

It may be associated with a number of other syndromes, such as Ellis-van Creveld syndrome¹⁷⁻²⁰.

Sometimes adult onset polycystic kidney and/or liver and pancreatic polycystosis have been reported. The pathogenesis of the cysts is still unknown.

Acknowledgment

Authors would like to express special thanks to Behnaz Ebadian, Bijan Movahedian, Navid Askari and Majid Heidarpoor for their sincere cooperation.

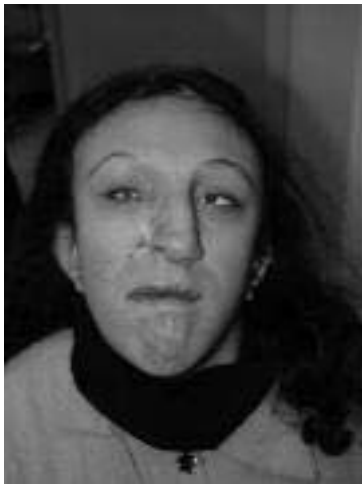

Figure 1. In full face view, we see asymmetric face and hypertelorism, corrected pseudo cleft of upper lip and scar of surgical milia removal.

Figure 2. High arch palate, absence of some teeth, short rami are seen in panoramic view.

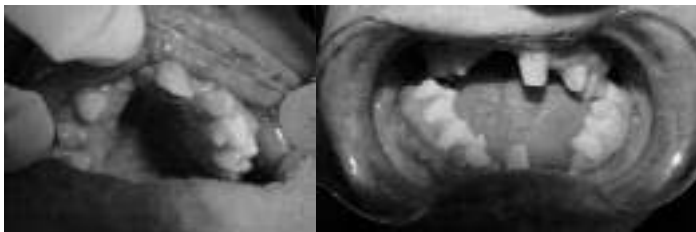
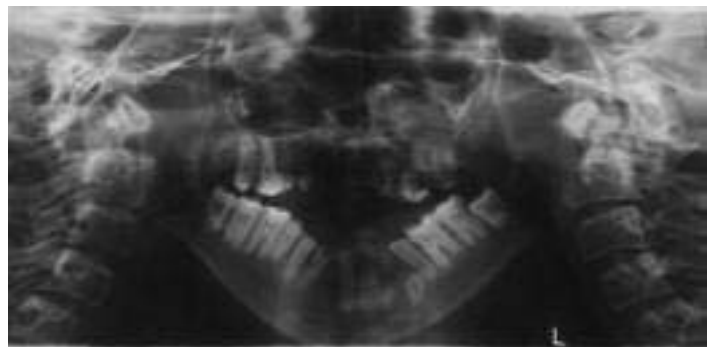


Figure 3. Abnormality of teeth and high palate.

Figure 4. Short rami and flat mid-face.

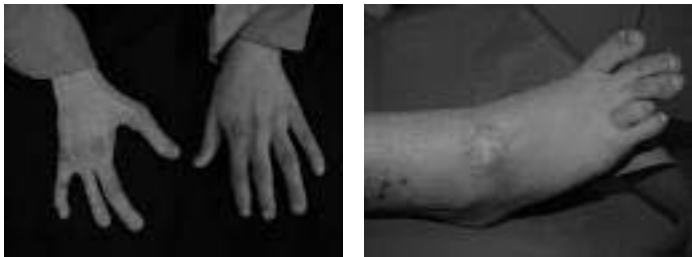
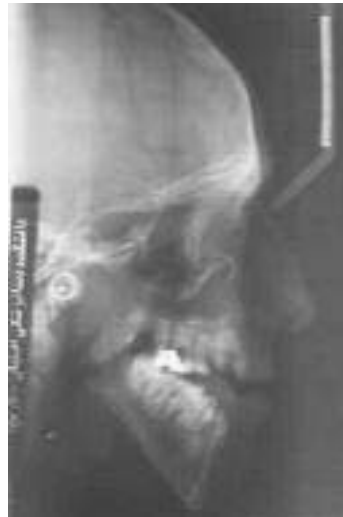
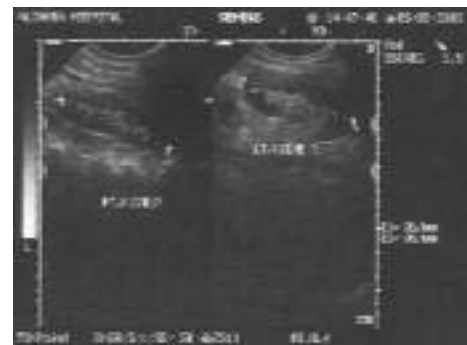Figure 5. Abnormality of fingers.

Figure 6. Normal kidneys in sonogram.



References

1. Papillon-Leage (Mme) and Psaume J. Une malformation hereditaire de muqueuse buccale : brides et freins anormaux. *Rev Stomatol (paris)* 1954;55: 209-227.
2. Gorlin RJ, Psaume J. orodigitofacial dysostosis – a new syndrome. *J pediatr* 1962; 61: 520- 530.
3. Orlin RJ, Cohen MM, Levin LS, editors. *Syndromes of the head and neck. Third ed. New York: Oxford University Press; 1990; 676-686.*
4. Gorlin, R. J.; Anderson, V. E.; Scott, C. R.: *Hypertrophied frenuli, oligophrenia, familial trembling and anomalies of the hand: report of four cases in one family and a forme fruste in another. New Eng. J. Med. 1961; 264: 486-489.*
5. Wiedemann H R, Kunze J , Grosse F R . *Clinical syndromes. 3rd ed .Canale, Italy; 1997:72.*

6. Wahrman J, Berant M, Jacobs J, Aviad I, Ben-Hur N. The oral-facial-digital syndrome: a male-lethal condition in boy with 47-XXY chromosomes. *Pediatrics* 1966; 37:812-821.
7. Solomon LM, Fretzin D, Pruzansky S. Pilosebaceous dysplasia in the oral-facial-digital syndrome. *Arch Dermat* 1970;102:598-602.
8. Orstavik KH, Tangsrud SE, Nordshus T, Finnanger AM, Hellum C, Gjessing E. Orofaciodigital syndrome type I in a girl with unilateral tibial pseudarthrosis. *J Med Genet.* 1992 Nov;29(11):827-30.
9. Orstavik KH, Tangsrud SE, Nordshus T, Finnanger AM, Hellum C, Gjessing E. Orofaciodigital syndrome type I in a girl with unilateral tibial pseudarthrosis. *J Med Genet.* 1992 Nov;29(11):827-30.
10. Habib K, Fraïtag S, Couly G, De Prost Y. Lesions cutanees du syndrome oro-digito-facial. *Ann Pediatr* 1992;39:449-452.
11. Habib K, Fraïtag S, Couly G, de Prost Y. [Cutaneous lesions in the orofacioidigital syndrome]. *Ann Pediatr (Paris)*. 1992 Sep;39 (7):449-52.
12. King NM, Sanares AM. Oral-facial-digital syndrome, Type I: a case report. *J Clin Pediatr Dent.* 2002 Winter;26(2):211-5.
13. Buno M, Pozo J, Munoz MT, Espejo M, Argente J. [Orofaciodigital syndrome associated with agenesis of the pituitary gland]. *An Esp Pediatr.* 2000 Apr;52(4):401-5.
14. Rimoin DL, Edgerton MT. Genetic and clinical heterogeneity in the oral-facial-digital syndrome. *J Pediatr.* 1967; 71 : 94-102.
15. Baraitser M. The oral-facial-digital syndromes. *J Med Genet* 1986;23:116-119.
16. Whelan DT, Feldman W, Dost I. The oral-facial-digital syndrome. *Clin Genet* 1975;8:205-212.
17. Pinkham J R .pediatric dentistry .3rd. W.B Saunders Company , Philadelphia ; 1994 , 44.
18. Pinkham J R .pediatric dentistry .3rd.w.B Saunders Company , Philadelphia ; 1994 , 45t.
19. Neville BW , et al . Oral & maxillofacial pathology . 2nd W.B. Saunders Company , Philadelphia;2002:70.
20. Neville BW , et al . Oral & maxillofacial pathology . 2nd W.B. Saunders Company , Philadelphia;2002: 69.