

Prediction of lumbar spine bone mineral density from the mandibular cortical width in postmenopausal women

Ehsan Hekmatin, Seyed Sina Ahmadi, Masoud Ataiekhorsagani¹, Mahboobe Feizianfard², Shahram Jafaripozve³, Nasim Jafaripozve

Department of Oral and Maxillofacial Radiology, Faculty of Dentistry, ¹ Department of Internal Medicine, Faculty of Medicine, ²Department of Endodontics, Faculty of Dentistry, Isfahan University of Medical Sciences, ³Resident of Radiology, Faculty of Medicine, Tehran University of Medical Sciences, Tehran, Iran

Background: Osteoporosis is one of the most common bone diseases that is characterized by a generalized reduction of the bone mass. Osteoporotic fractures are associated with morbidity, but can be a predictable condition if early diagnosis is made. The diagnosis is based on the World Health Organization's (WHO) T-score criteria. Panoramic images have been also used to predict low bone mineral density. The aim of the study was to evaluate the prediction of lumbar spine bone mineral density (BMD) from the mandibular cortical width in postmenopausal women. **Materials and Methods:** On the panoramic radiographic images, the mandibular cortical width (MCW) was measured by drawing a line parallel to the long axis of the mandible and another line tangential to the inferior border of mandible and a constructed line perpendicular to the tangent intersecting inferior border of mental foramen and analyzed the correlation of recorded MCW with BMD and T-score by using SPSS software and linear regression and bivariate correlation tests. **Results:** Bivariate correlation showed a significant correlation between BMD and MCW ($r = 0.945$) ($P = 0.000$). There was also a significant correlation between T-score and MCW ($r = 0.835$) ($P = 0.000$). To detect the accurate association between the BMD and MCW and also T-score and MCW, linear regression analyses tests showed two associations to predict the BMD and T-score from MCW with confidence interval of 95%. These associations were as follows:

T-score = $-7.087 + 1.497 \times \text{MCW}$

BMD = $0.334 + 0.163 \times \text{MCW}$.

Conclusion: The MCW is a good index to help the dentists to predict the osteoporosis by panoramic radiographs and have a significant role in patient screening and early diagnosis of osteoporosis.

Key words: Bone mineral density, osteoporosis, postmenopausal women

How to cite this article: Hekmatin E, Ahmadi SS, Ataiekhorsagani M, Feizianfard M, Jafaripozve S, Jafaripozve N. Prediction of lumbar spine bone mineral density from the mandibular cortical width in postmenopausal women. *J Res Med Sci* 2013;18:951-5.

INTRODUCTION

Osteoporosis is one of the most common bone diseases that is characterized by a generalized reduction of the bone mass.^[1] That is very common in the elderly, especially in postmenopausal women, due to decreased estrogen.^[2] Osteoporotic fractures are associated with morbidity and mortality and lead to significant financial burden on the affected individual, their family, and society.^[3,4] Osteoporosis can be a predictable condition if early diagnosis is made.

The diagnosis is based on the World Health Organization's (WHO) T-score criteria using central dual-energy X-ray absorptiometry (DEXA). According to the WHO diagnostic classification, osteoporosis is defined as a bone mineral density (BMD) at the hip

or spine less than or equal to 2.5 standard deviations below the young normal mean reference population.^[5] BMD values were divided into three groups of normal (T-score > -1.0), osteopenia (T-score, -2.5 to -1.0), and osteoporotic (T-score < -2.5).^[6,7]

At present, several studies have used dental radiographs, especially panoramic images, have been used to predict low BMD in patients.^[8-11] The oral cavity and jaws undergo regular radiographic examinations, so it is likely that the evaluation of a number of indices on panoramic radiographs are useful to assess bone mass density. These indices are related to the mandible and include the cortical index (CI), the mandibular cortical width (MCW), and the panorama index (PMI).^[2] It has shown that A thin mandibular cortical width correlates with reduced skeletal BMD.^[10,12,13]

Address for correspondence: Dr. Nasim Jafari Pozve, Oral and Maxillofacial Radiologist, Faculty of Dentistry, Isfahan University of Medical Sciences, Isfahan, Iran. E-mail: N. Jafari@dnt.mui.ac.ir

Received: 18-11-2012; **Revised:** 16-05-2013; **Accepted:** 25-08-2013

The panoramic-based mandibular indices efficacy in diagnosing osteopenia/osteoporosis is low to moderate.^[14] Some studies have not reported any relationship between these indices and BMD.^[15]

Commonly osteoporosis is not detected until a fracture occurs, so identification of postmenopausal women at high risk of fracture therefore is a priority and is especially important for women in early.^[16] Because many elderly individuals have more opportunities to visit a dental clinic than to visit a medical clinic for diagnosis of osteoporosis, this study was performed to evaluate the correlation between the width of the mandibular inferior cortex on panoramic radiographs and postmenopausal osteoporosis. This study not only used T-score but also BMD to predict the postmenopausal osteoporosis.

MATERIALS AND METHODS

This was a cross-sectional study. Healthy postmenopausal women who referred to the center of BMD assessment of Isfahan and Department of maxillofacial Radiology (Isfahan University of Medical Science, Faculty of Dentistry, Iran) between August 2010 and February 2012 were selected. The subjects were enrolled in the study if they had not experienced menstruation for at least 1 year. patients with systemic disease that had any effects on bone metabolism such as: Hyperparathyroidism, Hypoparathyroidism, Paget's disease, Osteomalacia, Renal osteodystrophy, Osteogenesis imperfect, cancers that metastasize to bone, history of use of special drugs or hormones that have any effects on bone metabolism, renal impairment, Bone destructive lesions in the jaw bones (such as malignant tumors or osteomyelitis) and vertebral or non-vertebral osteoporotic fractures and, diabetes were not included in the study. An informed consent form was obtained from the all of the patients. A consent form was filed and signed by all the participants.

For each patient a DEXA test result and a panoramic radiography are needed. The patient information was achieved in two ways:

1. Give an invitation form to patients that were referred to the bone densitometry centers and asked them to refer to the radiology department of the Isfahan Faculty of Dentistry.
2. Give an invitation form to the patients that were referred to the radiology department of the Isfahan faculty of dentistry and asked them to refer the BMD center and finally 52 cases were included in the study.

All of the panoramic radiographs were taken by Planmeca Promax Digital Panoramic X-ray unit (Planmeca Inc.,

Helsinki, Finland). Cortical width was assessed according to the technique explained by Ledgerton *et al.* at the mental foremen region, as follows:

To evaluate the radiographs, a line was drawn parallel to the long axis of the mandible and another line was drew tangential to the inferior border of the mandible and a constructed line perpendicular to the tangent intersecting inferior border of mental foramen, along which, mandibular cortical width was measured [Figure 1].

For accurate measurement of the mandibular cortical width and also to be able to return the radiographies to the patients, the radiographs were indirectly digitized with a laser Genius scanner (Genius HR6X Slim Scanner, China) with 600 dpi resolution and with negative method in 60 * 90 mm frame that included the region of interest (Inferior mandibular cortex at foramen mental region).

Then the scanned radiographs were transferred to a 64 megabyte graphic cards computer system and viewed via the monitor (F700P, LG, Korea).

We evaluated these scans by Photoshop software (Adobe Photoshop CS software, version 9) and measured the specified distance with the measurement device of this software. This device shows the measures of these distances in accuracy of 0.01 mm.

The width of the mandibular cortex in each scan was measured by this method two times and the mean of these two values was recorded for that region.

Both the left and right sides, the width of the mandibular cortex was measured and the mean was recorded as mandibular cortical width (MCW).

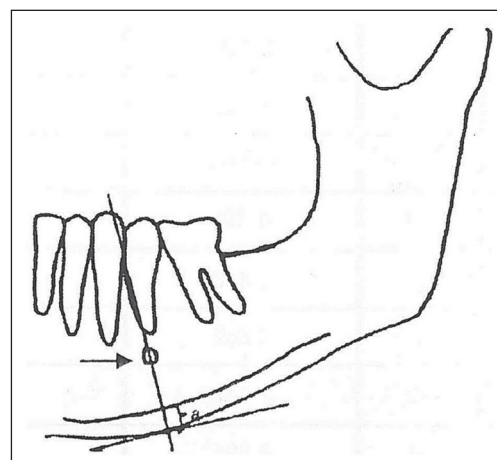


Figure 1: Schematic figure of the location of the mental foramen and lines that were used in the study. (a) is the mean cortical width and the arrow shows mental foramen

Evaluation of DEXA tests

All of the DEXA tests were performed by an expert technician using the bone densitometer (Explorer™-Hologic's Bone Densitometer, USA).

The results of this system were analyzed with smart scan software (version 4.7). So the BMD and T-Score of the lumbar spine region (L2-L4) were achieved .

Finally all of the data were statistically analyzed with the SPSS 18 Chicago, USA with confidence interval of 95% ($P < 0.05$). Correlation of recorded MCW with BMD and T-score was determined by linear regression and pearson correlation tests.

RESULT

Fifty-two postmenopausal women finally contributed to our study, The mean (SD) age of the subjects was 58.7+ – 12 years .The patients were classified according to WHO criteria (according to T-score) (reference?): 1) Normal group: includes 23 cases, 2) Osteopenic group: includes 14 cases , 3) Osteoporotic group: includes 15 cases. (Figure 2). The MCW mine was 3.90(Sd.deviation = 1.12). The mean BMD was 0.97 (Sd.deviation = 0.20). The mean T-score was -1.24 (Sd.deviation = 1.90)

To detect the correlation between the mandibular cortical width (MCW) and BMD and T- Score Pearson correlation coefficient (r) was used. Bivariate correlation showed a significant correlation between BMD and MCW ($P = 0.000$) and the Pearson correlation coefficient was 0.945. ($P = 0.000$). There was also a significant correlation between T- Score and MCW ($P = 0.000$) and the Pearson correlation was 0.835. ($P = 0.000$)

To detect the accurate association between the BMD and MCW and also T-score and MCW, linear regression analyses were performed. Linear regression tests showed association to predict the BMD and T- Score from MCW with confidence interval of 95%. These associations were as follows:
 T-Score = $-7.087 + 1.497 \times \text{MCW}$ [Figure 3].
 BMD = $0.334 + 0.163 \times \text{MCW}$ [Figure 4]

CONCLUSIONS

Panoramic radiography as an imaging technique is used by dental practitioners and some medical specialists. Information about bone density can be concluded from radiomorphometric indices of the mandible on panoramic radiographs like MCW.^[17-19] Cortical width on dental panoramic radiographs have been used as a suitable assessment methods. Mandibular cortical thickness in the mental regions in the panoramic radiographs is used

by Devlin *et al.* that showed showed the best agreement and specificity to evaluate osteoporosis so in this study cortical thickness measurement at mental foramen region is used.^[10]

In the previous study, mandibular cortical width in the mental foramen area was divided in the three normal, osteopenic, and osteoporotic groups based on lumbar densitometry, so our study was inconsistent with previous.^[17]

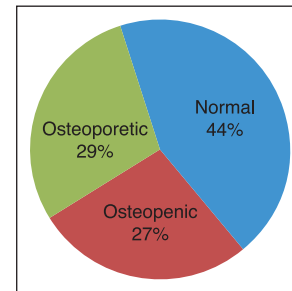


Figure 2: The frequency of the patients according to T-score

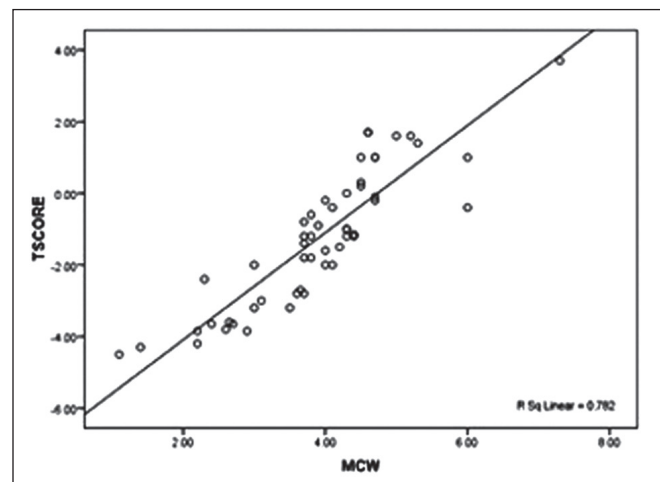


Figure 3: Scatter plot of association between T-score and MCW

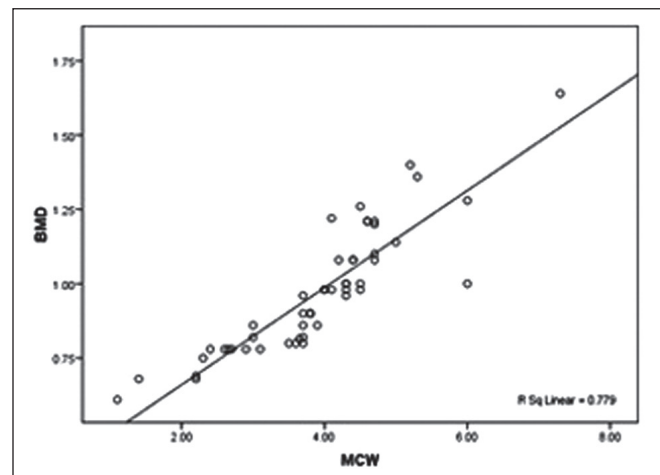


Figure 4: Scatter plot of association between BMD and MCW

The fact that dental radiographs are regularly made on a large fraction of the adult population makes their potential use as a marker of skeletal health an exciting avenue of research. The purpose of this article was to review the use of various intraoral as well as panoramic radiographs to promote early identification of patients at risk for osteoporosis.^[1]

In this study significant relation between vertebral BMD and T-score with the mandibular cortical width. The mean cortical widths of the osteopenic/osteoporotic groups were lower than that of the normal group. These correlations are similar to those found by^[17] Capor and Yüzügüllü have evaluated mandibular cortical width in men^[20] while Knezović Zlatarić suggest that the values is lower for women in comparison with men.^[21] Damilakis *et al.* believed that MCW in panoramic graphs is not useful as a screening test to find women with low BMD at the lumbar spine.^[22]

Other radiomorphometric indices like mandibular cortical index (MCI), panoramic mandibular index (PMI) and an alveolar crest resorption ratio (M/M ratio) were not evaluated in this study so studies with more population to evaluate this index is recommended. Another limitation of this study is that our subjects were postmenopausal women which are not represent of the normal population so further studies are recommended to plan a method on all the population instead of postmenopausal women only.

We found a correlation between BMD and T-score with MCW through a regression test, This association predicts the mean value of T-score and BMD from MCW. Mean MCW will decrease when T-score is decreased.

In conclusion, panoramic radiography is commonly used imaging technique by dentists which helps to diagnose the dental disease. Dentists have sufficient clinical and radiographic information that helps them to have a significant role in patient screening and early diagnosis of osteoporosis.

ACKNOWLEDGMENT

The authors wish to acknowledge the contribution of all patients and colleagues for their help with preparing the article. This work was supported by Isfahan University of Medical Sciences, Isfahan, Iran (No. 385043).

REFERENCES

- Aggarwal A, Panat SR. Identification of postmenopausal women at risk of osteoporosis using panoramic and intraoral radiographs- a review. *Minerva Stomatol* 2012;61:323-8.

- Johari Khatoonabad M, Aghamohammadzade N, Taghilu H, Esmaili F, Jabbari Khamnei H. Relationship Among Panoramic Radiography Findings, Biochemical Markers of Bone Turnover and Hip BMD in the Diagnosis of Postmenopausal Osteoporosis. *Iran J Radiol* 2011;8:23-8.
- Taguchi A, Ohtsuka M, Nakamoto T, Naito K, Tsuda M, Kudo Y, *et al.* Identification of post-menopausal women at risk of osteoporosis by trained general dental practitioners using panoramic radiographs. *Dentomaxillofac Radiol* 2007;36:149-54.
- Božić M, Ihan Hren N. A novel method of dental panoramic tomogram analysis: A perspective tool for a screening test for osteoporosis. *J Craniomaxillofac Surg* 2013;17:47
- World Health organization. Assessment of fracture risk and its application to screening of postmenopausal osteoporosis. Geneva, Switzerland: WHO; 1994.
- Harrison's Principles of Internal Medicine. 18th ed. In: Longo DL, Fauci AS, Kasper DL, Hauser S, Jameson JL, Loscalzo J, editors. New York: McGraw Hill; 2011.
- Goldman's Cecil Medicine. 24th ed. Ch: 251. In: Goldman L, Schafer AI, editors. Philadelphia: Saunder's Elsevier; 2012. p. 1577-88.
- López-López J, Estrugo-Devesa A, Jane-Salas E, Ayuso-Montero R, Gómez-Vaquero C. Early diagnosis of osteoporosis by means of orthopantomograms and oral x-rays: A systematic review. *Med Oral Patol Oral Cir Bucal* 2011;16:e905-13.
- Tözüm TF, Taguchi A. Role of dental panoramic radiographs in assessment of future dental conditions in patients with osteoporosis and periodontitis. *N Y State Dent J* 2004;70:32-5.
- Devlin H, Horner K. Mandibular radiomorphometric indices in the diagnosis of reduced skeletal bone mineral density. *Osteoporos Int* 2002;13:373-8.
- Marandi S, Bagherpour A, Imanimoghaddam M, Hatef M, Haghighi A. Panoramic-based mandibular indices and bone mineral density of femoral neck and lumbar vertebrae in women. *J Dent (Tehran)* 2010;7:98-106.
- Passos JS, Gomes Filho IS, Sarmiento VA, Sampaio DS, Gonçalves FP, Coelho JM, *et al.* Women with low bone mineral density and dental panoramic radiography. *Menopause* 2012;19:704-9.
- Khojastehpour L, Afsa M, Dabbaghmanesh MH. Evaluation of Correlation between Width and Morphology of Mandibular Inferior Cortex in Digital Panoramic Radiography and Postmenopausal Osteoporosis. *Iran Red Crescent Med J* 2011;13:181-6.
- Drozdowska B, Pluskiewicz W, Tarnawska B. Panoramic-based mandibular indices in relation to mandibular bone mineral density and skeletal status assessed by dual energy X-ray absorptiometry and quantitative ultrasound. *Dentomaxillofac Radiol* 2002;31:361-7.
- Dagistan S, Bilge OM. Comparison of antegonial index, mental index, panoramic mandibular index and mandibular cortical index values in the panoramic radiographs of normal males and male patients with osteoporosis. *Dentomaxillofac Radiol* 2010;39:290-4.
- Delaney MF. Strategies for the prevention and treatment of osteoporosis during early postmenopause. *Am J Obstet Gynecol* 2006;194:S12-23.
- Vlasiadis KZ, Skouteris CA, Velegarakis GA, Fragouli I, Neratzoulakis JM, Damilakis J, *et al.* Mandibular radiomorphometric measurements as indicators of possible osteoporosis in postmenopausal women. *Maturitas* 2007;58:226-35.
- Taguchi A. Triage screening for osteoporosis in dental clinics using panoramic radiographs. *Oral Dis* 2010;16:316-27.
- Nakamoto T, Taguchi A, Ohtsuka M, Suei Y, Fujita M, Tanimoto K, *et al.* Dental panoramic radiography as a tool to detect

- postmenopausal women with low bone mineral density: Untrained general dental performance. *Osteoporos Int* 2003;14:659-64.
20. Cakur B, Dağistan S, Sümbüllü MA. No correlation between mandibular and non-mandibular measurements in osteoporotic men. *Acta Radiol* 2010;51:789-92
21. Zlatarić DK, Celebić A, Kobler P. Relationship between body mass index and local quality of mandibular bone structure in elderly individuals. *J Gerontol A Biol Sci Med Sci* 2002;57:M588-93.
22. Damilakis J, Vlasidis K. Have panoramic indices the power to identify women with low BMD at the axial skeleton? *Phys Med* 2011;27:39-43.

Source of Support: Isfahan University of Medical Sciences, Faculty of Dentistry and Torabinejad Research Center, **Conflict of Interest:** None declared.