

# Duplication of the inferior vena cava and thrombosis: A rare case

Babak Tamizifar, Parisa Seilani<sup>1</sup>, Maryam Rismankar zadeh<sup>2</sup>

Departments of Cardiology, School of Medicine, <sup>1</sup>Departments of Internal Medicine, <sup>2</sup>Alzahra Hospital, Isfahan University of Medical Sciences, Isfahan, Iran

Duplication of inferior vena cava (IVC) is a rare finding in radiologic studies and its coincidence with thrombosis is even rarer. Here we described a rare case with duplication of IVC and symptomatic venous thrombosis of her lower extremity.

**Key words:** Computed tomography, double inferior vena cava, inferior vena cava, venous anomaly, venous thrombosis

**How to cite this article:** Tamizifar B, Seilani P, Rismankarzadeh M. Duplication of the inferior vena cava and thrombosis: A rare case. *J Res Med Sci* 2013;18:911-3.

## INTRODUCTION

Venous thromboembolism (VTE), is the third leading cause of cardiovascular mortality. VTE typically originates as deep venous thrombosis (DVT) in a lower extremity.<sup>[1]</sup> The incidence of DVT is estimated at 1 in 1,000 individuals/year.<sup>[1]</sup> It varies with age, and in young adults aged between 20 and 40 years, the incidence is 10 times lower.<sup>[2]</sup>

Duplication of inferior vena cava (IVC) is a rare finding in radiologic studies. The incidence is about 0.2-3%. Its symptomatic presentation is even rarer. There are few reported cases with IVC duplication and thrombosis of lower extremities.<sup>[2-7]</sup>

Its main differential diagnosis is lymphadenopathy, aortic aneurysm, and retroperitoneal cysts. In a few case reported articles, the duplication of the IVC may be associated with the recurrence of pulmonary thromboembolism if the anatomical variation goes undiagnosed.<sup>[2]</sup>

## CASE REPORT

Our patient was an 18-year-old girl with recent onset right leg pain and swelling with extension to her inguinal area. She also had dyspnea with respiratory distress. At the time of presentation, she was ill and febrile. She also had pitting edema of right leg and significant size difference between circumferences of her two legs. On the day of admission, she suddenly

presented with dyspnea and severe thoracic pain on the right side. All other physical examination was normal.

She had no predisposing factor for venous thrombosis. Besides, she had no known a history of DVT, clotting disorders, recurrent abortion, peripheral vascular disease, non-healing ulcerations on the extremities, cerebrovascular accidents or taking oral contraceptive pills.

Her laboratory data showed only mild normochromic, normocytic anemia, elevated erythrocyte sedimentation rate (ESR) to 75 (normal range less than 25) and CRP = 16 (normal less than 8). Other laboratory test including renal, electrolytes, liver, and urine analysis and culture were normal.

Color duplex ultrasound study demonstrated deep venous thrombi in the right popliteal, superficial and common femoral veins, with external iliac vein.

In addition, hypercoagulable workup was revealed no abnormal finding and also negative for antiphospholipid syndrome and lupus anticoagulant antibodies.

A multi-detector computed tomography (CT) pulmonary angiography of the chest defined pulmonary emboli in the territory of right main and segmental branch pulmonary artery and suggesting extensive infarction of the right middle pulmonary lobe. She was subsequently started on a low molecular weight heparin (Clexane®: 60 mg, every 12 h SC). Subsequently, CT of the abdomen and CT angiography with IV contrast injection carried

**Address for correspondence:** Dr. Babak Tamizifar, Department of Internal Medicine, School of Medicine, Isfahan University of Medical Sciences, Isfahan, Iran. E-mail: tamizib@med.mui.ac.ir

**Received:** 28-11-2012; **Revised:** 03-02-2013; **Accepted:** 09-04-2013

out after the procedure confirmed duplication of the IVC [Figure 1]. Both two IVC originate in the pelvis, run parallel to each other, bordering the aorta and left-sided IVC drained into the left renal vein. There was no other pathologic finding in thoracic and abdominopelvic CT studying.

After fully anticoagulated with low molecular weight heparin for 5 days and starting warfarin international normalized ratio (INR) range was between 2 and 3, she was discharged from hospital and was not symptomatic in her follow-up until next 3 months. According to the previous studies, for this patient we planned to continue anticoagulant therapy for 6 months.<sup>[2,3]</sup>

## DISCUSSION

In the United States, a first episode of VTE occurs in about 100 persons/100,000 each year. The incidence rises dramatically with age, with 5 cases/1,000 persons/year by the age of 80 years. Acquired risk factors for VTE include advanced age, history of previous VTE, obesity, and active cancer, all of which limit mobility, damage to endothelium and may be associated with hypercoagulability.<sup>[1,2]</sup>

Over the last 100 years, case series involving IVC duplication in association with VTE number less than 10.<sup>[2]</sup> The majority of cases of double IVC are diagnosed accidentally by imaging for other reasons, but these anomalies can have a significant clinical implications.<sup>[3]</sup> The first case reports of IVC duplication refer to first decade of previous century. The formation of the IVC is a complex event that has been well described. It is formed between the 6<sup>th</sup> weeks and 8<sup>th</sup> weeks of embryonic development via a series of anastomoses and regressions of the primitive trunk including: Posterior cardinal veins, subcardinal veins, and supracardinal veins.<sup>[4]</sup> During the normal embryogenesis, the left subcardinal and left supracardinal veins regress. Failure of normal regression

of any of the paired venous structures leads to abnormal persistence, duplication, or both.<sup>[5]</sup>

Phlebography is indicated as the gold standard for diagnosing duplication of the IVC.<sup>[5]</sup> but due to invasiveness, other authors have recommended that the combination of CT and ultrasound are satisfactory for an adequate diagnosis. In a case report of IVC duplication, there is a normal IVC along the right side of the spine.<sup>[2]</sup> In our patient, the right external iliac vein was found to be thrombosed but right and left-sided IVCs were free of clot.

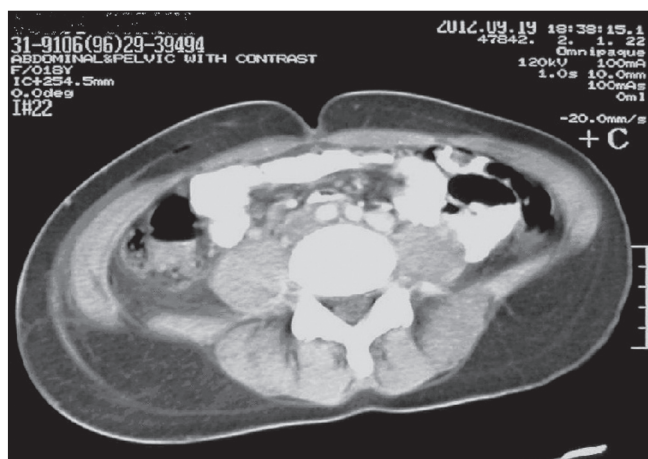
In a literature search, among patients with complicated and duplicated IVC, age of presentation of first thrombosis, in most reports was less than 35 years of age and there was no difference between men and women.<sup>[2-7]</sup> Few studies consider double IVC to be the cause of DVT, perhaps due to retrograde stasis.<sup>[6,7]</sup> Gayer described nine cases in which DVT coincided with anomalies in which part or all of the superior or IVC.<sup>[6]</sup> He concluded that venous return difficulty caused stasis and thereby increased the probability of thrombosis.<sup>[4]</sup> Although, Milani *et al.* argued that patients with duplication of the IVC may have a propensity for developing thrombosis.<sup>[2,4]</sup> They concluded that DVT might be associated with other routine pre-existing illnesses, such as lower limb fractures, cancer, the use of hormonal contraceptives, prior abdominal surgeries in elderly patients, genetic predisposition to thrombosis.

Treatment choices include observation for asymptomatic duplication, anticoagulation therapy, placing an IVC filter below the renal veins in both the main right IVC and the duplicated left IVC segment or insertion a single suprarenal filter in the main IVC with concomitant embolization for anomalous vein. We preferred the most appropriate approach to treatment for more than 6 months' anticoagulation while the principal factor provoking thrombosis continues.

In our problematic case, no other routine trigger factor for developing DVT was found. This case demonstrates the importance of IVC duplication in the presence of DVT, the challenge of diagnosis, and the various therapeutic options available for a symptom-causing IVC duplication as some previous studies make a point of it.<sup>[2-6]</sup>

## REFERENCES

1. Morris TA. Natural history of venous thromboembolism. *Crit Care Clin* 2011;27:869-84.
2. Milani C, Constantinou M, Berz D, Butera JN, Colvin GA. Left sided inferior vena cava duplication and venous thromboembolism: Case report and review of literature. *J Hematol Oncol* 2008; 1:24-28.
3. Ng WT, Ng SS. Double inferior vena cava: A report of three cases. *Singapore Med J* 2009;50:e211-3.



**Figure 1:** Abdominopelvic computed tomography representing duplication of inferior vena cava

4. Saad KR, Saad PF, Amorim CA, Armstrong D, Soares BL, Neves PC, *et al.* Duplication of the inferior vena cava: Case report and a literature review of anatomical variation. *J Morphol Sci* 2012;29:60-4.
5. Anne N, Pallapothu R, Holmes R, Johnson MD. Inferior vena cava duplication and deep venous thrombosis: Case report and review of literature. *Ann Vasc Surg* 2005;19:740-3.
6. Gayer G, Luboshitz J, Hertz M, Zissin R, Thaler M, Lubetsky A, *et al.* Congenital anomalies of the inferior vena cava revealed on CT in patients with deep vein thrombosis. *AJR Am J Roentgenol* 2003;180:729-32.
7. Chee YL, Culligan DJ, Watson HG. Inferior vena cava malformation as a risk factor for deep venous thrombosis in the young. *Br J Haematol* 2001;114:878-80.

**Source of Support:** Nil, **Conflict of Interest:** None declared.