

Case Report

A case of fibrolipomatous hamartoma of nerve arising from superficial peroneal nerve

*Ahmad Sobhan Ardakani**, *Pardis Nematolahi***, *Fereshteh Mohammadizadeh****,
*Mohammad Reza Akhoondinasab*****

Abstract

Fibrolipomatous hamartoma of nerve (neural fibrolipoma) is a tumor-like lipomatous process principally involving young persons. The median nerve is most commonly affected. The lesion is characterized by a soft slowly growing mass surrounding and infiltrating major nerves and their branches. It may cause symptoms of compression neuropathy and is associated with macrodactyly in one third of cases. Here, we present a case of neural fibrolipoma in the ankle region and dorsum of foot of a young man arising from superficial peroneal nerve.

KEY WORDS: Fibrolipomatous hamartoma, neural fibrolipoma, macrodactyly, superficial peroneal nerve.

JRMS 2007; 12(5): 271-274

Fibrolipomatous hamartoma of nerve (neural fibrolipoma) is a tumor-like lipomatous process principally involving the young persons¹. It usually manifests as a soft slowly growing mass consisting of proliferating fibrofatty tissue surrounding and infiltrating major nerves and their branches¹⁻³. About one third of neural fibrolipomas are associated with macrodactyly^{1,3,4}. The lesion is almost always seen during the first three decades of life, usually presenting with increasing pain, diminished sensation or paresthesia associated with a gradually enlarging mass causing compression neuropathy¹. Males are more often affected than females. There may be a genetic predisposition, but there is no history of any hereditary disorders¹. At operation, the lesion presents as a soft gray-yellow fusiform

sausage-shaped mass that has diffusely infiltrated large nerves¹. The median nerve is affected in most cases^{1,3,5}. Here, we present a case of neural fibrolipoma of the superficial peroneal nerve in the ankle region of a young man.

Case report

A 30-year-old man presented with a soft tissue mass in the left ankle and dorsum of foot associated with macrodactyly, especially of the forth toe. He had the history of amputation of the second and third toes for macrodactyly 15 years ago. The patient had this lesion congenitally with gradual enlargement. He complained of neurologic symptoms of pain and paresthesia. Physical examination revealed a soft tissue mass in the anterior aspect of the

*Associate Professor, Department of Pathology, School of Medicine, Isfahan University of Medical Sciences, Isfahan, Iran.

**Anatomical & Clinical Pathologist, Isfahan, Iran.

***Assistant Professor, Department of Pathology, School of Medicine, Isfahan University of Medical Sciences, Isfahan, Iran.

e-mail: mohammadizadeh@med.mui.ac.ir. (Corresponding Author)

****Plastic Surgeon, Assistant Professor, Department of Surgery, School of Medicine, Isfahan University of Medical Sciences, Isfahan, Iran.

ankle resulting in massive enlargement of the ankle and foot (figure 1). The neurological symptoms were compatible with compression neuropathy. Excisional biopsy of the lesion revealed superficial peroneal nerve trunk surrounded and infiltrated by fibrofatty tissue. The epineurium of the affected nerve was also expanded by fibrous tissue and fat (figure 2). Macroscopically, the lesion was composed of a soft tissue mass measuring 10 X 5 X 1.5 cm with rather soft consistency and solid yellow to

white-gray cut surface (figure 3). Microscopically, the mass was characterized by an admixture of atrophied nerve fascicles and fibrofatty tissue proliferation with thick collagen bundles (figures 4 and 5). Considering all of the clinical, surgical and pathological findings, our final diagnosis was fibrolipomatous hamartoma of nerve, also known as neural fibrolipoma. Follow up of the patient five months after the operation has not shown any recurrence.

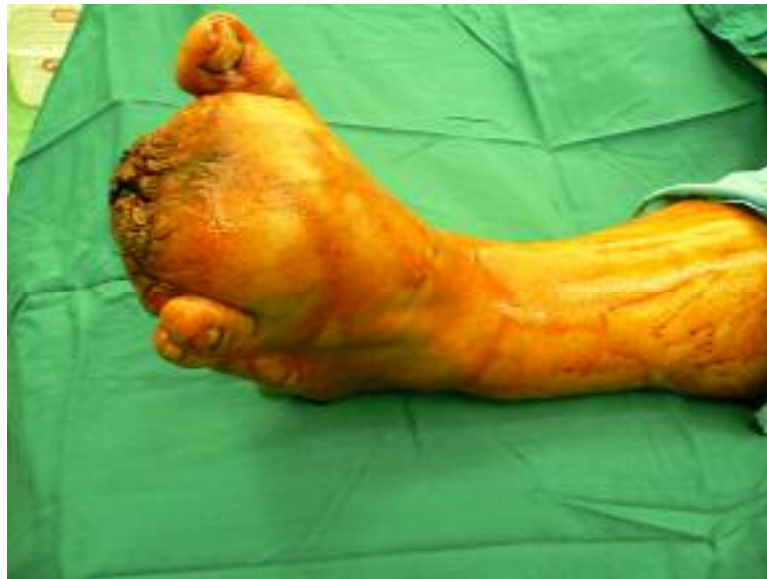

Figure 1. Clinical appearance of dorsum of foot and ankle of the patient before operation.

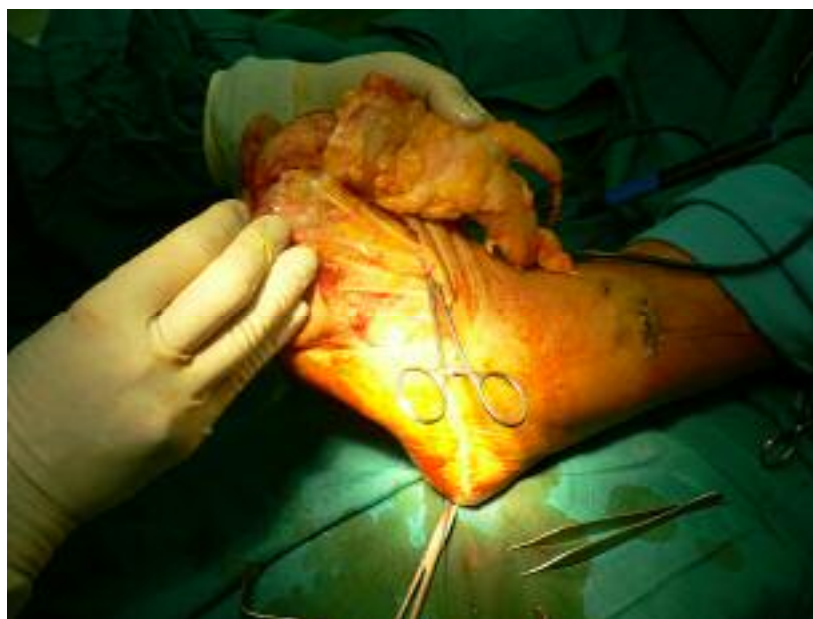

Figure 2. The mass as revealed at surgery.

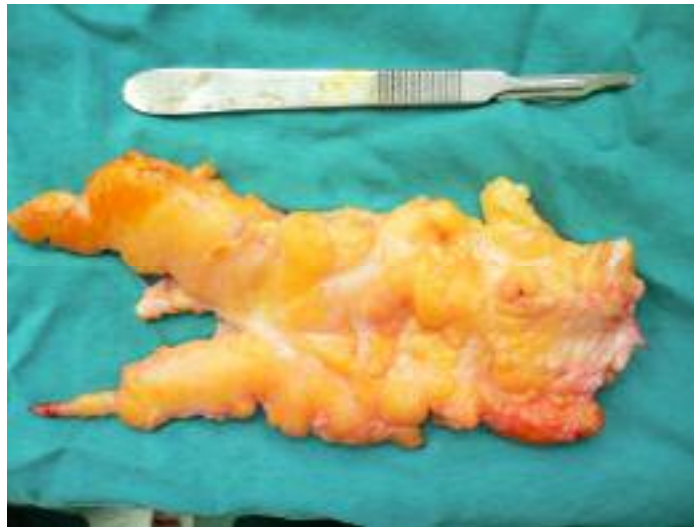

Figure 3. Gross features of the lesion showing a mass with rather soft consistency and yellow to white-gray color.

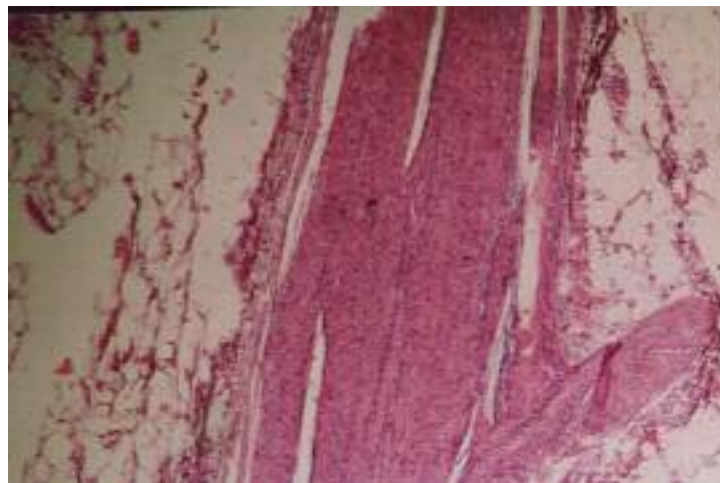


Figure 4. Microscopic appearance of the lesion showing fatty tissue, dense fibrosis and a nerve fascicle (X100).

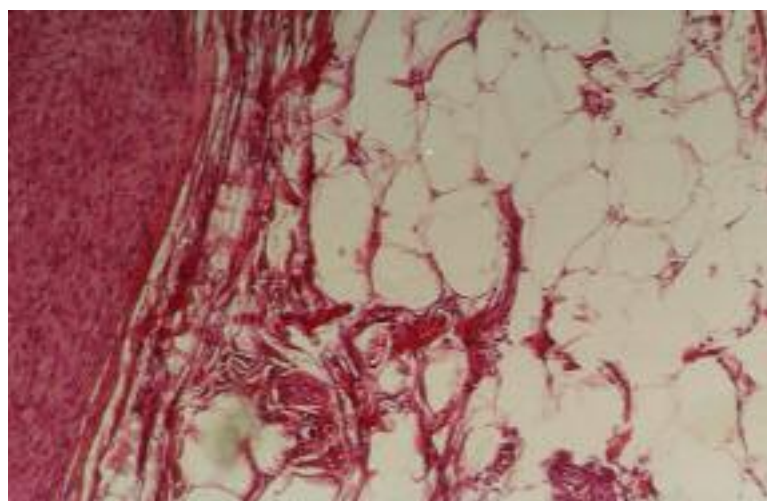


Figure 5. High power view of the lesion showing fibrofatty tissue (X400).

Discussion

Neural fibrolipoma is considered as a fibrolipomatous hamartoma of nerve. Rare cases show foci of metaplastic bone¹. Although median nerve is involved in most cases, involvements of ulnar nerve, other nerves of upper extremity and those of the dorsum of the foot have also been reported^{1-3,5-7}. The histogenesis of fibrofatty overgrowth of nerve is disputed. Mature fat cells have been described within the normal nerve sheath and it is thought that proliferation of these cells leads to the fatty enlargement of the nerve and its coverings. The relationship of these neural changes to the development of macrodactyly remains controversial³. The diffuse infiltrative character of the lesion distinguishes it from localized lipoma of nerve¹. Cutaneous lipomatous neurofibroma, a variant of neurofibroma, should also be considered in differential diagnosis. However, neural fibrolipoma shows atrophy rather than proliferation of neural elements, observed in neurofibroma⁸⁻¹⁰. Another differential diagnosis is diffuse lipomatosis. This is a

lesion of subcutis and muscle and only secondarily affects nerves¹. Although MRI is an important tool in diagnosis, it should be supported by a tissue biopsy. There is no effective therapy for neural fibrolipoma. Treatment for patients with no neurologic deficit involves prophylactic decompression of affected nerves at all points of possible compression. Patients with macrodactyly may benefit from debulking, joint reconstruction or amputation⁴. Complete excision is contraindicated in some cases because it may cause severe sensory or motor disturbances¹. Follow up of patients in most reports has shown a benign course following complete excision. However, local recurrence has developed in rare cases^{3,4,7}.

Conclusion

Neural fibrolipoma should be considered as a differential diagnosis whenever a lipomatous lesion is encountered involving neural tissues in upper extremity, foot or ankle, especially when associated with macrodactyly.

References

1. Weiss S, Goldblum JR. **Enzinger and Weiss's soft tissue tumors**. 4th ed. St.Louis: Mosby; 2001. 617-619.
2. Akisue T, Matsumoto K, Yamamoto T, Kizaki T, Fujita I, Yoshiya S et al. **Neural fibrolipoma of the superficial peroneal nerve in the ankle: a case report with immunohistochemical analysis**. *Pathol Int* 2002; 52(11):730-733.
3. Silverman TA, Enzinger FM. **Fibrolipomatous hamartoma of nerve. A clinicopathologic analysis of 26 cases**. *Am J Surg Pathol* 1985; 9(1):7-14.
4. Razzaghi A, Anastakis DJ. **Lipofibromatous hamartoma: review of early diagnosis and treatment**. *Can J Surg* 2005; 48(5):394-399.
5. Meyer BU, Roricht S, Schmitt R. **Bilateral fibrolipomatous hamartoma of the median nerve with macrocheiria and late-onset nerve entrapment syndrome**. *Muscle Nerve* 1998; 21(5):656-658.
6. Bibbo C, Warren AM. **Fibrolipomatous hamartoma of nerve**. *J Foot Ankle Surg* 1994; 33(1):64-71.
7. Kakitsubata Y, Theodorou SJ, Theodorou DJ, Shibata M, Yuge M, Yuki Y et al. **MR imaging of uncommon recurrence of fibrolipomatous hamartoma of the ulnar nerve**. *Acta Radiol* 2003; 44(3):326-328.
8. Val-Bernal JF, de sa Dehesa J, Garijo MF, Val D. **Cutaneous lipomatous neurofibroma**. *Am J Dermatopathol* 2002; 24(3):246-250.
9. Val-Bernal JF, Gonzalez-Vela MC. **Cutaneous lipomatous neurofibroma: characterization and frequency**. *J Cutan Pathol* 2005; 32(4):274-279.
10. Ahn SK, Ahn HJ, Kim TH, Hwang SM, Choi EH, Lee SH. **Intratumoral fat in neurofibroma**. *Am J Dermatopathol* 2002; 24(4):326-329.