

Sprengel deformity and Klippel-Feil syndrome leading to cervical myelopathy presentation in old age

Seyyed Ahmad Mirhosseini, Seyyed Mohammad Mahdy Mirhosseini¹, Reza Bidaki², Ahmad Pourrashidi Boshrabadi³
 Department of Neurosurgery, ¹Isfahan University of Medical Sciences, Isfahan, ²Psychiatrist, ³Rafsanjan University of Medical Sciences, Rafsanjan, Iran

Klippel-Feil syndrome is a rare condition characterized by the congenital fusion of two of the seventh cervical vertebrae. A 50-year-old woman presented with a 2-year history of neck pain and ataxia for 1 year. She had not urinary incontinence. She was referred to a neurosurgeon by a neurologist because of her progressive gait ataxia. Risk for brachial plexus injury because of compression or stretching by the clavicle accelerate with age. Therefore, the surgical approach of adults' patients with Sprengel's deformity can intend suitable surgical conclusions.

Key words: Cervical myelopathy, Klippel-Feil syndrome, omovertebral bone, Sprengel deformity

How to cite this article: Mirhosseini SA, Mirhosseini SMM, Bidaki R, Boshrabadi AP. Sprengel deformity and Klippel-Feil syndrome leading to cervical myelopathy presentation in old age. J Res Med Sci 2013;18:526-8.

INTRODUCTION

Klippel-Feil syndrome (KFS) is a rare condition characterized by the congenital fusion of any two of the seventh cervical vertebrae.^[1] Sprengel's deformity (SD) is a congenital structural abnormality of the shoulder girdle; receive surgical treatment as a child or adolescence. Therefore, it is rare to identify an adult with untreated SD.^[2] Neurological complications are various such as spastic paraplegia, mental weakness, and syringomyelia.^[3]

The omovertebral bone is characterized as an abnormality in the musculoskeletal system. In this anomaly, scapula, and the cervical spine are connected to each other.^[4] However, some studies reported association between SD and omovertebral bone and introduced it as KFS.^[2] Shoulder girdle anomaly concomitant with muscle disorder such as hypoplasia or atrophy are called SD.^[1,5] Vertebral fusion of cervical spines is rare, but it is possible to occur in that spines. This rare situation is seen in the KFS.^[2] Maurice Klippel and Andre Feil separately described this syndrome for first time in 1912. First symptoms that they explained were including short neck, restricted motion of the neck, and low hairline. After that time, some patients with same features are reported.^[6] The prevalence of this syndrome is unclear, but some studies believe that its prevalence is about 1 in 40,000 of alive newborns.^[7] Furthermore, this syndrome affect female more than male.^[7]

It should be considered in the setting of neurological symptoms characteristic of cervical myelopathy in patients with obvious skeletal dysmorphias of unknown etiology.^[8] Short neck, low hairline, and restricted neck motion are diagnostic triad is present in less than half of the patients.^[9] We report a 50-year-old woman who suffered from neck pain and ataxia for a long time. To the best of our knowledge, there is one study that presented a patient with this topic.^[8]

CASE REPORT

A 50-year-old woman admitted to the Alzahra Hospital, Isfahan, Iran. She presented with a 2 years history of neck pain and ataxia for 1 year. She hadn't urinary incontinence and she was referred to a neurosurgeon by a Neurologist because of her progressive gait ataxia.

Neurological examination showed intact cranial nerves and no motor deficit, but we found impairment in pain sensory and light touch in both legs that was prominent on the right side of the body, hyperreflexia in the left knee, ankle jerk, and mild gait ataxia based on tandem and blind walking. Blood tests and urinalysis were normal. Physical examination revealed a short neck, a low occipital hairline and diminished cervical range of motion. The patient also had an elevated left scapula and a bony prominence extending from the shoulder to the neck. The range of motion of

Address for correspondence: Dr. Seyyed Ahmad Mirhosseini, Department of Neurosurgery, Isfahan University of Medical Sciences, Isfahan, Iran.
 E-mail: drmirhosseini@yahoo.com

Received: 28-10-2012; **Revised:** 28-04-2013; **Accepted:** 02-05-2013

the neck and left shoulder was restricted. Anteroposterior and lateral radiographs revealed fused vertebral body of C5-C6 without spina bifida [Figures 1, 2a and b].

Radiographs in flexion and extension position demonstrated neither vertebral instability nor narrowing of the retrodental distance in ante- and retroflexion. Plain thoracic and lumbar radiographs showed scoliosis with no other spinal anomalies. Subsequent Magnetic Resonance (MR) and computed tomography imaging with three dimensional reconstructions of the neck and shoulder revealed an atypical bone configuration of the left shoulder with elevation and dysplasia of the scapula and an aberrant bony structure extending from the superomedial border of the scapula to the C5 transverse process leading to constriction of the spinal canal [Figures 1-3]. These findings were interpreted as omovertebral bone with associated unilateral SD and KFS. Resection of the omovertebral bone and decompression of the spinal canal were indicated with respect to patient's clinical myelopathy.

A curved incision was performed over the omovertebral bone from its cervical origin to its scapular termination. The intraspinal localized aberrant bony fragment, which we considered responsible for the neurological syndrome, was removed from the cleft in the posterior arch of C5, a laminectomy was performed at that level, and the omovertebral bone was partially resected.

In terms of gait ataxia the patient was neurologically unchanged, but she experienced a significant reduction in her neck pain, improved range motion of the neck, and the cosmetic result was good immediately after the operation. She recovered well from the procedure and was discharged from the hospital 3 days post-operatively. Follow-up radiographs demonstrated no further bony compression. There was no evidence of new instability resulting from the operative procedure occurred.

DISCUSSION

Maurice Klippel and Andre Feil explained a syndrome separately that is defined by a clinical triad include short neck, restricted range of motion in the neck and low posterior hairline. This syndrome is known as KFS. After that time, some patients with this syndrome found extra anomalies that can be accompanying to KFS. About 50% of patients who are suffered from it have that triad. Causes of KFS return to embryonic period when cervical vertebra is forming. Some authors introduced error in segmentation as a reason for KFS. The prevalence of KFS has been reported about 1 of 40,000 or 1 of 42,000 persons and most of them are female.^[10] Present case was a woman who had mentioned triad.

According to the level of vertebral fusion, some studies classified it into three groups: (1) Many vertebrae in cervical and thoracic zone are fused to each other, (2) Fusion is seen in one or two vertebra like a fusion between C2-C3 or C5-C6, and (3) vertebrae are associated with each other in cervical and thoracic or lumbar zone accompany with other anomalies.^[11] Our patient had fusion between C5-C6 with an elevated left scapula and a bony prominence extending from the shoulder to the neck.

Torticollis and loss of symmetrical expression of the face has been reported in 10% and 11.5% of cases with KFS respectively.^[12] However in about our case, there is no torticollis.

Our patient that was a rare presentation in that age had multiple anomalies including SD, omovertebral bone, and scoliosis.

As it is mentioned, symptoms and signs that point to KFS are various and it can present as cosmetic problems or severe problem such as predisposing to severe neurologic damage. Thus, sometimes it is introduced as an emergent situation and if you misdiagnose it, it will remain serious neurologic sequel.^[13]

SD is another anomaly that is seen in 7-42% of cases with KFS. Elevation of scapula is the most prominent feature of

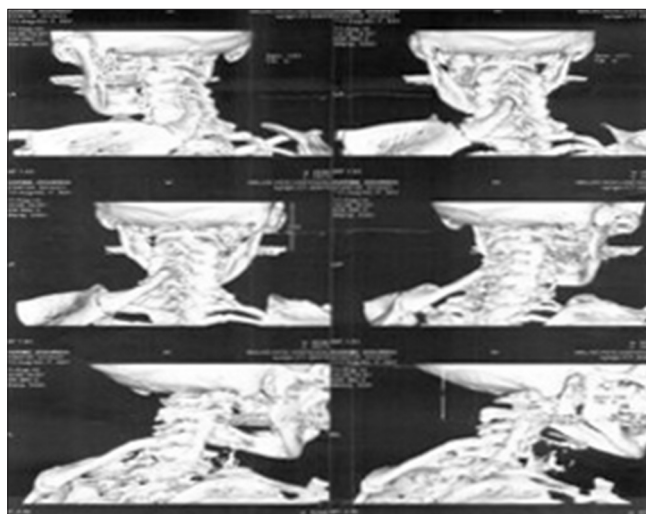


Figure 1: Multislice computed tomography, three dimensional

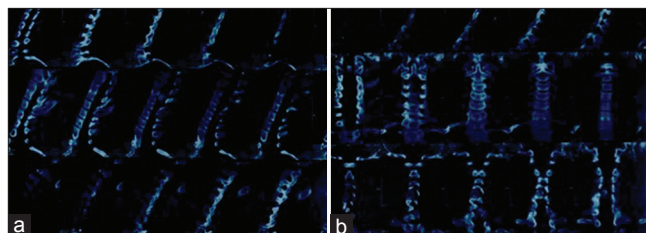


Figure 2: (a) Computed tomography (b) oblique view CT posteroanterior view

it. This anomaly results in cosmetic deformity and muscular dysfunction of upper limb. Muscular dysfunction resulted from some common defects in the trapezius, rhomboids and levator scapulae and some uncommon defects in muscles such as the pectoralis major/minor, latissimus dorsi, sternocleidomastoid, and serratus anterior. Differentiation of scapula occurs in 5th week of gestation.^[14] This process is started at levels of 4-6 cervical spines and then it descends to normal location opposite to second to seventh vertebra of thoracic. Events that happen in that time can cause SD. Omovertebral bone is seen in 25-35% (even 50% in some studies) of patients who are suffered from SD.^[15] In fact, it is a cartilaginous or bony and or fibrous tissue with a firm covers that fuse the scapula and processes of cervical spines.^[16] Conservative treatment is not acceptable in SD and surgery usually is useful for removing deformity.^[2] However, when physicians make a diagnosis and plan treatment, they should search the features of KFS and SD.

CONCLUSION

The case of a unilateral SD and KFS as an etiology for cervical myelopathy is unique in the adults. Risk for brachial plexus injury because of compression or stretching by the clavicle accelerate with age. Therefore, the surgical approach of adults' patients with SD can intend suitable surgical conclusions.

REFERENCES

- Hensinger RN, Lang JE, MacEwen GD. Klippel-Feil syndrome; a constellation of associated anomalies. *J Bone Joint Surg Am* 1974;56:1246-53.
- Doita M, Iio H, Mizuno K. Surgical management of Sprengel's deformity in adults. A report of two cases. *Clin Orthop Relat Res* 2000;371:119-24.
- Engel D: The etiology of the undescended. Boon JM, Potgieter D, Van Jaarsveld Z, Frantzen DJ. Congenital undescended scapula (Sprengel deformity): A case study. *Clin Anat* 2002;15:139-42.
- Boon JM, Potgieter D, Van Jaarsveld Z, Frantzen DJ. Congenital undescended scapula (Sprengel deformity): A case study. *Clin Anat* 2002;15:139-42.
- Ogden JA, Conlogue GJ, Phillips MS, Bronson ML. Sprengel's deformity. Radiology of the pathologic deformation. *Skeletal Radiol* 1979;4:204-11.
- Samartzis DD, Herman J, Lubicky JP, Shen FH. Classification of congenitally fused cervical patterns in Klippel-Feil patients: Epidemiology and role in the development of cervical spine-related symptoms. *Spine (Phila Pa 1976)* 2006;31:E798-804.
- Goffin J, Casey A, Kehr P, Liebig K, Lind B, Logroscino C, *et al.* Preliminary clinical experience with the Bryan Cervical Disc Prosthesis. *Neurosurgery* 2002;51:840-5.
- Füllbier L, Tanner P, Henkes H, Hopf NJ. Omovertebral bone associated with Sprengel deformity and Klippel-Feil syndrome leading to cervical myelopathy. *J Neurosurg Spine* 2010;13: 224-8.
- Vaidyanathan S, Hughes PL, Soni BM, Singh G, Sett P. Klippel-Feil syndrome-the risk of cervical spinal cord injury: A case report. *BMC Fam Pract* 2002;3:6.
- Tracy MR, Dormans JP, Kusumi K. Klippel-Feil syndrome: Clinical features and current understanding of etiology. *Clin Orthop Relat Res* 2004;424:183-90.
- Abbas J, Nazzal M, Serrano P, Elmer L. Aortic arch abnormality in a patient with Klippel-Feil syndrome. *Vascular* 2006;14:43-6.
- Smith BA, Griffin C. Klippel-Feil syndrome. *Ann Emerg Med* 1992;21:876-9.
- McBride WZ. Klippel-Feil syndrome. *Am Fam Physician* 1992;45:633-5.
- Grogan DP, Stanley EA, Bobechko WP. The congenital undescended scapula. Surgical correction by the woodward procedure. *J Bone Joint Surg Br* 1983;65:598-605.
- Aydinli U, Ozturk C, Akesen B, Ozer O. Surgical treatment of sprengel's deformity: A modified Green procedure. *Acta Orthop Belg* 2005;71:264-8.
- Hamner DL, Hall JE. Sprengel's deformity associated with multidirectional shoulder instability. *J Pediatr Orthop* 1995;15:641-3.

Source of Support: Nil, **Conflict of Interest:** None declared.