

# Laparoscopic phrenectomy for a diaphragmatic neurilemmoma

Kun Liu, Minghui Zhang<sup>1</sup>, Xiao Liang<sup>2</sup>, Xiujun Cai<sup>2</sup>

Departments of Hepatobiliary Surgery and <sup>1</sup>Ultrasound, Qingdao Municipal Hospital, Ocean University of China, Qingdao 266071, <sup>2</sup>Department of General Surgery, Sir Run Run Shaw Hospital, School of Medicine, Zhejiang University, Hangzhou 310016, China

Diaphragmatic neurilemmoma (schwannoma) is an extremely rare tumor that is often discovered incidentally. Even when diagnosed, patients are commonly advised only to attend regular follow-up appointments as conventional tumorectomy is enormously invasive and confers relatively few benefits. Here, we report a unique case of a diaphragmatic neurilemmoma with concomitant symptomatic cholecystolithiasis, who was treated successfully by pure laparoscopy. The entire operation lasted 65 min, and patient was discharged uneventfully on the 3<sup>rd</sup> post-operative day. The follow-up for 29 months has shown with no recurrence or symptoms.

**Key words:** Diaphragmatic neurilemmoma, diaphragmatic tumor, laparoscopy

**How to cite this article:** Liu K, Zhang M, Liang X, Cai X. Laparoscopic phrenectomy for a diaphragmatic neurilemmoma. J Res Med Sci 2013;18:522-5.

## INTRODUCTION

Primary neurilemmoma (schwannoma) of the diaphragm is an extremely rare tumor.<sup>[1,2]</sup> It is almost always benign and asymptomatic; thus, most neurilemmomas are found incidentally. Moreover, even after a neurilemmoma is diagnosed, patients are commonly advised only to attend regular follow-up appointments as the conventional tumorectomy is enormously invasive and offers relatively few benefits.<sup>[2]</sup> With increasing knowledge of minimally invasive surgery, laparoscopic phrenectomy with diaphragmatic repair has been proven to be safe and effective in the hands of skillful surgeons.<sup>[3-5]</sup> In this context, we report a unique case of a diaphragmatic neurilemmoma with concomitant symptomatic cholecystolithiasis that was successfully treated using a purely laparoscopic approach.

## CASE REPORT

A 46-year-old man was referred to Sir Run Run Shaw Hospital (Hangzhou, China) in April 2009 with a perihepatic mass found during a medical checkup requiring further investigation. A plain chest X-ray revealed a local right diaphragmatic eventration [Figure 1d]; abdominal ultrasonography demonstrated a 30 mm hypoechoic mass between the liver capsule and the diaphragm; a computed tomography [CT, Figure 1a-c] scan revealed a 30-32 mm tumor under the diaphragm; and enhanced magnetic resonance imaging [MRI, Figure 1e and f] suggested

a benign tumor, which was likely a diaphragmatic neurilemmoma at the same location. Simultaneously, a secondary diagnosis of asymptomatic cholecystolithiasis was confirmed. Given his absence of any discomfort and his inability to suspend his work, patient refused surgery and agreed to attend regular follow-up appointments instead.

Unfortunately, his gallstones became symptomatic during the 16<sup>th</sup> month of follow-up with two attacks of cholecystalgia per month, although these attacks were relieved using antibiotics and antispasmodics while under the care of community hospitals. We encountered the patient again in November 2010, and he consented to a simultaneous laparoscopic cholecystectomy and diaphragmatic tumorectomy. At the time of his admission, all of the regular laboratory tests were normal, including carcinoembryonic antigen,  $\alpha$ -fetoprotein, and neuron-specific enolase. The imaging findings were comparable to those 19 months earlier. In addition, the patient had a 4-year history of essential hypertension, which was satisfactorily controlled. Thus, he underwent laparoscopy under general anesthesia on November 9, 2010.

Patient was placed in the prone position and four trocars were employed in accordance with our previous report:<sup>[6]</sup> An umbilical trocar of 10 mm for the camera, a sub-xiphoid trocar of 12 mm as the main port, and two 5 mm trocars at the right midclavicular line for the assistant. A thorough exploration was undertaken,

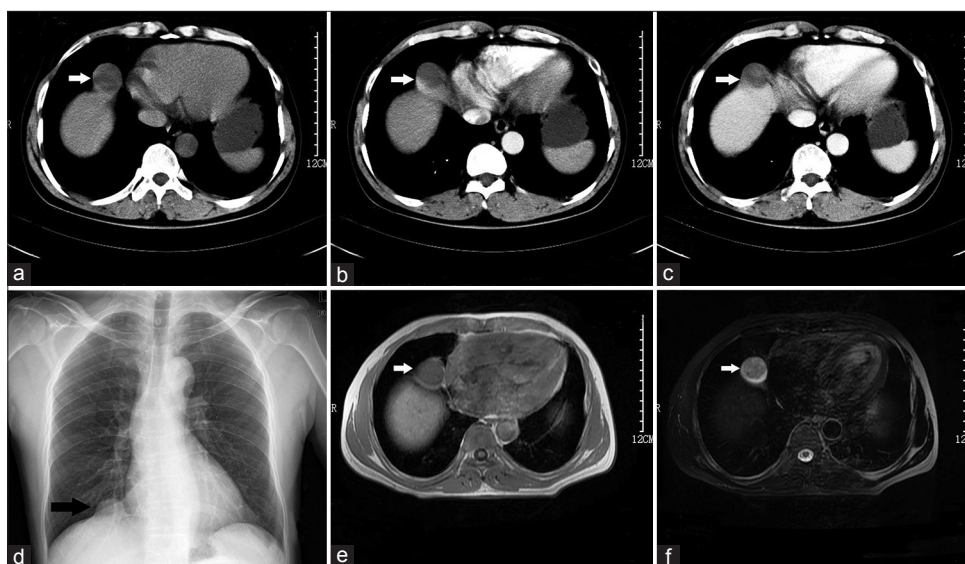
**Address for correspondence:** Dr. Xiao Liang, Department of General Surgery, Sir Run Run Shaw Hospital, School of Medicine, Zhejiang University, No. 3, East Qingchun Road, Hangzhou, 310016, P.R. China. E-mail: srrshlk@163.com

**Received:** 25-11-2012; **Revised:** 28-04-2013; **Accepted:** 02-05-2013

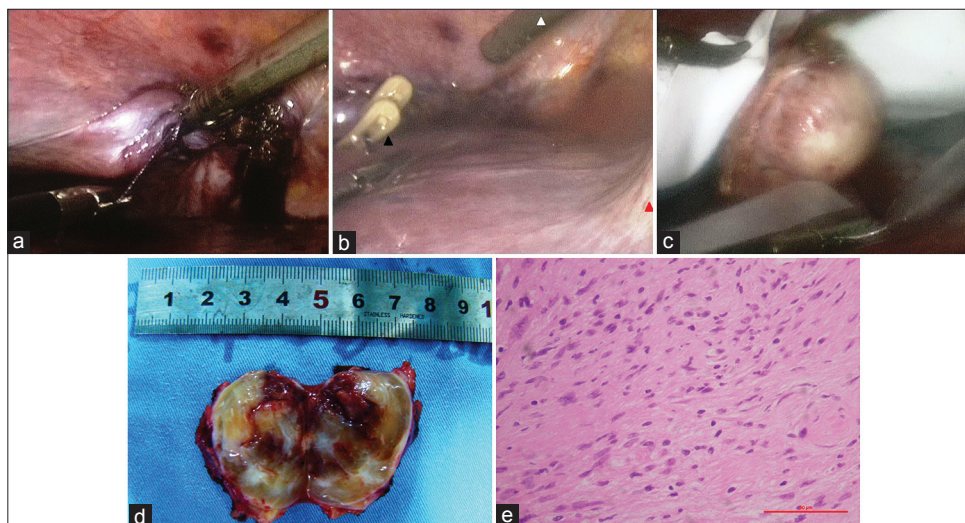
and a 3 cm mass underneath the right diaphragm was identified. At that time, an anti-Trendelenburg position was introduced, and the anesthesiologists turned down the tidal volume accordingly. While, the assistant fixed the diaphragm 2 cm away from the tumor, the surgeon performed a partial phrenectomy with our Laparoscopic Peng's Multifunctional Operative Dissector.<sup>[6]</sup> Afterward, the diaphragm was continuously sutured with 2-0 Vicryl sutures [Ethicon Inc.; Figure 2a]. The anesthesiologists were asked to manually expand the lungs using a breathing bag before the last suture was knotted in order to extrude the carbon dioxide from the thoracic cavity. Subsequently, the right subphrenic space was infused with water to perform

an air test in the Trendelenburg position to identify any remaining diaphragmatic defects [Figure 2b]; in addition, water was used to rule out an ongoing hemorrhage. Finally, a normal tidal volume and the anti-Trendelenburg position were resumed, and laparoscopic cholecystectomy was performed. The specimens were packed in a plastic bag and extracted via the 12 mm port [Figure 2c]. A gross section of the mass revealed a multilobulated, yellowish, solid tumor with cystic parts [Figure 2d], and the intraoperative frozen section pathological diagnosis was a diaphragmatic neurilemmoma.

The entire skin-to-skin time was 65 min, and the artificial



**Figure 1:** (a) Computed tomography (CT) plain scan, (b) CT arterial phase, and (c) CT venous phase revealed an approximately 3 cm, delayed-enhanced, encapsulated tumor in the right subphrenic area (arrow), (d) Chest X-ray showed a local diaphragmatic eventration (arrow), (e) T1-weighted magnetic resonance imaging, the mass exhibited a high signal intensity (arrow), (f) the T2-weighted intensity was not well-distributed with multiple degenerative areas and unevenly intensified on the enhanced scan (arrow)



**Figure 2:** (a) The tumor had been resected, a continuous suture of the diaphragm was done by laparoscopic approach, (b) two absorbable lapro-clips (Covidien Inc.) were applied to reinforce the suture (black arrowhead). The leak tightness was examined while the anesthetist expanded the lungs (white arrowhead: Laparoscopic Peng's Multifunctional Operative Dissector; red arrowhead: Falciform ligament), (c) the specimen was packed into a plastic bag, (d) macroscopic examination through a cut section, (e) microscopic examination (H and E, stain) of the tumor

pneumothorax lasted 21 min. The intraoperative blood loss was less than 50 ml. No intraoperative blood transfusions or thoracic/abdominal drainage was needed. The intraoperative vital signs were stable, and no tension pneumothorax occurred. Post-operatively, the patient initiated oral intake and bedside activities 6 h later. No analgesics were used, and no complications occurred. He was discharged on the 3<sup>rd</sup> post-operative day, and the final pathology results confirmed the diagnosis of a diaphragmatic neurilemmoma by immunohistochemistry [Figure 2e]. Patient has been observed for more than 2 years with no recurrence or symptoms.

## DISCUSSION

Diaphragmatic neurilemmomas (schwannomas and neurinomas) are extremely rare and represent approximately 3% of all diaphragmatic neoplasms; thus, only a few experiences have been accumulated.<sup>[7]</sup> In English-language medical literature from PubMed, Scopus, Web of Science, Global Health, BIOSIS, EBSCO, and Cochrane Central by April 2013, only 10 cases of diaphragmatic neurilemmomas have been reported; of these cases, 6, and 4 were managed by open thoracotomy and laparotomy, respectively [Table 1].<sup>[7-16]</sup> The present case is the first to be managed using a purely laparoscopic approach.

Diaphragmatic neurilemmomas occur most frequently in people between 29 years and 53 years of age (95% confidence interval in these 11 patients, with a mean age of 41 years). Women seem to be more susceptible than men (8/3, sex ratio 2.67), and there is a similar incidence on both sides of the diaphragm (6/5). Most patients are diagnosed incidentally with no special symptoms or signs, although chest pain, coughing, and dyspnea are the most commonly encountered symptoms when a large tumor is located in the thoracic cavity or chest wall. The diagnosis thus depends largely on imaging examinations. An X-ray may show a diaphragmatic eventration or a solitary mass.

Ultrasonography is helpful for locating the tumor when it is in the abdominal cavity as in our case. CT and MRI scans can reveal tumor details, including the intra-structure of the tumor and its peripheral relationship with surrounding structures.<sup>[17]</sup> Ultimately, a percutaneous biopsy is optional and limited to accessible lesions in a minority (2/11) of patients whose tumors were located in the peripheral region of the diaphragmatic dome.<sup>[7,8]</sup> Today, the creation of an artificial pneumothorax or pneumoperitoneum has already been abandoned for the purpose of pre-operative differential diagnosis.

Diaphragmatic neurilemmomas are benign, slow-growing nerve sheath tumors that derive from the Schwann cells of the terminal branches of the bilateral phrenic nerves. These tumors are encapsulated and do not invade adjacent structures; thus, it is almost always asymptomatic. Some surgeons recommend an elective resection once a neurilemmoma is diagnosed as it is not easy to distinguish absolutely between benign and malignant tumors prior to surgery; however, more physicians prefer the more conservative observation, except when there is a sudden increase in the size of the tumor or if patient has neurofibromatosis, which is a condition that increases the suspicion of malignant changes.<sup>[9]</sup> Traditionally, resection is performed through a standard posterolateral thoracotomy (6/10) or laparotomy (4/10), both of which require large incisions, leading to severe post-operative pain. In the new era of minimally invasive surgery, laparoscopy provides a safe, efficient, and cosmetic approach with rapid recovery for diaphragmatic lesions.<sup>[4]</sup> Surgeons can already perform a partial phrenectomy and repair the diaphragm using sutures or autologous or artificial materials, and the approach can be laparoscopic or even robotic, depending on the size of the diaphragmatic defect.<sup>[3,18]</sup> Moreover, laparoscopic transdiaphragmatic resection of mediastinal tumors and retroperitoneal transdiaphragmatic robotic-assisted resection of thoracolumbar neurofibromas are also feasible.<sup>[5,19]</sup>

**Table 1: Case reports of diaphragmatic neurilemmoma in the English literature**

First author (published year) <sup>Ref</sup>	Ages at resection	Sex	Location	Size (cm)	Symptoms	Observation	Operative approach
Weisel (1956) <sup>[10]</sup>	55	F	Left	23*18	Pain, cough, dyspnea	1 year, enlarging	Thoracotomy
Trivedi (1958) <sup>[11]</sup>	5	F	Left	7.5	Clubbing	None	Thoracotomy
Sarot (1969) <sup>[12]</sup>	65	M	Left	9*7	No	12 years, enlarging	Thoracotomy
McHenry (1988) <sup>[13]</sup>	45	F	Left	3.5	No	None	Laparotomy
McClenathan (1989) <sup>[7]</sup>	46	F	Right	10	No	5 years, enlarging	Thoracotomy
Koyama (1996) <sup>[8]</sup>	38	F	Left	5.1*3.2	No	None	Laparotomy
Ikegami (2004) <sup>[14]</sup>	47	M	Right	5	No	13 years, enlarging	Laparotomy
Ohba (2008) <sup>[9]</sup>	50	F	Right	10.4*7.8	No	None	Thoracotomy
Chang (2012) <sup>[15]</sup>	38	F	Left	14*10	Pain, dyspnea	None	Thoracotomy
Hobbs (2012) <sup>[16]</sup>	13	F	Right	12*10	Pain	None	Laparotomy
Present case	47	M	Right	3.2*3	No	19 months, stable	Laparoscopy

Herein, we performed a laparoscopic phrenectomy with cholecystectomy to treat a diaphragmatic neurilemmoma and asymptomatic cholecystolithiasis at the same time. In our case, the diaphragmatic defect after tumor excision was less than 5 cm; thus, it could be repaired with simple sutures. Tension pneumothorax is an indication for conversion to laparotomy; luckily, it is uncommon and usually occurs with large diaphragmatic defects or with prolonged durations of high-pressure pneumoperitoneum.<sup>[20]</sup> In this case, it took only 21 min to cut and repair the diaphragm, and a relatively low-pressure pneumoperitoneum (12 mmHg) was introduced. Collectively, a smooth recovery was achieved.

## CONCLUSION

A unique case of the rare diaphragmatic neurilemmoma cured by laparoscopy is reported. Laparoscopic surgery is less invasive and offers a faster recovery in contrast to open thoracotomy or laparotomy; thus, it can be an option for diaphragmatic tumors in select patients and skillful hands.

## REFERENCES

1. Marchevsky AM. Mediastinal tumors of peripheral nervous system origin. *Semin Diagn Pathol* 1999;16:65-78.
2. Kim MP, Hofstetter WL. Tumors of the diaphragm. *Thorac Surg Clin* 2009;19:521-9.
3. Ino H, Naitou M, Hato S, Tomiyama K, Mandai Y, Hayashi T, *et al.* A rare primary diaphragmatic hemangioma successfully treated by laparoscopic surgery: Report of a case. *Surg Today* 2010;40:654-7.
4. Palanivelu C, Rangarajan M, Rajapandian S, Amar V, Parthasarathi R. Laparoscopic repair of adult diaphragmatic hernias and eventration with primary sutured closure and prosthetic reinforcement: A retrospective study. *Surg Endosc* 2009;23:978-85.
5. Tanaka K, Hara I, Yamaguchi K, Takeda M, Takenaka A, Fujisawa M. Laparoscopic resection of a lower posterior mediastinal tumor: Feasibility of using a transdiaphragmatic approach. *Urology* 2007;70:1215-8.
6. Cai XJ, Yang J, Yu H, Liang X, Wang YF, Zhu ZY, *et al.* Clinical study of laparoscopic versus open hepatectomy for malignant liver tumors. *Surg Endosc* 2008;22:2350-6.
7. McClenathan JH, Okada F. Primary neurilemmoma of the diaphragm. *Ann Thorac Surg* 1989;48:126-8.
8. Koyama S, Araki M, Suzuki K, Fukutomi H, Maruyama T, Mun Y, *et al.* Primary diaphragmatic schwannoma with a typical target appearance: Correlation of CT and MR imagings and histologic findings. *J Gastroenterol* 1996;31:268-72.
9. Ohba T, Shoji F, Kometani T, Yoshino I, Maehara Y. Schwannoma in the peridiaphragm. *Gen Thorac Cardiovasc Surg* 2008;56:453-5.
10. Weisel W, Claudon DB, Willson DM. Neurilemmoma of the diaphragm. *J Thorac Surg* 1956;31:750-7.
11. Trivedi SA. Neurilemmoma of the diaphragm causing severe hypertrophic pulmonary osteoarthropathy. *Br J Tuberc Dis Chest* 1958;52:214-7.
12. Sarot IA, Schwimmer D, Schechter DC. Primary neurilemmoma of diaphragm. *N Y State J Med* 1969;69:837-40.
13. McHenry CR, Pickleman J, Winters G, Flisak ME. Diaphragmatic neurilemmoma. *J Surg Oncol* 1988;37:198-200.
14. Ikegami T, Ezaki T, Ishida T, Kohno H, Fujihara M, Mori M. Neurilemmoma of the diaphragm mimicking a liver tumor: Case report. *Abdom Imaging* 2004;29:85-6.
15. Chang CY, Chang YC, Chang SC, Chen YC. A huge diaphragmatic schwannoma mimicking diaphragm palsy. *QJM* 2012;105:701-3.
16. Hobbs DJ, McLellan J, Schlatter MG. Schwannoma of the diaphragm: A pediatric case report and review of the literature. *J Pediatr Surg* 2012;47:e5-7.
17. Wasa J, Nishida Y, Tsukushi S, Shido Y, Sugiura H, Nakashima H, *et al.* MRI features in the differentiation of malignant peripheral nerve sheath tumors and neurofibromas. *AJR Am J Roentgenol* 2010;194:1568-74.
18. Zügel NP, Kox M, Lang RA, Hüttl TP. Laparoscopic resection of an intradiaphragmatic bronchogenic cyst. *JSLS* 2008;12:318-20.
19. Moskowitz RM, Young JL, Box GN, Paré LS, Clayman RV. Retroperitoneal transdiaphragmatic robotic-assisted laparoscopic resection of a left thoracolumbar neurofibroma. *JSLS* 2009;13:64-8.
20. Sternberg DM, Petrick AT, Gharagozloo F, Hannallah MS. Tension pneumothorax precluding laparoscopic repair of diaphragmatic hernia. *Surg Laparosc Endosc* 1997;7:429-31.

Source of Support: Nil, Conflict of Interest: None declared.