

Severe gastrointestinal burn with hydrochloric acid

Coşkun Araz, Nedim Çekmen, Özcan Erdemli, Lutfu Soylu¹, Fuat Atalay¹, Tefik Ali Demirbaş², Ali Demirbaş², Bahadır Celep²

Intensive Care Unit, Ankara Guven Hospital, ¹Department of Gastrointestinal Surgery, Ankara Guven Hospital, ²Department of Gastrointestinal Surgery, Ankara Yuksek Ihtisas Hospital, Ankara, Turkey

Inadvertantly or purposely, an oral intake of corrosive substances may cause life-threatening problems. Early admission to the hospital, clinical and endoscopic evaluation, and early surgery when required, may reduce morbidity and mortality. We report the case of a 49-year-old male patient, who had attempted suicide, by drinking about 800 mL of 25% hydrochloric acid, and who had severe intra-abdominal damage. The aim of this report is to state the fact that a good outcome is possible in severe burns caused by oral intake of corrosive substances, when fast, multidisciplinary, and appropriate management is provided on time.

Key words: Corrosive ingestion, hydrochloric acid, intensive care unit

INTRODUCTION

Corrosive chemicals are used for many purposes in daily life, like cleaning agents, cosmetics, substances used for house, car, and upkeep of the garden. Oral intake of these substances either by accident, or sometimes purposely, may cause life-threatening problems. Inadvertant drinking of corrosive substances usually occurs in a group of patients at the pediatric age. Their voluntarily intake is mostly for suicide in adults. The spectrum of gastric injury due to corrosives can vary. Recent data suggest that more than 200,000 exposures to household or industrial cleaning products occur annually in the United States and corrosive esophageal burns affect for about 5000 – 15000 people in the USA every year.^[1] It is difficult to determine what fraction of these exposures represent caustic ingestion. Although there are no epidemiological studies reported from our country, clinical experiences show that this rate is probably higher in Turkey.

Ingested corrosive agents can produce oropharyngeal and gastrointestinal damages ranging from minor burns to full-thickness injuries, with severe necrosis,

depending on the amount and concentration of the agent and duration of exposure.^[2-4] Systemic symptoms due to gastrointestinal absorption of corrosive substances and sudden death in the following period is not very common. The most important reason of sudden death is the laryngeal burn, edema, and inflammation caused by chemical substances, and the resulting acute respiratory obstruction.^[4-6] However, in corrosive esophagitis patients, mortality is rather due to severe chemical burn in the thoracic and abdominal regions, presenting with the interruption of the integrity of the gastrointestinal tract, with necrosis, perforation, hemorrhages, and infections.^[7] The interventions made in the acute phase and the care given in the following period carry high mortality and morbidity risks and mandate a multidisciplinary approach and a close follow-up. The aim of this report is to state the fact that good outcomes are possible in severe burns caused by the oral intake of corrosive substances when fast, multidisciplinary, and appropriate management is provided on time. We report a case of massive hemorrhagic necrosis of the gastrointestinal organs, including the lower esophagus, stomach, small bowel, and pancreas, secondary to caustic ingestion of hydrochloric acid.

CASE REPORT

Herewith, we report the case of a 49-year-old male patient who had attempted suicide by drinking about 800 mL of 25% hydrochloric acid, and was in the Ankara Güven Hospital, Ankara, Turkey, in 2009. The patient was admitted to the Emergency Department within 30 minutes of ingestion of the corrosive liquid, with severe

Access this article online	
Quick Response Code:	Website: www.journals.mui.ac.ir/jrms
	DOI: ***

Address for correspondence: Dr. Nedim Çekmen, İlko evleri 2796.sok No:12 Çayyolu Mah, Yenimahalle, Ankara, Turkey

Email: nedimcekmen@yahoo.com

Received: 22-02-2012; Revised: 03-05-2012; Accepted: 30-05-2012

abdominal pain, agitation, and respiratory discomfort. Due to subsequent psychological problems, he had attempted to commit suicide. The patient, with a history of no previous systemic disorder, was evaluated by Gastroenterology, General Surgery, and Emergency Department practitioners, as also the Intensive Care Unit (ICU) team. On admission to the ICU, his consciousness was delirious in nature and he was confused. His blood pressure was 130/90 mmHg, heart rate 115/minute, oxygen saturation (SpO₂) 90%, and respiratory rate 25 per minute. In the physical examination of the respiratory system, wheezing and prolonged expiration existed, together with fine rales. There were increased abdominal irritability and peritoneal irritation signs, but no pathological findings in the thoracoabdominal tomographic examination. There were ulcerative lesions, and bloody and dirty material in his mouth. His initial leucocyte count was 20.600 cell/uL, creatinine 1,68 mg/dL, aspartate aminotransferase 455 U/L, alanine aminotransferase 175 U/L, lactate dehydrogenase 701 U/L, gamma-glutamyl transferase 110 U/L, sodium 152.1 mEq/L, potassium 3.21 mEq/L, pH 7.29, pO₂ 71 mmHg, pCO₂ 43 mmHg, HCO₃⁻ 17.4 mmol/L, and SpO₂ 89%. Intravenous hydration, meperidine, antibiotics, nonsteroidal anti-inflammatory agents, methylprednisolone, and proton pump inhibitors were given for his symptoms. After admission to the Emergency Department, the patient was moved to the ICU and sedated with opioids and benzodiazepines, because of his agitative state. With nasal oxygen delivery his SpO₂ was 98%. Nine hours after ingestion, due to gradually increasing metabolic acidosis and respiratory deterioration, the patient was intubated and connected to the mechanical ventilator. Arterial, central venous, and urinary catheterization were performed. His Acute Physiology and Chronic Health Evaluation II (APACHE II) score was 27 and estimated mortality rate was 61%. At the forty-eighth hour, because of extensive abdominal pain and serious respiratory discomfort, the thoracoabdominal computerized tomography (CT) was repeated [Figure 1]. An urgent surgical intervention was made because free abdominal fluid was detected on CT. During the operation, six liters of intra-abdominal fluid with infected material was aspirated. Total gastrectomy, duodenal resection, partial jejunectomy, and partial pancreatectomy were performed. Due to splenic hemorrhage, splenectomy was also applied [Figures 2-4 show pictures of the resected material]. Histopathological analysis of the surgical material revealed stage IIIb necrosis, which was also called 'black necrosis'. Hemogram and electrolyte levels were closely followed up during the perioperative period. The blood components were given and fluid replacements were administered when needed.

The patient was extubated eight days after the operation, without deterioration of oxygenation. However, he had abdominal infections and / or serious metabolic problems

in common, such as, lactic acidosis or low serum sodium bicarbonate levels, due to abdominal low perfusion and adrenal insufficiency. After surgery, antibiotherapy, parenteral nutrition, and palliative care were applied to the patient for 140 days, 105 of which passed in the ICU. Nine complementary or intra-abdominal debridement and clean-up surgeries were performed during this period. Oral nutrition was started on the one hundred and twenty-fifth day of hospitalization. Parenteral nutrition was gradually stopped and he was discharged with recommendations for Psychiatry, Gastroenterology, General Surgery, and Physical Therapy Departments on the one hundred and fortieth day. After six months, he came for a follow-up without any further complication.

DISCUSSION

The pediatric group under age five constitute 75% of all corrosive burn cases. However, compared with the ingestion of corrosive substances in children, this problem tends to be more serious in adults, because its intent is often suicidal, rather than accidental.^[3] Mortality rates are generally reported to be 10 – 20%, but they can be as high as 78%, if the intake is purposely for suicide.^[7]

The degree and extent of damage depends on several factors like the type of substance, the morphological form of the agent, the quantity, and the intent,^[3,4,8,9] as well as the burn itself. Secondary infections also increase the morbidity and mortality. These infectious situations may include; stomatitis, gingivitis, mediastinitis, peritonitis, pneumonia, and the like. Infections may develop secondary to perforation or surgery, because of impairment of epithelization and wound healing. Severe mediastinitis and mediastinal abscess formation is reported in 1% of esophageal perforation cases.^[10,11] In our case, intra-abdominal infections had been one of the most important factors affecting the progression of the disease. He had undergone surgical interventions many times because of infections and had to receive long-term, wide-spectrum, antibiotherapy. As a result of utmost intensive care, intrathoracic or respiratory system infections did not occur in our patient, which frequently coexist and diminish morbidity and mortality in ICU patients, as well as, corrosive burn patients.

Caustic and corrosive injury of the upper gastrointestinal tract can lead to significant morbidity and mortality, with the development of upper gastrointestinal stricture or perforation. Medical and surgical treatments are controversial and include steroids, antibiotics, esophageal dilation, stenting, and surgical reconstruction, and are centered around saving esophageal integrity and preventing esophageal strictures. Early diagnosis and prompt and aggressive treatment can

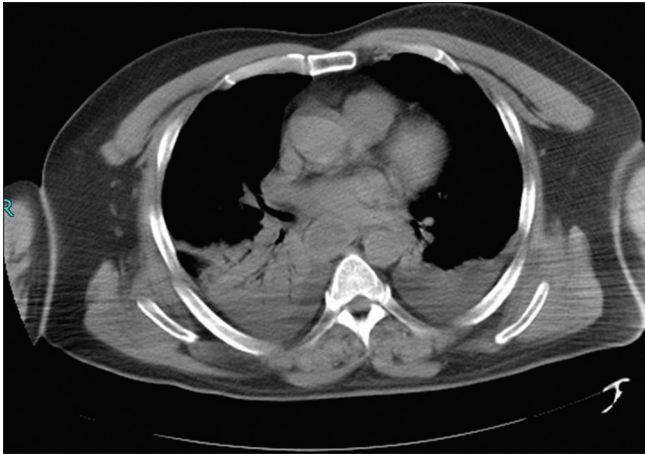


Figure 1: Computed tomography scan of the abdomen at admission

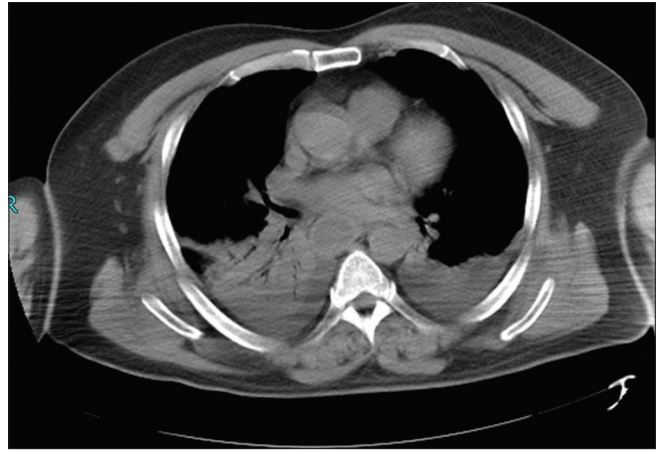


Figure 2: Intraoperative perspective for severe intestinal burn

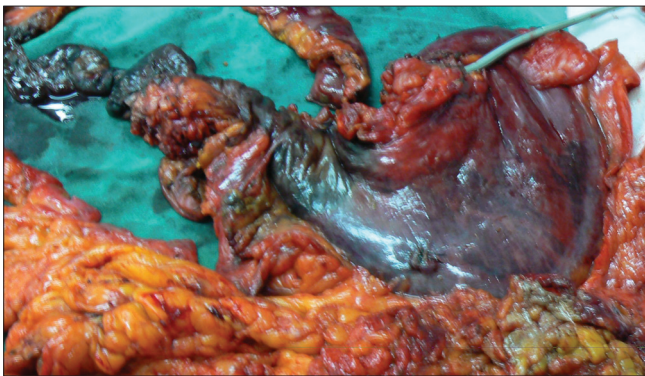


Figure 3: Totally resected material. Note the widespread of the burn

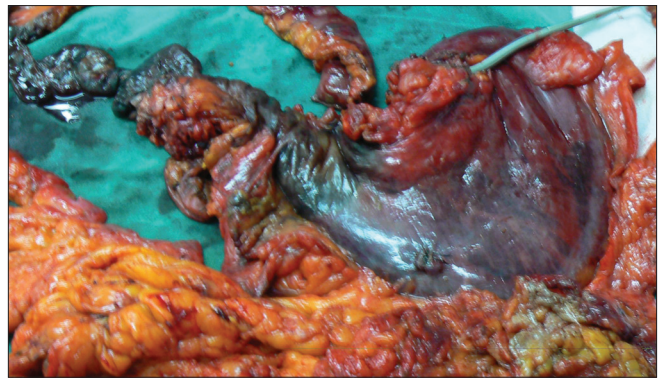


Figure 4: Black necrosis of the stomach

improve the long-term outcomes in these patients.^[12] In the acute stage, perforation and necrosis may occur. X-rays of the abdomen and chest should be done initially to detect any evidence of perforation. Endoscopy should be performed as soon as possible in all cases, to evaluate the extent and severity of damage, unless there was evidence of perforation.^[3] In this case we attempted an investigational endoscopy, but we could not complete the procedure, because the mucosa of esophagus looked pale and thin and there were widespread necrotic and hemorrhagic areas. Continuing the procedure might have led to esophageal perforation and further complicated the medical status.

In severe corrosive injuries of the upper respiratory tract, intubation and ventilation are mandatory. In some of these patients oral damage may not be serious. However, this does not reflect the severity of gastric or intestinal injury. On account of fast swallowing of the corrosive material, intraoral irritation may not occur, whereas, intestinal damage may be tremendous. Choosing the best time for airway instrumentation is crucial, if the decision of intervention is prolonged, due to edema and tissue necrosis, the airway may not be provided. We intubated our patient nine hours after admission. In this period close monitoring was carried out for oxygen saturation and the respiratory comfort of the

patient. When metabolic acidosis and respiratory discomfort developed, the patient was intubated immediately.

Metabolic acidosis, hemolysis or intravenous coagulopathy may occur after acid absorption.^[13] Careful management of the acid–base status, electrolytes, and blood counts are recommended. In our patient severe metabolic and respiratory acidosis developed rapidly. We intubated the patient and mechanical ventilation was applied. Electrolyte, sodium bicarbonate, fresh frozen plasma, or erythrocyte suspension replacements were given according to the laboratory values.

Long-term complications include stricture formation in the oesophagus, antral stenosis, and the development of esophageal carcinoma.^[9] This patient was redirected to the associated branches for nutrition, swallowing therapy, and follow-up, after discharge from the hospital.

CONCLUSION

Early intervention is important in oral corrosive substance intake cases. Endoscopic intervention should be made in the first 24 hours if possible. If hemorrhages, erosions, necrosis, and pale-atrophic mucosa is detected, a close clinical follow-up should be made for a possible perforation.

A multidisciplinary approach is crucial in a way that an adequate treatment can be administered, and short- and long-term complications can be avoided. This case report supports that even if the damage is very serious and proceeds to mortality, an aggressive multidisciplinary approach would help prevent complications and mortality rates may decrease in corrosive-intake patients.

REFERENCES

1. Kay M, Wyllie R. Caustic ingestions in children. *Curr Opin Pediatr* 2009;21:651-4.
2. Dogan Y, Erkan T, Cokugras FC, Kutlu T. Caustic gastroesophageal lesions in childhood: An analysis of 473 cases. *Clin Pediatr (Phila)* 2006;45:435-8.
3. Robustelli U, Bellotti R, Scardi F, Fortunato Armellino M, De Masi A, Forner AL, *et al.* Management of corrosive injuries of the upper gastrointestinal tract. Our experience in 58 patients. *G Chir* 2011;32:188-93.
4. Cabral C, Chirica M, de Chaisemartin C, Gornet JM, Munoz-Bongrand N, Halimi B, *et al.* Caustic injuries of the upper digestive tract: A population observational study. *Surg Endosc* 2012;26:214-21.
5. Franke DD, Davis EG, Woods DR, Johnson RK, Miller FB, Franklin GA, *et al.* Catastrophic gastrointestinal injury due to battery acid ingestion. *J Emerg Med* 2011;40:276-9.
6. Ananthkrishnan N, Parthasarathy G, Kate V. Acute corrosive injuries of the stomach: A single unit experience of thirty years. *ISRN Gastroenterol* 2011;2011:914013.
7. Ertekin C, Alimoglu O, Akyildiz H, Guloglu R, Taviloglu K. The results of caustic ingestions. *Hepatogastroenterology* 2004;51:1397-400.
8. Keh SM, Onyekwelu N, McManus K, McGuigan J. Corrosive injury to upper gastrointestinal tract: Still a major surgical dilemma. *World J Gastroenterol* 2006;12:5223-8.
9. Ramasamy K, Gumaste VV. Corrosive ingestion in adults. *J Clin Gastroenterol* 2003;37:119-24.
10. Chou SL, Chern CH, Chen JD, How CK, Wang LM, Lee CH. Descending necrotising mediastinitis: A report of misdiagnosis as thoracic aortic dissection. *Emerg Med J* 2005;22:227-8.
11. Marty-Ane CH, Alauzen M, Alric P, Serres-Cousine O, Mary H. Descending necrotizing mediastinitis. Advantage of mediastinal drainage with thoracotomy. *J Thorac Cardiovasc Surg* 1994;107:55-61.
12. Schaffer SB, Hebert AF. Caustic ingestion. *J La State Med Soc* 2000;152:590-6.
13. Boseniuk S, Rieger C. acute oral acetic acid poisoning--case report. *Anaesthesiol Reanim* 1994;19:80-2.

How to cite this article: Araz C, Çekmen N, Erdemli Ö, Soyulu L, Atalay F, Demirbaş TA, *et al.* Severe gastrointestinal burn with hydrochloric acid. *J Res Med Sci* 2013;18:449-52.

Source of Support: Nil, **Conflict of Interest:** None declared.