

Case Report

Anesthetic Management of Total Traumatic Avulsion of Mandible

M. Doroudian MD*

Abstract

A healthy 34 year old man was referred to the operating room for the repair of his totally avulsed lower jaw. He did not tolerate the supine position and always maintained a sitting position to keep his airway open. The patient was successfully managed with a special anesthetic technique to overcome his airway problem and to intubate him.

Keywords: Airway Obstruction, Mandibular Avulsion, Difficult Airway, Difficult Intubation

Mandible plays an important role in the patency of upper airway by supporting tongue and hyoid bone, the latter in turn supports epiglottis¹. Traumatic loss of mandible, though is very rare and has not been reported systematically can cause special airway problem, which is very important for the anesthesiologist.

Case History

A thirty-four year old male farmer was hit in the mandible by the rotating blade of a water pump system, which resulted in total avulsion of his mandible. He was referred to a University hospital in Kerman with the avulsed bone wrapped in a piece of cloth (Figure 1, A and B). Although he was bleeding in his crashed lower face with his tongue fully hanging over his chest (Figure 1, sections C), his general condition was excellent and he was able to fully communicate with others with writing. As shown in figure 1, A and B only a small fragment of left vertical ramus of the mandible remained in place. In the operation room it was decided to perform tracheostomy under local anesthesia before the induction of anesthesia. However, the patient could not tolerate the recumbent position. In spite of intravenous sedation with narcotics and midazolam, several attempts at holding him in supine position was counteracted vigorously by the patient and he always restored his sitting position with a slight forward bending. The patient pointed out (by writing of course) that he must retain this particular position to save him from suffocation. The patient did not tol-

erate lateral or even a mild semi sitting position. The decision to anesthetize the patient in the sitting position and then restoring supine position had the potential risk of difficulty in opening the airway together with the risk of failure to ventilate. In addition, it was not possible to fit an anesthesia face-mask around the airway opening. Finally, it was decided to anesthetize the patient in his favorite position after making an artificial support for the tongue as follows. After topical anesthesia of the base of the tongue dorsum as far posteriorly as possible, a transverse mattress suture was stitched using a large needle with a heavy gauge silk to ensure a substantial deep bite of tongue^{1,2}. A loose knot was placed near the dorsum of the tongue and the two ends were left sufficiently long to be led forward and secured outside the mouth. All necessary equipment for emergency cricothyrotomy and translaryngeal jet ventilation were made available. After establishment of standard monitoring (pulse oximetry, electrocardiography, blood pressure) and preoxygenation with a high flow rate of O₂ (O₂ flash) blowing the fresh gas right over the patient's face and obtaining pulse oxymetric saturation (SaO₂) of 99%, anesthesia was induced intravenously in sitting position with thiopental 250 mg followed immediately by succinylcholine 50 mg. Immediately after induction, the patient was placed in supine position to attempt laryngoscopy and intubation. Initial attempts at visualizing the glottis was unsuccessful,

*Assistant Professor, Department of Anesthesia, Kerman University of Medical Sciences Kerman, Iran.

Correspondence to: Dr. Mohammad R Doroudian, Department of Anesthesia, Kerman University of Medical Sciences, Kerman, Iran.

because the freely moving bulk of tongue prevented the laryngoscope blade to take a sustained placement over dorsum of the tongue. Therefore, the tongue was supported by pulling the ends of the silk tightly (Figure 2). In this way, laryngoscopy was performed easily and the patient was intubated orally through the fully exposed glottis with number eight (internal diameter, mm) tracheal tube. The tube was fixed to the upper incisors using steel wire. Anesthesia was maintained with a mixture of halothane and N₂O in oxygen using neuromuscular blockade and controlled ventilation. The surgical procedure consisted of fixing the avulsed bone, grafting some vasculature, and flap covering of the grafted area. The remaining anesthesia period was uneventful and the patient was extubated after full awakening in the recovery room.

Discussion

This patient presented with a unique airway problem, loss of lower jaw, with its accompanying anesthesia problems including failure to fit an anesthesia mask, hence difficulty in preoxygenation and controlled mask ventilation, difficulty in establishing a supine position due to the drop of unsupported tongue right over the postero-superior pharyngeal wall, and finally difficulty during placement of laryngoscope blade due to freely moving bulk of tongue. Therefore general anesthesia induction in these patients have the inherent risk of airway obstruction and the development of the so-called "failure to both ventilate and intubate" catastrophe. Although several cases of severe crush injury of the lower jaw have already been presented^{3, 4} but total avulsion of mandible has not been reported yet. Anesthetic management of these patients must be performed taking into account the underlying pathophysiology of the airway and the associated trauma. Avulsion of the lower jaw if is also accompanied by loss of hyoid bone may further complicate the obstructive nature of the upper airway because of dropping the unsup-

ported epiglottis over the glottic inlet. The patient may be awakely intubated with a blind technique or fiberoptically, although the bleeding upper airway may be a contradicting factor (as in this case). Blind insertion of an artificial airway (pharyngeal, laryngeal, tracheal, etc) may further increase the extent of injury in such cases. Laryngeal Mask Airway (LMA) also may not be useful in these clinical settings due to loss of supporting tissue of the tongue. Furthermore, expansion of laryngeal cuff of LMA may increase the extent of injury and makes the operative exposure difficult. Retrograding techniques through cricothyroid or cricotracheal membrane using an epidural catheter may be a good alternative whenever the anesthesiologist is familiar with the procedure.

In this patient, a pathophysiologically oriented approach was chosen, namely supporting the freely moving tongue with a tough mattress stitch at the base of the tongue, so that pulling the silk would straighten and tighten the tongue well enough for a laryngoscope blade to smoothly slipping over it and bringing the glottis in sight.

Administration of succinyl choline in these patients seems to be a matter of clinical judgment, however it must be used cautiously only if jet ventilation and cricothyrotomy sets are readily available to combat the nonintubation-nonventilation condition. In addition, full preoxygenation to a SaO₂ of 99-100% will provide an adequate time for laryngoscopy trials without considerable decrease in arterial O₂ saturation in a relatively healthy cardiorespiratory system. However cautious use of lower doses of succinyl choline seems to be safe in experienced hands. In this case, succinyl choline administered half of the ordinary dosage (i.e. 50 mg), therefore if the airway can not be secured in time, the patients relaxation would wear off and respiration will return.

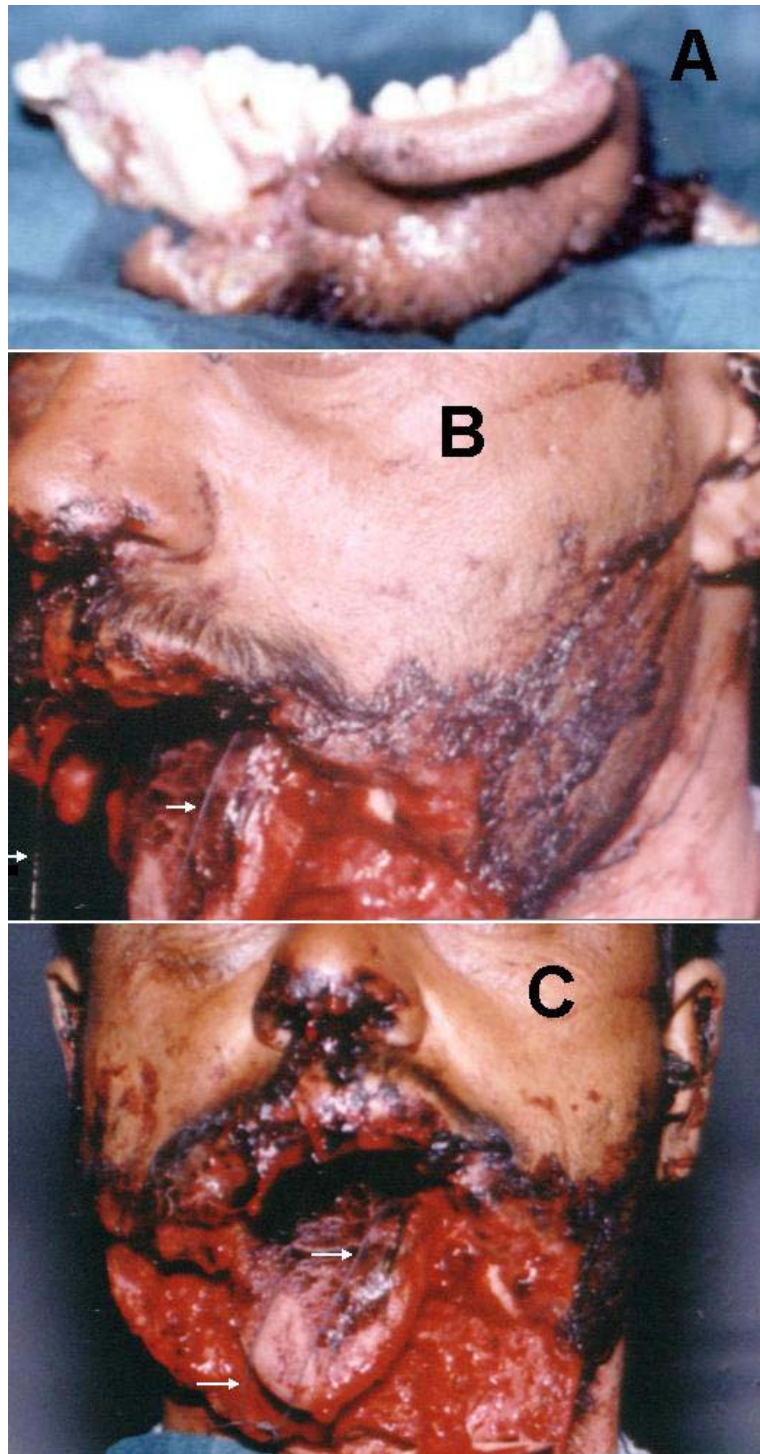


Figure 1. Patient's face and the avulsed mandible at different views before and during the operation.

A: The avulsed mandible after cleaning, B and C: Face from semilateral and anterior views respectively, showing the absence of lower jaw, hanging tongue, crashed soft tissue injury. White arrows in B showing the silk suture.

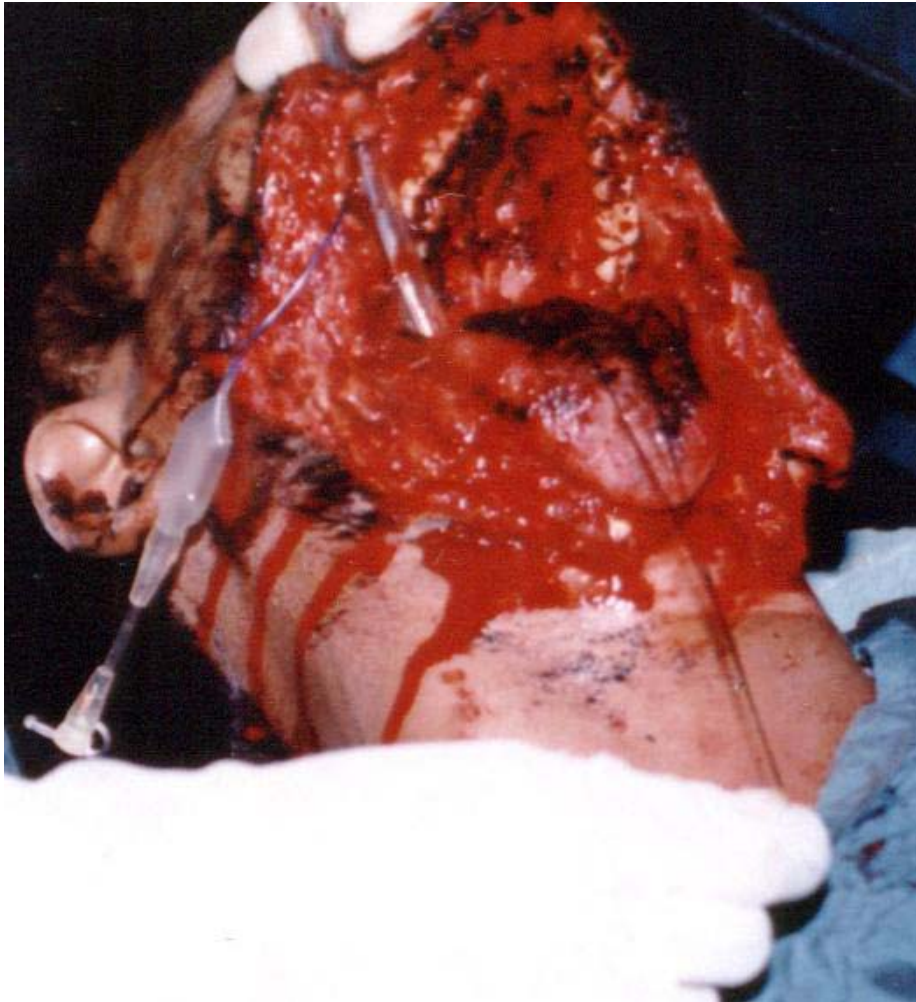

Figure 2. Pulling of the ends of the mattress suture to aid laryngoscopy and intubation

References

1. Rowe N.L , Williams J.L . Maxillofacial Injuries, 2nd edition, Edinburgh, Churchill Livingstone, 1995
2. Fonseca R.J, Walker R.V. Oral and Maxillofacial trauma , 2nd edition, Philadelphia, W B Saunders, 1997
3. Norton.M.L . Atlas of difficult airway, 2nd edition , St Louis, Mosby, 1996
4. Gotta AW. Maxillofacial Trauma: Anesthetic consideration. ASA Refresher Course 15:39, 1987