

Oral prednisolone in the treatment of cervical radiculopathy: A randomized placebo controlled trial

Majid Ghasemi, Ali Masaeli, Majid Rezvani¹, Vahid Shaygannejad, Khodayar Golabchi, Rasul Norouzi

Departments of Neurology, Isfahan Neurosciences Research Center, Isfahan University of Medical Sciences, ¹Departments of Neurosurgery, Isfahan University of Medical Sciences, Isfahan, Iran

Background: Steroids are commonly used in the treatment of cervical radiculopathy (CR), but there is limited information in this regard. We evaluated the efficacy of oral prednisone in the treatment of CR. **Materials and Methods:** This randomized, double-blinded, placebo-controlled trial was conducted on adult patients with neck/shoulder pain for at least 1 month with no alarm symptoms/signs of malignancy, infection, or severe myelopathy, and no contraindication for corticosteroid use. Patients were allocated to receive prednisolone 50 mg/day for 5 days that was tapered within the following 5 days, or placebo. All patients also received acetaminophen 325 mg three times a day and ranitidine 150 mg two times a day. Neck disability index (NDI) and the verbal rating scale (VRS) were used to evaluate the outcomes. **Results:** A total of 59 patients (31 female, mean \pm SD age = 46.2 \pm 9.0 years) completed the study. A significant decrease was observed regarding the NDI and VAS scores from baseline to the end of study in both groups ($P < 0.001$). However, for both the NDI (35.7 \pm 21.4 vs. 12.9 \pm 10.2) and VRS (4.4 \pm 2.7 vs. 1.6 \pm 1.2), the amount of decrease was greater in the prednisone compared with the placebo group ($P < 0.001$). Based on the clinically important change in NDI, pain was improved in 75.8% (22/29) of the prednisolone and 30% (9/30) of the placebo group ($P < 0.001$). **Conclusion:** A short course of oral steroid therapy with prednisolone is highly effective in reducing pain in patients referring with uncomplicated CR. Further studies are warranted on dosing, duration, and long-term efficacy and safety of oral steroid therapy, compared with injection approach.

Key words: Cervical radiculopathy, prednisone, steroids

INTRODUCTION

Cervical radiculopathy (CR) is a neurologic disorder that usually presents with neck and arm pain, accompanied with sensory/motor function loss or reflex changes dependent on the affected nerve root. The reported annual incidence rate of CR is 83.2 per 100,000 populations (male/female ratio = 1.69), and in most of the patients CR presents within the fifth decade of age.^[1] Compressive radiculopathy, mostly resulted from disc herniation or spondylosis, is the main type of CR. Causes of noncompressive radiculopathies include infection, inflammatory, and neoplastic lesions.^[2] The underlying mechanisms of pain in CR are not clear. Although nerve root compression is the most common cause of CR, without compression of dorsal root ganglion, it does not always lead to pain. Some evidence indicates the role of inflammatory mediators (prostaglandin E2, interleukin-6, and nitric oxide), released by herniated discs, in the pathophysiology of pain.^[3,4] Accordingly, anti-inflammatory agents are among the widely used treatments of CR.^[2]

Most of the surgical and nonsurgical therapies of CR have not yet been tested in well-designed trials and current recommendations are mainly based on

anecdotal reports.^[5] Analgesic agents (opioids and nonsteroidal anti-inflammatory drugs (NSAIDs) are often used as the first-line therapy.^[2] Some physicians prescribe a short course (1 week) of oral corticosteroid therapy with prednisone. Studies have also reported beneficial effects of epidural corticosteroid injections. Surgical interventions are limited to those with severe disease and resistant to other less invasive therapies. However, epidural injection and surgery are associated with rare but serious neurologic sequelae.^[1]

Considering the potential serious complications from injections and surgeries, and the lack of qualified data on the efficacy of oral corticosteroid therapies, we conducted a randomized controlled trial (RCT) to evaluate the efficacy of a short course of prednisolone in relieving pain in patients with CR.

MATERIALS AND METHODS

Patients and settings

This randomized, double-blinded, placebo-controlled trial was conducted on patients with CR referring to the clinic of neurology in Kashani University Hospital between 2011 and 2012. Adult patients with neck/shoulder pain for less than 1 month and neck

Address for correspondence: Dr. Majid Ghasemi, Department of Neurology, Isfahan Neurosciences Research Center, Isfahan University of Medical Sciences, Isfahan, Iran. E-mail: m_ghasemi@med.mui.ac.ir

Received: 01-01-2013; **Revised:** 08-02-2013; **Accepted:** 12-02-2013

disability index (NDI) score of 15 or more (indicating moderate disability) were enrolled into the study. Diagnosis was confirmed by needle electromyography (EMG) and nerve conduction study (NCS) tests and MR imaging of cervical spine. Those with alarm symptoms of malignancy or infection (e.g., fever/chills, weight loss, history of malignancy), symptoms and signs of moderate to severe myelopathy, history of immunosuppressant or corticosteroid use, chronic liver disease, diabetes mellitus, osteoporosis, glaucoma, peptic ulcer disease, and pregnant/breastfeeding woman were excluded. Considering type I error (α) = 0.05, study power = 80%, and expecting at least one score difference between the two groups in the amount of change in 11-point numerical pain rating scale (NPRS) score, sample size was calculated as 30 patients in each group. The study protocol was approved by the Ethics Committee of Isfahan University of Medical Sciences and informed consent was obtained from the patients. The study has also been registered in Iranian Registry of Clinical Trials (IRCT138801211804N1).

Blinding and randomization

Patients were randomized within two treatment group using random allocation software.

Neither the investigator nor the patient knew which treatment was to be administered.

An individual without involvement in this study were asked to render medication packages (placebo or prednisolone). Placebo pills were matched to prednisolone in appearance and taste.

Intervention

Patients in the prednisolone group received prednisolone (Aburaihan Co. Iran) 50 mg/day for 5 days that was tapered within the following 5 days. Patients in the placebo group received the placebo pills with the same regimen. All patients also received acetaminophen 325 mg three times a day as the standard treatment, and ranitidine two times a day for preventing adverse effects on gastrointestinal system.

Assessments

At the time of enrollment, patients were interviewed and examined with a neurologist. For confirmation of diagnosis, the EMG and NCS tests were done using Medelec synergy instrument and MR imaging of cervical spine. Two methods were used for the measurement of pain before and after the study; the NDI and the NPRS both of them recommended as appropriate outcome measures for CR treatment trials.^[6] The NDI is a widely used self-administered questionnaire that measures neck pain-related disability. It contains 10 items questioning about different daily activities (7 items), pain intensity (2 items), and concentration (1 item). Each item is scored from

0 (no disability) to 5 (full disability) and the total NDI score ranges from 0 to 50 point (expressed as percentage in this study) for which a higher score indicates a greater patient's perceived disability. The NDI has good psychometric characteristics specially responsiveness to change, which is important for clinical trials.^[6] We also used the 11-point NPRS, which is a general pain rating scale with appropriate psychometric characteristics among patients with CR.^[6] In the NPRS, patient reports the current intensity of pain by choosing a score from 0 = no pain to 10 = worst pain imaginable. The threshold for the minimal clinically important change is advised as 8.5 point for NDI and 2.2 point for NPRS.^[6]

Data analyses

Data were analyzed using SPSS 17 for Windows (SPSS, Inc., Chicago, IL, 1996). Paired *t*-test was used for comparison of the NDI and NPRS scores from before to after the intervention. Independent *t*-test was used to compare baseline characteristics and the amount of change in the mentioned scales between the two groups. Chi-square test was also applied for comparison of baseline characteristics between the two groups. A *P* value < 0.05 was considered as indicating a significant difference in all analyses.

RESULTS

A total of 59 patients including 31 females and 28 males with the mean age of 46.2 ± 9.0 years completed the study. One patient in the prednisolone group was lost for follow-up. There was no significant difference between the two groups regarding baseline characteristics [Table 1].

A significant decrease was observed regarding the NDI and NPRS scores from baseline to the end of study in both groups ($P < 0.001$, Table 2). However, for both the NDI (35.7 ± 21.4 vs. 12.9 ± 10.2) and NPRS (4.4 ± 2.7 vs. 1.6 ± 1.2), the amount of decrease was greater in the prednisolone compared with the placebo group ($P < 0.001$, Figures 1 and 2).

Based on the minimal clinically important change in NDI, pain was improved in 75.8% (22/29) of the prednisolone and 30% (9/30) of the placebo group ($P < 0.001$).

Table 1: Patients' demographic and baseline characteristics

Item	Prednisolone n=29	Placebo n=30	P
Age (year)	46.5±9.5	46.0±8.8	0.840*
Female/male	16 (55.1)/13 (44.8)	15 (50)/15 (50)	0.446**
Nerve root			
C5	4 (13.7)	5 (16.6)	0.993**
C6	14 (48.2)	14 (46.6)	
C7	8 (27.5)	8 (26.6)	
C8	3 (10.3)	3 (10)	

Data are presented as mean±SD or number (%). *Independent *t* test, **Chi-square test

Table 2: Pain severity from before to after the study between in two groups

Indicator	Prednisolone n=29			Placebo n=30		
	Before	After	P*	Before	After	P*
NDI	68.8±17.5	33.1±24.0	<0.001	69.6±17.3	56.7±19.4	<0.001
NPRS	8.4±1.5	4.0±2.6	<0.001	8.5±1.4	6.9±1.7	<0.001

Data are presented as mean±SD. NDI=Neck disability index; NPRS=Numeric pain rating scale; *Paired t test

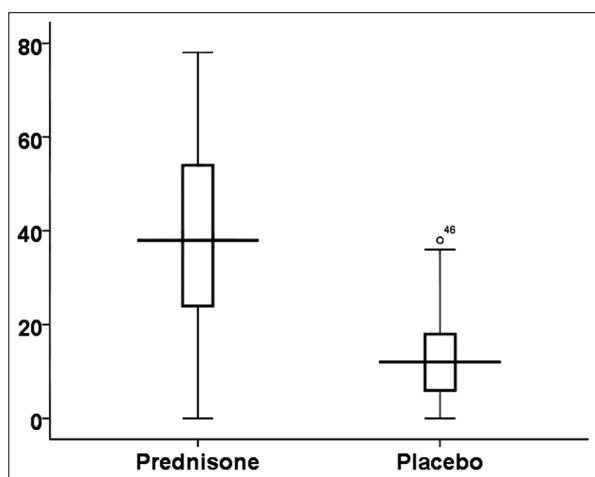


Figure 1: Amount of change in neck disability index score between the two groups

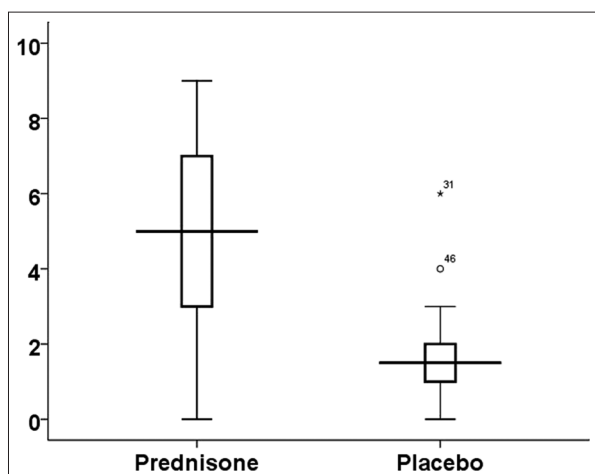


Figure 2: Amount of change in numeric pain rating scale score between the two groups

DISCUSSION

There are two major approaches for the treatment of patients with CR; surgical and nonsurgical interventions. The surgery is usually recommended when there are alarm symptoms/signs of spinal cord impairment, progressive neurologic deficit, or myelopathy, and also if pain is persistent despite for at least 6-12 weeks of nonsurgical treatments. The success rate reported by surgical interventions is about 75% while complications are rare but serious including injury to the spinal cord and nerve root.^[1] Although there are few studies

comparing surgical with nonsurgical interventions and the results showed comparable long-term efficacy,^[7] starting the therapy with nonsurgical interventions in patients without severe signs of cervical myelopathy seems reasonable.^[2]

Commonly used treatments in patients with CR include analgesic agents including NSAIDs and acetaminophen and injected or orally administered steroids.^[2-5] These medicines are recommended based on the role of inflammatory mediators released by the herniated disk. However, most of the commonly recommended nonsurgical therapies of CR are on the basis of anecdotal experiences and have not yet been tested in RCTs.^[5] To the best of our knowledge, our study is the first report of a double-blinded, placebo-controlled trial on oral steroid therapy in patients with CR. The results of our study showed that a short course of therapy with prednisolone is highly effective in reducing neck pain resulting in improvement in two-third of the patients with CR. This success rate was comparable to steroid injection (73-81%) reported by previous studies.^[8-11] Steroid injection, however, is associated with rare but serious neurological complications including brain/spinal cord infarcts,^[12] especially considering that patients usually need repeated injections,^[9] though imaging techniques such as fluoroscopy can increase the safety of injection.^[8-13]

There are some limitations to our study. We did not follow-up with the patients to check what happens after tapering prednisolone, if the CR recurred, need for another course of therapy, long-term side effects of such therapy, and if the patient needed surgery. Steroids are associated with important side effects including impaired glycemic control in diabetes mellitus, worsening of hypertension, and gastritis, all of them are commonly seen in the fifth decade of age in which there is a peak for CR. Therefore, further studies are warranted on dosing, duration, and long-term efficacy and safety of oral steroid therapy, and comparison with injection and also surgical approaches.

CONCLUSIONS

The result of this RCT showed that a short course of oral steroid therapy with prednisolone is highly effective in reducing pain in patients referring with uncomplicated CR. Further studies are warranted on dosing, duration, and long-term efficacy and safety of oral steroid therapy, compared with the injection approach.

ACKNOWLEDGMENT

The authors are thankful to staff of the neurology clinic in Kashani Hospital who helped them in patient recruitment. The authors

are also thankful to Dr. Ali Gholamrezaei who helped them in data analysis.

REFERENCES

- Carette S, Fehlings MG. Cervical radiculopathy. *N Engl J Med* 2005;353:392-9.
- Polston DW. Cervical radiculopathy. *Neurol Clin* 2007;25:373-85.
- Furusawa N, Baba H, Miyoshi N, Maezawa Y, Uchida K, Kokubo Y, *et al.* Herniation of cervical intervertebral disc: Immunohistochemical examination and measurement of nitric oxide production. *Spine (Phila Pa 1976)* 2001;26:1110-6.
- Kang JD, Georgescu HI, Intyre-Larkin L, Stefanovic-Racic M, Evans CH. Herniated cervical intervertebral discs spontaneously produce matrix metalloproteinases, nitric oxide, interleukin-6, and prostaglandin E2. *Spine (Phila Pa 1976)* 1995;20:2373-8.
- Bono CM, Ghiselli G, Gilbert TJ, Kreiner DS, Reitman C, Summers JT, *et al.* An evidence-based clinical guideline for the diagnosis and treatment of cervical radiculopathy from degenerative disorders. *Spine J* 2011;11:64-72.
- Young IA, Cleland JA, Michener LA, Brown C. Reliability, construct validity, and responsiveness of the neck disability index, patient-specific functional scale, and numeric pain rating scale in patients with cervical radiculopathy. *Am J Phys Med Rehabil* 2010;89:31-9.
- Nikolaidis I, Fouyas IP, Sandercock PA, Statham PF. Surgery for cervical radiculopathy or myelopathy. *Cochrane Database Syst Rev* 2010;(1):CD001466.
- Kwon JW, Lee JW, Kim SH, Choi JY, Yeom JS, Kim HJ, *et al.* Cervical interlaminar epidural steroid injection for neck pain and cervical radiculopathy: Effect and prognostic factors. *Skeletal Radiol* 2007;36:431-6.
- Manchikanti L, Cash KA, Pampati V, Wargo BW, Malla Y. The effectiveness of fluoroscopic cervical interlaminar epidural injections in managing chronic cervical disc herniation and radiculitis: Preliminary results of a randomized, double-blind, controlled trial. *Pain Physician* 2010;13:223-36.
- Lee SH, Kim KT, Kim DH, Lee BJ, Son ES, Kwack YH. Clinical Outcomes of Cervical Radiculopathy Following Epidural Steroid Injection: A Prospective Study With Follow-up for More Than 2 Years. *Spine (Phila Pa 1976)* 2012;37:1041-7.
- Lee JW, Park KW, Chung SK, Yeom JS, Kim KJ, Kim HJ, *et al.* Cervical transforaminal epidural steroid injection for the management of cervical radiculopathy: A comparative study of particulate versus non-particulate steroids. *Skeletal Radiol* 2009;38:1077-82.
- Scanlon GC, Moeller-Bertram T, Romanowsky SM, Wallace MS. Cervical transforaminal epidural steroid injections: More dangerous than we think? *Spine (Phila Pa 1976)* 2007;32:1249-56.
- Pobiel RS, Schellhas KP, Eklund JA, Golden MJ, Johnson BA, Chopra S, *et al.* Selective cervical nerve root blockade: Prospective study of immediate and longer term complications. *AJNR Am J Neuroradiol* 2009;30:507-11.

How to cite this article: Ghasemi M, Masaeli A, Rezvani M, Shaygannejad V, Golabchi K, Norouzi R. Oral prednisolone in the treatment of cervical radiculopathy: A randomized placebo controlled trial. *J Res Med Sci* 2013;18:S43-S6.

Source of Support: This study was supported by the Isfahan neuroscience research center, **Conflict of Interest:** None declared.