

# Synovial sarcoma of the mandible

Maryam Khalili, Nosratollah Eshghyar, Fereshteh Ensani<sup>1</sup>, Pouyan Amini Shakib<sup>2</sup>

Department of Oral and Maxillofacial Pathology, Faculty of Dentistry, Tehran University of Medical Sciences, Tehran, Iran; <sup>1</sup>Department of Pathology, Faculty of Medicine, Tehran University of Medical Sciences, Tehran, Iran; <sup>2</sup>Department of Oral and Maxillofacial Pathology, Faculty of Dentistry, Babol University of Medical Sciences, Babol, Iran

Synovial sarcoma (SS) is a relatively common soft tissue tumor but only 6%-7% of cases are diagnosed in the head and neck region. It typically occurs in young adults and is slightly more common in males. The most common sites in the head and neck region are hypopharynx and parapharyngeal spaces. However, SS can also occur in tonsils, tongue, and orofacial soft tissues. It is not difficult to diagnose SS microscopically with its classic biphasic appearance, but the diagnosis of monophasic forms is more challenging especially in unusual locations. In this article, we report a rare case of monophasic SS of the mandible. The clinical, histopathological, and immunohistochemical features are discussed and compared with previously reported cases in the literature. To our knowledge, only six primary involvements have been reported in the jaws. Therefore, our case represents the seventh reported case of SS in the area.

**Key words:** Immunohistochemistry, jaw lesion, mandible, mouth neoplasm, synovial sarcoma

## INTRODUCTION

Synovial sarcoma (SS) is a common mesenchymal malignancy which represents approximately 10% of all soft tissue sarcomas.<sup>[1]</sup> It frequently affects the extremities, and only 6.8% of cases have been reported in the head and neck region.<sup>[2]</sup> It typically occurs in young adults and is more common in males than females. The most common sites in the head and neck region are hypopharynx and parapharyngeal spaces.<sup>[3]</sup> However, SS can also occur in tonsils, tongue, and orofacial soft tissues.<sup>[4]</sup> It is not difficult to diagnose SS microscopically with its classic biphasic appearance, but it is seriously problematic to diagnose the monophasic forms, and in this situation immunohistochemistry is very useful.<sup>[5]</sup> When monophasic variants of SS arise in unusual sites, such as the head and neck region, recognition and differential diagnosis become more difficult. It is important to diagnose this entity in such locations correctly because wide surgical excision without regional node dissection is still the main approach to treatment.<sup>[6]</sup> Because of the rarity of SS in the head and neck region, especially in the jaws, and the risk of misdiagnosis of monophasic variants in unusual sites, the diagnosis of SS requires an integrated multidisciplinary approach

by means of powerful diagnostic tools. In this article, we report a rare case of primary monophasic SS of the mandible and its clinical, histopathological, and immunohistochemical features. Also, a thorough search in the literature was performed, and a comparative summary of all reported cases is presented here.

## CASE REPORT

A 76-year-old man was referred to Oral and Maxillofacial Pathology Department of Tehran University of Medical Sciences, Iran, in February, 2011, with a progressive swelling in the left side of his face of 1-month duration. He also complained of dull pain in the same region and paresthesia of the left half of the lower lip. Clinical examination revealed bony hard, nontender swelling of the posterior region of the mandibular body. Also, submandibular lymph nodes at the same side were enlarged and palpable. No other intra-oral sign was observed and no significant event was noted in his past medical history. A conventional panoramic radiograph showed ill-defined destruction of the posterior mandibular body and ascending ramus [Figure 1]. A computed tomography (CT) scan revealed a destructive lesion at the same region.

An incisional biopsy was performed under local anesthesia. Histopathologic examination of the specimen showed a relatively uniform neoplasm composed almost entirely of spindle cells with irregular, moderately to highly cellular patterns [Figure 2]. Neoplastic cells showed mild pleomorphism and scattered atypical mitotic figures, with no evidence of necrosis [Figure 3]. Based on clinical, radiographic,

Access this article online	
Quick Response Code:	Website: www.journals.mui.ac.ir/jrms
	DOI: ***

**Address for correspondence:** Dr. Pouyan Amini Shakib, Faculty of Dentistry, Ganjafroz Ave., Babol, Iran. E-mail: pouyanshakib@yahoo.com

**Received:** 12-06-2012; **Revised:** 22-07-2012; **Accepted:** 24-07-2012

and histopathologic findings, an initial diagnosis of “malignant spindle cell tumor” was made. Also, a panel of immunohistochemical staining was applied. Odontogenic and nonodontogenic fibrosarcoma, neurogenic sarcoma, angiosarcoma, intraosseous spindle cell carcinoma, and atypical Ewing sarcoma were considered in the differential diagnosis.

Tumor cells were positive for vimentin, cytokeratin (AE1/AE3), CD99, Bcl2, and Ki-67 (more than 25%; all by Dako Co., Tehran, Iran) and negative for smooth muscle actin (SMA) and S100 (all by Dako Co., Tehran, Iran; Figures 4-6). A final diagnosis of “monophasic synovial sarcoma” was made accordingly. The patient was referred to the department of oral and maxillofacial surgery for further management which consisted of hemimandibulectomy with levels I–III cervical lymphnode dissection. The histopathologic examination of the whole specimen confirmed our previous diagnosis. Also, metastatic tumor involvement was observed in one lymph node in level II and one in level III. The patient died 2 months later because of extensive metastasis to the lungs.

## DISCUSSION

SS is a clinically and morphologically well-defined entity that despite its name is not common in joint cavities and is frequently diagnosed in areas having no relation with synovial structures. It occurs primarily in para-articular regions of extremities, usually in a close association with tendon sheaths and joints.<sup>[7]</sup>

In the head and neck region, the hypopharynx is considered as a common site of involvement, but intraoral cases are extremely rare and based on our knowledge, only 39 cases have been reported until 2011.<sup>[6,8,9]</sup> Although the tongue is considered as a common intra-oral site, SS has been reported in other intra-oral areas such as buccal mucosa, floor of the mouth, and jaw bones.<sup>[10]</sup> To our knowledge, only six cases of reported intraoral SSs have occurred in the jaws and our case represents the seventh one. A comparative summary of these cases is shown in Table 1.

Microscopically, the classical form of SS is a biphasic tumor composed of sharply segregated epithelial and sarcomatous components. The epithelial areas usually appear in the form of glands or solid nests of large pale cells. The sarcomatous component is made up of spindle cells with a fibroblast-like appearance. It tends to be hypercellular but with a relatively monotonous appearance and plump nuclei. Monophasic synovial sarcoma is composed of only one of the two components. In most cases, the spindle cell sarcomatous component is observed, which is easily misdiagnosed as fibrosarcoma

**Table 1: Clinicopathologic features of reported cases of synovial sarcoma of the jaws**

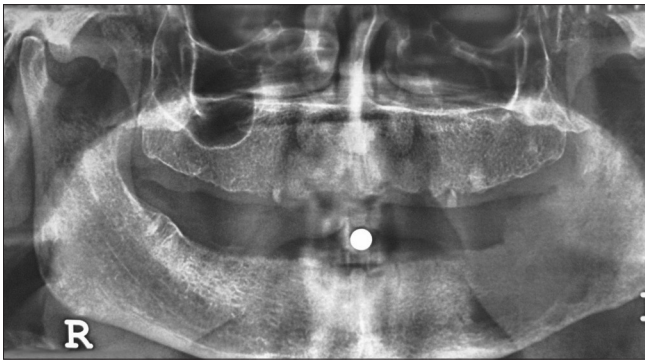
Case	Reference	Age	Gender	Location	Type	Follow-up
1	Maxymiw <i>et al.</i> <sup>[11]</sup>	32	Female	Maxilla	Biphasic	Dead
2	Torsiglieri <i>et al.</i> <sup>[12]</sup>	28	Male	Mandible	Biphasic	Dead
3	Captier <i>et al.</i> <sup>[13]</sup>	10	Male	Mandible	Biphasic	A/W: 1 y
4	Tilakarantne <sup>[14]</sup>	29	Female	Mandible	Monophasic	A/W: 2 y
5	Granowetter <i>et al.</i> <sup>[15]</sup>	11	Male	Mandible	Unknown	A/W: 3 y
6	Tao <i>et al.</i> <sup>[9]</sup>	20	Female	Mandible	Monophasic	A/W: 1 y
7	Present case	76	Male	Mandible	Monophasic	Dead

A/W, alive and well

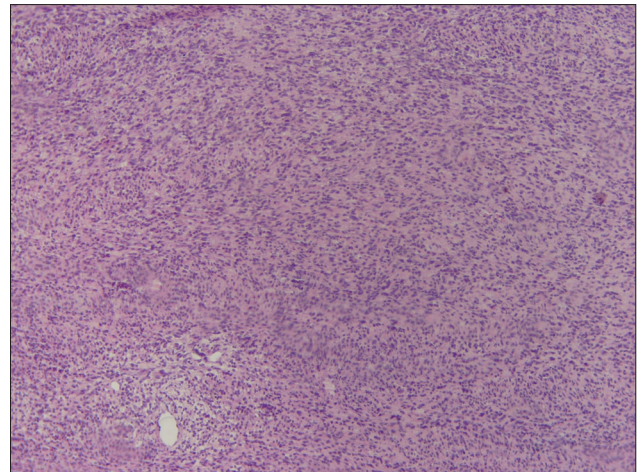
or other spindle cell neoplasms.<sup>[16]</sup> The monophasic form of SS in the jaws requires additional consideration and benign or malignant spindle cell neoplasms with odontogenic origin such as odontogenic fibroma (especially simple type), ameloblastic fibroma, and ameloblastic fibrosarcoma with scant epithelial nests should be included in the differential diagnosis. A careful and comprehensive histopathologic examination of the lesion should be performed to rule out such lesions. Regarding special histochemical staining, mucin stains reveal the presence of acid mucopolysaccharides (hyaluronic acid, chondroitin sulfate, and heparitin sulfate) in the spindle cell areas.<sup>[17]</sup> Immunohistochemical staining can help to differentiate monophasic SS from the other more common nonodontogenic spindle cell neoplasm of the jaws. Strong co-expression of mesenchymal (vimentin) and epithelial (cytokeratin or/and EMA) markers in spindle cells is rarely identified in other neoplasms (neither epithelial nor mesenchymal origin), and combined with positivity for CD99 and Bcl2, the definitive diagnosis of SS can be made. However, it is also recommended to investigate the negative reactivity of spindle-shaped neoplastic cells with S100 and SMA to rule out neurogenic or smooth muscle origin of the cells (although immunoreactivity of some SSs with S100 has been reported).<sup>[17,18]</sup>

Various clinical and histopathologic prognostic factors have been proposed for SS including patient's age, tumor size and location, necrosis, and mitotic index. Recent studies have suggested new prognostic indicators. A Ki67 index of 10% or more is indicative of highly proliferative behavior.<sup>[19]</sup> Our case showed a Ki67 index of more than 25%.

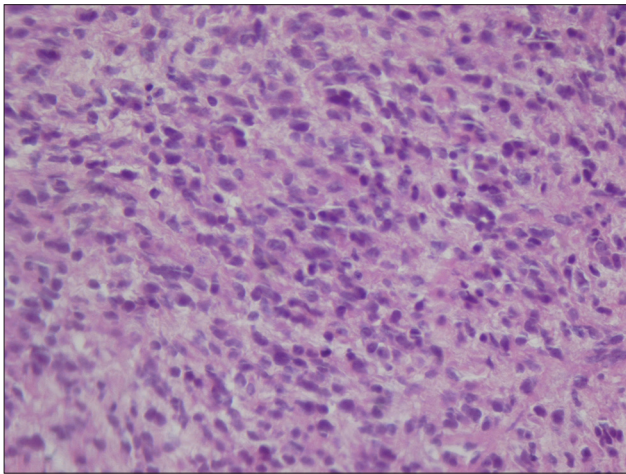
When histopathologic studies are ambiguous in confirming the diagnosis of SS, cytogenetic studies can be helpful. The detection of a specific translocation between chromosome X and 18, t(x; 18)(p11.2; q11.2), found in 95% of tumors is a more significant diagnostic tool.<sup>[20]</sup> However, molecular analysis is not required if the diagnosis of SS is probable



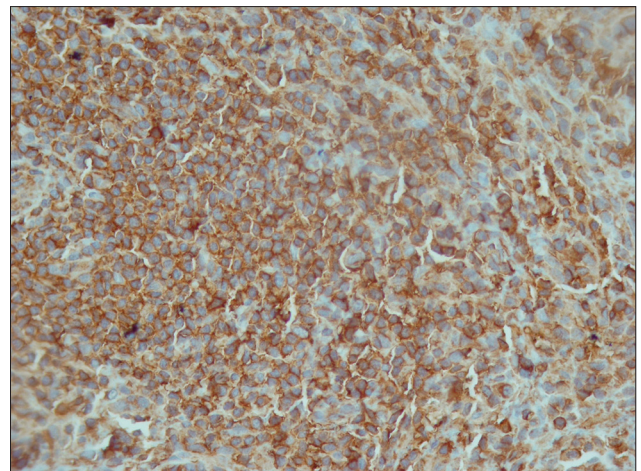
**Figure 1:** Panoramic radiography showed a destructive lesion in the left mandibular body and ramus



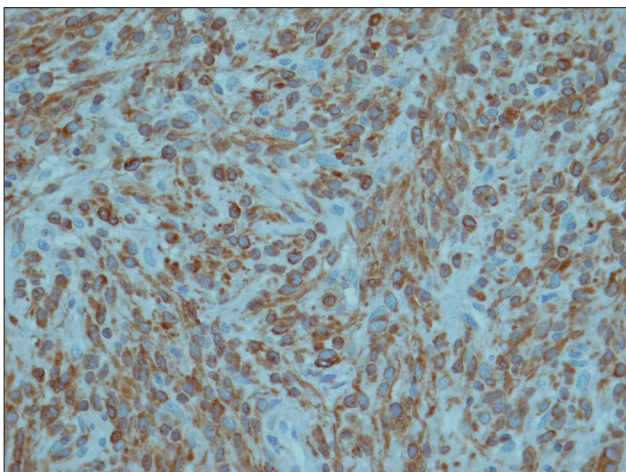
**Figure 2:** Photomicrograph showing a spindle cell neoplasm with irregular, moderately to highly cellular patterns (H and E staining; original magnification  $\times 40$ )



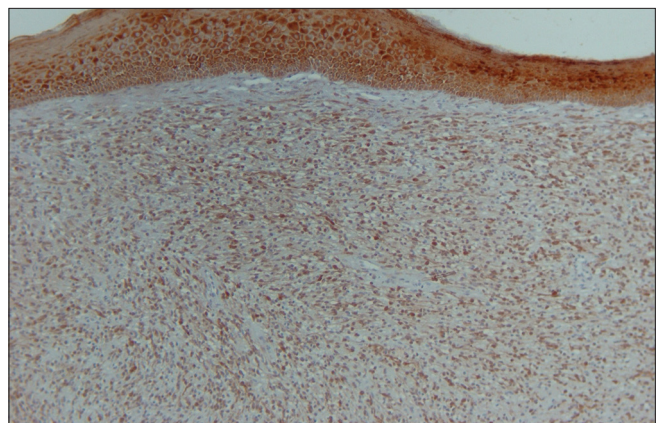
**Figure 3:** Neoplastic cells with mild pleomorphism and scattered atypical mitotic figures (H and E staining; original magnification  $\times 100$ )



**Figure 4:** Positive immunoreactivity of tumoral cells with CD99 antibody ( $\times 100$ )



**Figure 5:** Positive immunoreactivity of tumoral cells with Bcl2 antibody ( $\times 100$ )



**Figure 6:** Positive immunoreactivity of tumoral cells with CK antibody ( $\times 40$ )

based on clinical, histologic, and/or immunohistochemical evaluation.<sup>[10]</sup>

In addition to difficulties in the diagnosis of monophasic SS, a troubling pattern of locoregional recurrence as well as distant metastasis has been described. Because of the rarity of this tumor in the head and neck, the ideal treatment has

not been established yet, but complete surgical resection followed by radiation therapy, without chemotherapy, is suggested<sup>[11]</sup> Our patient was treated by local and regional surgery without radiation and chemotherapy. The poor prognosis was related to regional as well as distant metastasis.

## CONCLUSION

Based on our knowledge, we reported the seventh case of primary SS of the jaws. Because of the rarity of SS in this location, a careful step by step analysis is recommended to prevent misdiagnosis and improve the treatment outcome. Also, we would like to emphasize the critical role of special techniques such as immunohistochemistry and cytogenetics in the diagnosis of monophasic SS.

## REFERENCES

1. Kartha SS, Bumpous JM. Synovial cell sarcoma: Diagnosis, treatment, and outcomes. *Laryngoscope* 2002; 112:1979-82.
2. Park JK, Ham SY, Hwang JC, Jeong YK, Lee JH, Yang SO, *et al.* Synovial sarcoma of the head and neck: A case of predominantly cystic mass. *AJNR Am J Neuroradiol* 2004; 25:1103-5.
3. Rigante M, Visocchi M, Petrone G, Mule A, Bussu F. Synovial sarcoma of the parotid gland: A case report and review of the literature. *Acta Otorhinolaryngol Ital* 2011; 31:43-6.
4. Shaariyah MM, Mazita A, Masaany M, Razif MY, Isa MR, Asma A. Synovial sarcoma: A rare presentation of parapharyngeal mass. *Chin J Cancer* 2010; 29:631-3.
5. Coindre JM, Pelmus M, Hostein I, Lussan C, Bui BN, Guillou L. Should molecular testing be required for diagnosing synovial sarcoma? A prospective study of 204 cases. *Cancer* 2003; 98:2700-7.
6. Agarwal AP, Shet TM, Joshi R, Desai SB, Chinoy RF. Monophasic synovial sarcoma of tongue. *Indian J Pathol Microbiol* 2009; 52:568-70.
7. Weiss SW, Goldblum JR. *Enzinger and Weiss's soft tissue tumors*. 5<sup>th</sup> ed. USA: Mosby; 2008. p. 11-66.
8. Vogel U, Wehrmann M, Eichhorn W, Bultmann B, Stiegler M, Wagner W. Molecular and clinicopathological findings in a tonsillar synovial sarcoma. A case study and review of the literature. *Head Neck Pathol* 2010; 4:257-60.
9. Tao Q, Qiao B, Wang Y, Hu F. Diagnosis and treatment of primary synovial cell sarcoma that occurred in the left mandible body: A case report and literature review. *Oral Surg Oral Med Oral Pathol Oral Radiol Endod* 2011; 111:e12-20.
10. Wang H, Zhang J, He X, Niu Y. Synovial sarcoma in the oral and maxillofacial region: Report of 4 cases and review of the literature. *J Oral Maxillofac Surg* 2008; 66:161-7.
11. Maxymiw WG, Wood RE. Synovial sarcoma of the maxillofacial region with osseous involvement. Case report. *Int J Oral Maxillofac Surg* 1990; 19:305-7.
12. Torsiglieri AJ Jr, Hendrix RA, Quinn PS. Synovial sarcoma of the jaw. *Ear Nose Throat J* 1991; 70:396-8.
13. Captier G, Montoya P, Duche R, Le Barazer M, Bigorre M, Marguerite G. Synovial sarcoma of the mandible in children. Apropos of a case. *Rev Stomatol Chir Maxillofac* 1999; 100:187-91.
14. Tilakaratne WM. Synovial sarcoma of the mandible. *J Oral Pathol Med* 2006; 35:61-3.
15. Granowetter L, Ladas E, Taromina K, Rooney D, Kelly KM. Integrative tumor board: Pediatric synovial sarcoma. *Integr Cancer Ther* 2006; 5:48-55.
16. Sharif MA, Mushtaq S, Mamoon N, Khadim MT, Asghar Z. Biphasic synovial sarcoma of oral cavity. *J Coll Physicians Surg Pak* 2008; 18:713-5.
17. Rosai J. *Rosai and Ackerman's Surgical Pathology*. 9<sup>th</sup> ed. USA: Mosby; 2004. p. 2311.
18. Jang KS, Min KW, Jang SH, Paik SS, Tae K, Jang SJ, *et al.* Primary synovial sarcoma of the thyroid gland. *J Korean Med Sci* 2007; 22:S154-8.
19. Bilgic B, Mete O, Ozturk SA, Demiryont M, Keles N, Basaran M. Synovial sarcoma: A rare tumor of larynx. *Pathol Oncol Res* 2003; 9:242-5.
20. Khademi B, Daneshbod Y, Negahban S, Daneshbod K, Kaviani M, Mohammadianpanah M, *et al.* Biphasic parapharyngeal synovial sarcoma: A cytologic and immunocytologic report of a case. *Cytojournal* 2006; 3:20.

**How to cite this article:** Khalili M, Eshghyar N, Ensani F, Shakib PA. Synovial sarcoma of the mandible. *J Res Med Sci* 2012;17:1082-5.

**Source of Support:** Nil, **Conflict of Interest:** None declared.