

## A case of missed biliary ascariasis: Endoscopic retrograde cholangiography still remains the gold standard

Sir,

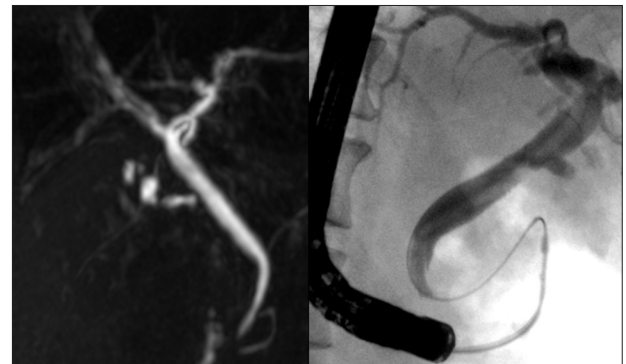A 50-year-old male presented with a 10-day history of jaundice associated with epigastric pain (Institute of Liver and Biliary Sciences, New Delhi, India, 2011). About six weeks prior to this admission, he had an episode of obstructive jaundice for which he had undergone Endoscopic Retrograde Cholangiopancreatography (ERCP), biliary sphincterotomy, and removal of sludge-like material from the bile duct. His investigations were as follows: Serum bilirubin 8.4 mg/dl, alanin transaminase: 141 IU/L, alkaline phosphatase 204 IU/l, and white blood cell count 9200/mm<sup>3</sup>. His abdominal ultrasound and magnetic resonance cholangiopancreatography (MRCP) revealed a mildly dilated common bile duct (CBD), without any definite evidence of any obstructive lesion. A repeat ERCP was performed two days after MRCP, which revealed a linear filling defect in the CBD [Figure 1] consistent with *Ascaris lumbricoides* worm [Figure 2]. The patient improved rapidly after removal of the worm.

The ultrasound (US) is the imaging modality of choice for biliary ascariasis.<sup>[1,2]</sup> However, the sensitivity of US for detection of a single worm is only 50%.<sup>[1,3,4]</sup> The

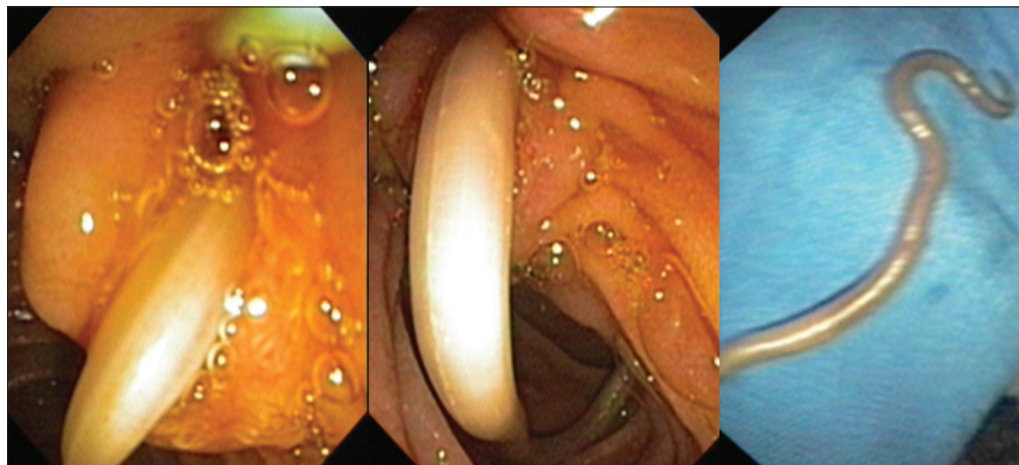
operator dependency and poor visualization of lower CBD are other limitations of US, for detection of biliary ascariasis. MRCP is very accurate in providing detailed information of the biliary system, without operator-dependency. It shows intraductal ascaris as linear hypointense filling defects.<sup>[5]</sup> However, in this case, the worm remained undetected by both modalities (US and MRCP). The migration of the worm out of the CBD remains a possibility; however, with progressive worsening of symptoms, this is questionable. The easy detection and removal of the worm by ERCP suggests that it is still the gold standard for this condition. Biliary sphincterotomy is frequently performed during ERCP,<sup>[6]</sup> and it is considered to be a risk factor for biliary ascariasis. It is well-known that MRCP has a poorer resolution than ERCP, and it can miss certain lesions like small stones, small ampullary tumor, and strictures. However, whether it can miss a large worm has not been reported.

**Ramesh Kumar**

Department of Hepatology, Institute of Liver and Biliary Sciences (ILBS), New Delhi, India



**Figure 1:** MRCP (left panel) showing no definite evidence of a filling defect in the bile duct, while ERCP done within a two-day interval revealed a linear filling defect (right panel) within the common bile duct, suggestive of a worm



**Figure 2:** Left panels show *Ascaris lumbricoides* partially coming out of the major ampulla on a side viewing endoscope, and the right panel shows the extracted worm

**Address for Correspondence:** Dr. Ramesh Kumar,  
Department of Hepatology, Institute of Liver and  
Biliary Sciences (ILBS), Sector D1, Vasant Kunj, New Delhi, India.  
E-mail: docrameshkr@gmail.com

## REFERENCES

1. Khuroo MS, Zargar SA, Mahajan R, Bhat RL, Javid G. Sonographic appearances in biliary ascariasis. *Gastroenterology* 1987;93:267-72.
2. Ibrarullah M, Mishra T, Dash AP, Upadhaya UN. Biliary ascariasis--role of endoscopic intervention. *Trop Gastroenterol* 2011;32:210-3.
3. Kalra N, Gulati A, Khandelwal N, Duseja A, Behra A, Joshi K. Pitfall in the diagnosis of biliary ascariasis. *J Clin Ultrasound* 2009;37:161-2.
4. Das CJ, Kumar J, Debnath J, Chaudhry A. Imaging of ascariasis. *Australas Radiol* 2007;51:500-6.

5. Alper F, Kantarci M, Bozkurt M, Ozturk G, Onbas O, Balik AA. Acute biliary obstruction caused by biliary ascaris in pregnancy: MR cholangiography findings. *Clin Radiol* 2003;58:896-8.
6. Khatibian M, Sotoudehmanesh R, Ali-Asgari A, Movahedi Z, Kolahdoozan S. Needle-knife fistulotomy versus standard method for cannulation of common bile duct: A randomized controlled trial. *Arch Iran Med* 2008;11:16-20.

Access this article online	
<b>Quick Response Code:</b>	<b>Website:</b> www.journals.mui.ac.ir/jrms
	<b>DOI:</b> ***