

Distraction osteogenesis in the hand with and without K-wire

Mahmoud Omranifard¹, Hossein Abdali¹, Yousef Shafaiee², Payam Kabiri³, Farzaneh Aminpour⁴, Amir Mahdi Ansari⁵, Noushin Jazebi⁵

¹ Associate Professor, Department of Plastic Surgery, School of Medicine, Isfahan University of Medical Sciences, Isfahan, Iran. ² Resident, Department of Plastic Surgery, School of Medicine And Student Research Committee, Isfahan University of Medical Sciences, Isfahan, Iran. ³ Department of Biostatistics and Epidemiology, School of Public Health, Tehran University of Medical Sciences, Tehran, Iran. ⁴ Medical Education Research Center, Isfahan University of Medical Sciences, Isfahan, Iran And Department of Health Information Management, School of Health Management and Information Sciences, Tehran University of Medical Sciences, Tehran, Iran. ⁵ Isfahan University of Medical Sciences, Isfahan, Iran.

BACKGROUND: Distraction osteogenesis is an established option for reconstruction of amputated fingers. In contrast to the primary method of distraction osteogenesis, using Kirschner wire (K-wire) as an internal fixator is not common today. This study was conducted to evaluate distraction osteogenesis with and without K-wire. **METHODS:** This randomized clinical trial was conducted on 16 amputated fingers which were divided into two equal groups. While we used both orthofix M-100 and K-wire in the first group, only orthofix M-100 was implemented in the second group. The results were analyzed by t-test in SPSS_{11.5}. **RESULTS:** Overall, 16 fingers of 8 male patients whose one or more fingers were cut due to hand trauma were evaluated in two random groups. The mean daily lengthening rates in Groups 1 and 2 were 0.44 ± 0.17 mm and 0.4 ± 0.11 mm, respectively ($p = 0.59$). The mean time required for 1 cm lengthening was 18.71 ± 4.07 and 23.25 ± 4.56 days in Groups 1 and 2, respectively ($p = 0.065$). The mean value of overall lengthening was 16.25 ± 8.05 mm in Group 1 and 16.69 ± 4.89 mm in Group 2 ($p = 0.89$). Moreover, some minor complications occurred in 9 samples. **CONCLUSIONS:** There was no statistically significant difference between the two groups. However, in the K-wire group, the time needed for 1 cm lengthening was clinically shorter. In addition, fewer complications, such as non-union and length loss, were observed in Group 1.

KEYWORDS: Osteogenesis, Distraction, Kirschner Wire, Bone Wire, External Fixators, Internal Fixators, Callotasis

BACKGROUND

One of the most important parts of human body is the hand which is mainly critical for individuals to supply their needs and environmental communications. A major area of sensory cortex in brain is devoted to hands.^[1,2] In addition, the exclusive ability of fingers to touch objects, sense, and perform art is unique in mankind.^[1]

The first and most crucial surgical decision in facing severe finger injuries is how to survive the fingers or cut them in appropriate time. Needless to say, making the final decision depends on the patient himself, the severity of injury, and the surgeon's ability to achieve an acceptable result.^[1,3] In most cases of injuries, it is impossible to keep the fingers due to destruction of vital hand elements such as vessels, nerves, and dermis. Therefore, fingers must inevitably be amputated.^[4] Since the appropriate length of the finger is essential for its normal function, the goal of distraction is to create the desired finger length.^[5] Additionally, finger distraction and surgical repairing lead to improvement of both function and appearance of the finger.

Use of distraction osteogenesis (callotasis) as an osteogenesis method with gradual distraction after bone edge osteotomy originally goes back to the 19th century.^[1] In 1966, osteogenesis distraction (with gradual stretch) was introduced for the first time by Matev. He lengthened the cut thumb of a twelve-years-old boy to 38 mm, using an external fixator. In this technique, a Kirschner wire (K-wire) was placed in the thumb and finger lengthening was carried out without any considerable sensory loss or scar.

Distraction osteogenesis is used in reconstruction of either traumatic cuts or congenital abnormalities of fingers. This method has gained popularity in hand surgery because of simultaneous growth of soft tissue vessels and nerves around the lengthened bone which thus eliminates the need for vessel-nerve reconstruction.^[6,7] Distraction osteogenesis is an established option for reconstruction of amputated fingers. In contrast to the primary method of distraction osteogenesis, using K-wire (internal fixator) is not common today. This study was conducted to evaluate distraction osteogenesis with and without K-wire.

Address for correspondence: Mahmoud Omranifard, Associate Professor, Department of Plastic Surgery, School of Medicine, Isfahan University of Medical Sciences, Isfahan, Iran. Email: m_omranifard@med.mui.ac.ir

Received: 24.11.2011; **Revised:** 26.12.2011; **Accepted:** 28.01.2012

METHODS

This randomized, non-blinded, parallel-group clinical trial study was registered as research project No. 388453 and supported by Isfahan University of Medical Sciences, Isfahan, Iran. It was conducted in Al-zahra and Imam Musa Kazem Hospitals (Isfahan, Iran) during 2009-10. This It was carried out on 16 fingers of 8 male patients whose one or more fingers were cut due to hand trauma. They were at least 13 years old. Minimal distraction requirement was the one-centimeter length of the cut fingers. The procedure was done at least 6-8 weeks after the final reconstruction. All cut sites had appropriate skin coverage without large scars. The same contralateral finger was normal as well.

Patients were randomly assigned following simple randomization procedures (computerized random numbers) to 1 of the 2 treatment groups. In group 1, osteogenesis distraction was performed using M100 as an external fixator while K-wire was also placed in parallel with the finger axis as an internal fixator. In the second group however, only an external fixator was placed.

The procedure of external fixator embedding was conducted in the operating room and under general anesthesia. After skin incision on the dorsal side of the finger and soft tissue retraction, a certain bone was exposed with longitudinal excision. Horizontal osteotomy with maximum periosteum protection was subsequently performed in the exposed bone level. Bone lengthening, orthofix device, and K-Wire were evaluated by X-ray imaging after primary operation and during distraction osteogenesis periods.

In the next step, 5-10 days post-operation, after wound healing, gradual distraction was initiated twice a day using an Allen wrench to rotate the fixator pin. Generally, the distraction speed was 1 mm/24 hrs and was variable considering the sense of finger and patient tolerance. If the patient had pain or sensory impairment and if there was any resistance against pin rotation, the distraction speed was reduced. As soon as the bone reached the appropriate length, the process of pin rotation was stopped. The external fixator was removed just after consolidation phase. All patients were followed 6 months after the removal of the external fixator. The data was entered into SPSS_{11.5} (SPSS Inc., Chicago, IL) for Windows. The descriptive data was presented as mean \pm SD. Comparisons were made using t-test at a significance level of 0.05.

RESULTS

In this study, 16 fingers of 8 patients were equally divided into two groups to receive treatment with (Group 1) or without (Group 2) using a K-wire. All patients were male and aged 13-46 years old. The mean age of patients was 28.81 years (26.38 ± 10.30 years in the first group and 31.25 ± 9.11 years in the second group; $p = 0.333$). The fingers were cut due to trauma in both right and left hands. Distraction sites included 2 (12.5%) in the first metacarpal (MTC), 12 (75%) in the proximal phalange, and 2 (12.5%) in the middle phalange.

The primary length of fingers varied from 14 to 76 mm with the mean of 33.06 mm. The mean length of cut fingers before bone distraction was not significantly different between the two groups (31.31 ± 16.74 mm in Group 1 and 33.56 ± 20.23 mm in Group 2; $p = 8.3$).

Osteodistraction is a light and simple device. The patient would not experience any disability during the course of lengthening. In addition, at the end of the treatment, the finger would be longer, have a good appearance, and better function. As a result, the patient can use better prostheses (Figure 1).

As figure 2 shows, bone lengthening, orthofix device, and K-wire were evaluated with X-ray after the primary operation and during distraction osteogenesis periods.

In addition to cosmetic effects, bone lengthening can help hand function. In fact, a 1-cm lengthening of a finger can significantly increase hand function (Figures 3 and 4). Moreover, in case of a hand with multiple amputated fingers, distraction can lead to better implementation of prosthesis (Figures 5 and 6) and improve the function.

In general, the minimum and maximum lengthening rates were 0.166 mm and 0.69 mm per day, respectively (mean: 0.42 mm). Therefore, it takes 15 to 30 days (mean: 21.13 days) to reach a 1-cm finger growth. The mean finger bone growth was 0.44 ± 0.17 mm/24 hrs in Group 1 and 0.4 ± 0.11 mm/24 hrs in Group 2 ($p = 0.594$). In other words, a 1-cm bone growth in took 18.71 ± 4.07 days in Group 1 and 23.25 ± 4.56 days in Group 2. Although this difference is clinically considerable, it was not statistically significant ($p = 0.065$). The mean increased length was 16.25 ± 8.05 mm in Group 1 and 16.69 ± 4.89 mm in Group 2 ($p = 0.897$). Meanwhile, the distracted length ranged from

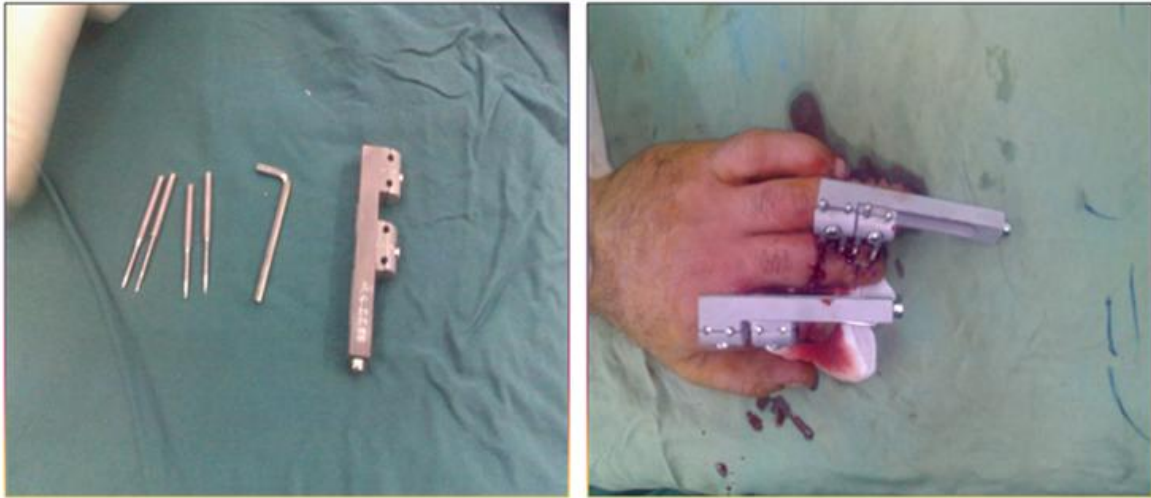


Figure 1. Osteodistraction device

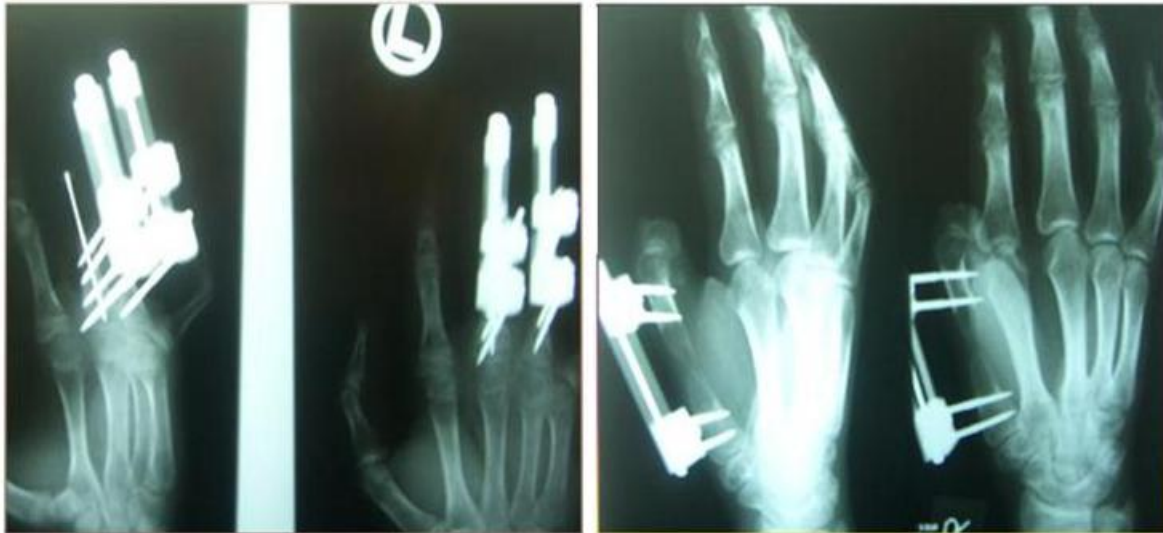

Figure 2. X-ray images of osteodistraction with and without K-wire

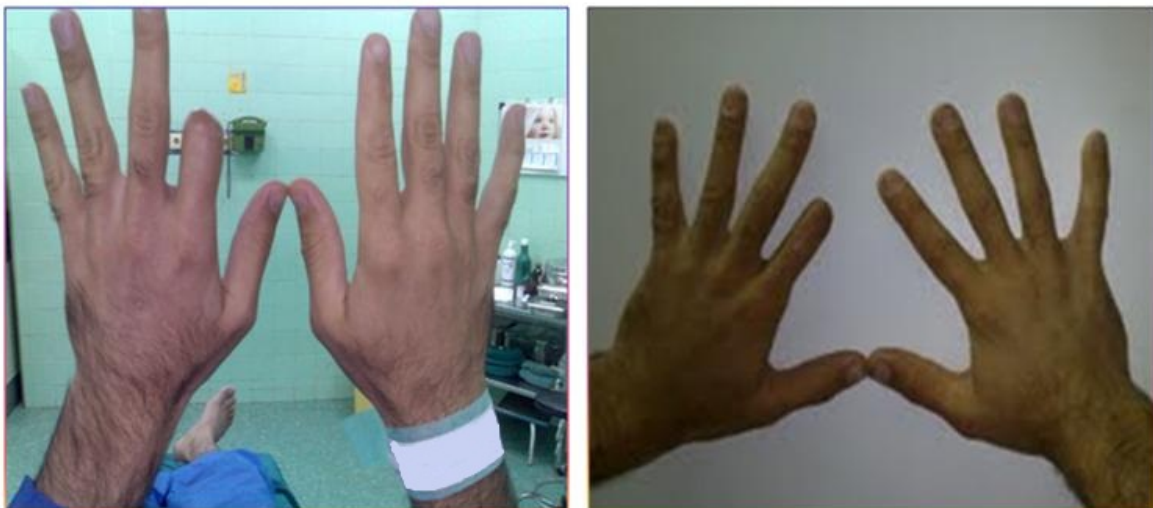

Figure 3. Index finger lengthening before and after distraction




Figure 4. Thumb length before and after distraction osteogenesis

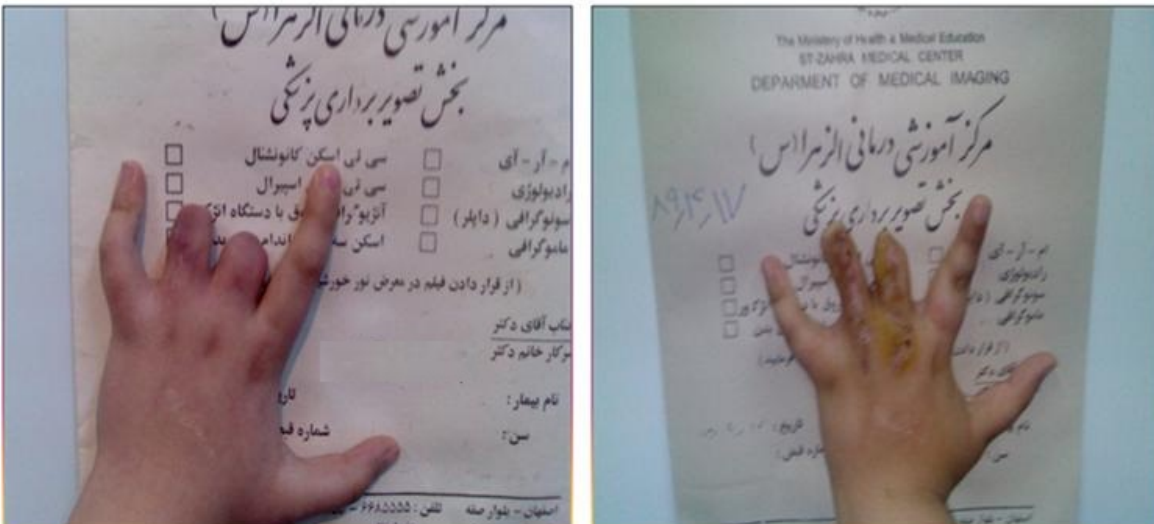


Figure 5. Middle and ring fingers lengthening before and after distraction

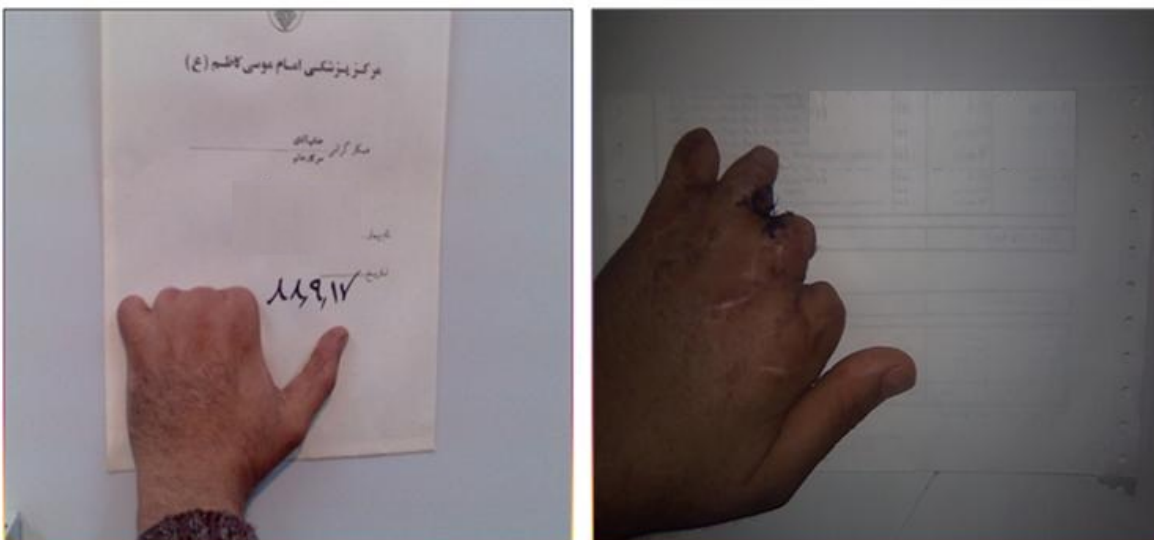


Figure 6. Hand with four amputated fingers before and 2 months after osteodistraction

8 to 24.5 mm with a mean of 16.46 mm.

Nine fingers of both groups (56.25%) experienced several complications, 4 fingers had 1 complication, 3 fingers had 2 complications and two fingers had 3 complications. In Group 1, 4 fingers (50%) and in Group 2, 5 fingers experienced at least one complication ($p = 0.614$). Non-union complications were observed in one finger in Group 1 (12.5%) and 4 fingers in Group 2 (50%) ($p = 0.106$). In addition, malunion was absent in Group 1 but occurred in one finger in Group 2 (12.5%) ($p = 0.302$).

Bending occurred in one case in Group 1 (12.5%) and two cases in Group 2 (25%) ($p = 0.552$). Finger length loss was seen in one (12.5%) and 4 (50%) cases in Groups 1 and 2, respectively ($p = 0.106$). Dislocation of the fixator pin was detected in 2 fingers (25%) in Group 1 and no fingers in Group 2 ($p = 0.131$). The two groups were not significantly different according to a satisfaction questionnaire.

DISCUSSION

The implementation of K-wire is very easy and increases the operation time only 5-10 minutes. Moreover, we believe this method can guarantee bone immobility during distraction and fix the bone during early post-operation period without causing any major disability.

Distraction osteogenesis is a safe and efficient method for bone lengthening with minimum morbidity and is highly useful in metacarpal and phalangeal reconstruction. This method is also feasible in younger ages. Dhalla et al. applied the method in 2-6 years-old patients (mean age: 7.9 years). They treated 20 metacarpals and 7 phalanges which shows metacarpal lengthening to be helpful in hand function improvement.^[8,9] In our study however, the mean age of patients was 28.81 years and 2 metacarpal and 12 phalange bones were lengthened.

Similar to previous studies, the present study found mean bone lengthening speed to be 0.44 mm/day in Group 1 and 0.40 mm/day in Group 2 (the overall mean lengthening speed: 0.42 mm/day). The mean bone lengthening was 16.46 mm in all samples (16.25 mm in Group 1 and 16.69 mm in Group 2; $p = 8.7$). Previous studies have reported the rates as 11.5 mm and 14 mm with and without using K-wire, respectively.

The overall incidence of complications was 56.2% and

the two groups were not significantly different in this regard (56.25% with and 50% without K-wire; $p = 0.614$). Fortunately, none of the complications in this study was major. The high incidence of complications reported by Baccari et al.^[10] our study did not significantly interfere with the final results.

Impaired consolidation at the end of the process is an important complication which was observed in 5 cases (31.25%) including one in Group 1 (12.5%) and 4 in Group 2 (50%). Even though the difference was clinically obvious, it was not statically significant ($p = 0.106$). Therefore, more subjects are needed in further investigations.

In accordance with previous studies, just one case in Group 1 and 2 cases in Group 2 experienced bending and bone axis deviation. Heo et al. observed the mentioned complications in 2 cases (16.6%) which are closely similar to our study.^[11] Moreover, we detected pin dislocation in 2 cases of Group 1. Since both fingers had a primary length of less than 17 mm, it is recommended to use K-wire for fingers with a length of at least 17 mm. Heitmann and Levin^[12] and Houshian and Ipsen^[13] also reported pin dislocation.

It is worth mentioning that some complications such as nerve and vessel injuries, premature consolidation, and dermis necrosis which were seen in some previous research^[8] were not observed in this study. The two groups were not significantly different in terms of satisfaction from distraction fixator.

Based on the available literature, several approaches to lengthening, including single stage and rapid distraction lengthening with bone graft, have been implemented.^[14] Volpi and Fragomen's study^[14] confirmed that gradual distraction is a preferred method due to cosmetic outcomes with few post-operative complications as we showed in our study. Therefore, this method can be used not only as an adjuvant method with other complex methods for bone lengthening but also as a major method for hand reconstruction.^[15]

As explained before, we used this method for traumatic phalangeal bone defect. Nevertheless, it is also a good choice for congenital hand defect and brachydactyly.^[16,17] Similar to Franssen et al.,^[18] this study also showed the usage of K-wire with distraction osteogenesis to be able to improve the safety and stability of the procedure without any complications.

CONCLUSIONS

Distraction osteogenesis is a very simple method which can increase bone length with minimal disability during distraction osteogenesis. Using K-wire would decrease complications and could guarantee bone fixation and stability during operation and in the early post-distraction osteogenesis period.

ACKNOWLEDGMENTS

This paper is derived from a specialty thesis in Isfahan University of Medical Sciences.

REFERENCES

1. A Mathes SJ. *Plastic Surgery: The Hand and Upper Limb*. 2nd ed. Philadelphia: Saunders; 2005.
2. Hall JE, Guyton C. *Textbook of Medical Physiology*. 10th ed. Philadelphia: Saunders; 2000.
3. Gupta A, Shatford RA, Wolff TW, Tsai TM, Scheker LR, Levin LS. Treatment of the severely injured upper extremity. *J Bone Joint Surg* 1999; 81A:1628-51.
4. Brown PW. The rational selection of treatment for upper extremity amputations. *Orthop Clin North Am* 1981; 12(4): 843-8.
5. Vekris MD, Darlis NA, Beris AE, Mitsionis GI, Soucacos PN. Digital ray reconstruction through distraction osteogenesis lengthening. *J Bone Joint Surg Br* 2003; 85(Suppl III): 219-20.
6. Heitmann C, Levin LS. Alternatives to thumb replantation. *Plast Reconstr Surg* 2002; 110(6): 1492-503.
7. Gordon A, Page R, Saleh M. Index finger lengthening by gradual distraction and bone grafting. *J Hand Surg Br* 1998; 23(6): 785-7.
8. Dhalla R, Strecker W, Manske PR. A comparison of two techniques for digital distraction lengthening in skeletally immature patients. *J Hand Surg Am* 2001; 26(4): 603-10.
9. Matev IB. The bone-lengthening method in hand reconstruction: twenty years' experience. *J Hand Surg Am* 1989; 14 (2 Pt 2): 376-8.
10. Baccari S, Charfi H, Daghfous M, Ennouri K, Tarhouni L, Bahri H. [Digital lengthening by gradual distraction]. *Chir Main* 2006; 25(1): 33-9.
11. Heo CY, Kwon S, Back GH, Chung MS. Complications of distraction lengthening in the hand. *J Hand Surg Eur Vol* 2008; 33(5): 609-15.
12. Heitmann C, Levin LS. Distraction lengthening of thumb metacarpal. *J Hand Surg Br* 2004; 29(1): 71-5.
13. Houshian S, Ipsen T. Metacarpal and phalangeal lengthening by callus distraction. *J Hand Surg Br* 2001; 26(1): 13-6.
14. Volpi AD, Fragomen AT. Percutaneous distraction lengthening in brachymetacarpia. *Orthopedics* 2011; 34(8): e424-7.
15. Patterson RW, Seitz WH, Jr. Nonvascularized toe phalangeal transfer and distraction lengthening for symbrachydactyly. *J Hand Surg Am* 2010; 35(4): 652-8.
16. Das SP, Mohanty RN, Das SK. Metacarpal lengthening by distraction histiogenesis in adults. *Indian J Orthop* 2009; 43(4): 379-82.
17. Nguyen ML, Jones NF. Undergrowth: brachydactyly. *Hand Clin* 2009; 25(2): 247-55.
18. Franssen BB, Schuurman AH, Van der Molen AM, Kon M. One century of Kirschner wires and Kirschner wire insertion techniques: a historical review. *Acta Orthop Belg* 2010; 76(1): 1-6.

How to cite this article: Omranifard M, Abdali H, Shafaiee Y, Kabiri P, Aminpour F, Ansari AM, et al. Distraction osteogenesis in the hand with and without K-wire. *J Res Med Sci* 2012; 17(5) Special Issue 2: S204-S209.

Source of Support: Isfahan University of Medical Sciences, **Conflict of Interest:** None declared.