

Case Report

Unicameral bone cyst of the proximal tibia in a five year old girl

Mohammadali Tahririan¹, Mehdi Motiffard¹

Abstract

Unicameral bone cysts (UBCs) are benign, osteolytic lesions which are often asymptomatic and are commonly seen in the proximal of humerus and femur. The average age at diagnosis is 9-11 years and there is a male preponderance with a male-to-female ratio of approximately 2-2.5 to 1. We describe a case of 5-year-old girl who presented to orthopedic clinic with a 4-month history of painful limping. Plain radiography of the right knee demonstrated a well-defined lytic lesion in the proximal of the tibia. Open biopsy and then curettage and bone grafting with bone- substitute was performed. The diagnosis of this condition requires a high index of suspicion. This report demonstrates that all UBCs do not have the same clinical patterns and with adequate attention good results can be achieved.

KEYWORDS: Unicameral Bone Cyst, Benign, Limping, Pain.

J Res Med Sci 2012; 17(1): 104-107

Unicameral bone cysts (UBCs) are benign, osteolytic lesions which are often asymptomatic and are commonly seen in the proximal of humerus and femur. The average age at diagnosis is 9-11 years and there is a male preponderance with a male-to-female ratio of approximately 2-2.5 to 1.

Case Report

A 5-year-old girl presented to our clinic (Kashani hospital, Isfahan, Iran, 2011) with a history of 4-month pain around her right knee. She had a painful limping. There was no history of any specific infection or trauma. She did not have any similar complain previously. The pain was constant throughout the day but was alleviated by analgesics. There was a moderate tenderness in the proximal of tibia in palpation without any warmth or change in color of the skin in the suspicious area. There was no limitation in arc of motion of her right knee and hip. The child was not febrile and there was no sign or symptom of systemic illness. Hematological investigations (include leukocyte count, cell profile, erythrocyte sedimentation rate,

calcium, phosphorus and alkaline phosphatase) were normal.

Before referring to our clinic, she had been visited 3 months ago by an orthopedic surgeon, and a plain radiography had been requested. At that time, the plain radiography of the right knee demonstrated a small well-circumscribed eccentric lesion in the proximal medial metaphyseal region of the tibia without disruption of the cortex (Figure 1), and the patient had been treated conservatively with suspicious of fibrous cortical defect.

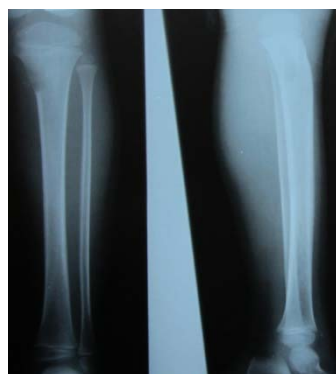

Figure 1. First presentation with small eccentric lucent lesion

1- Assistant Professor, Department of Orthopedic Surgery, School of Medicine, Isfahan University of Medical Sciences, Isfahan, Iran.
Corresponding author: Mohammadali Tahririan
E-mail: tahririan@med.mui.ac.ir

3 months later she was referred to our clinic with a new plain radiography, which demonstrated a large well-defined centric lytic lesion with involvement of both medial and lateral portion of proximal tibial metaphysis, without disruption of cortices and physis (Figure 2). There was no evidence of fallen leaf sign or obvious sclerotic border. Furthermore, there was no obvious septation but to some extent cortical expansion. Because of rapid progression of the lytic lesion, a magnetic resonance imaging (MRI) was requested. MRI reported an expansile centric, septated cystic lesion in metadiaphyseal part of the right tibia without fracture or secondary changes in muscular component (Figure 3). Signal of lesion was high on T2-weighted and low on T1-weighted.

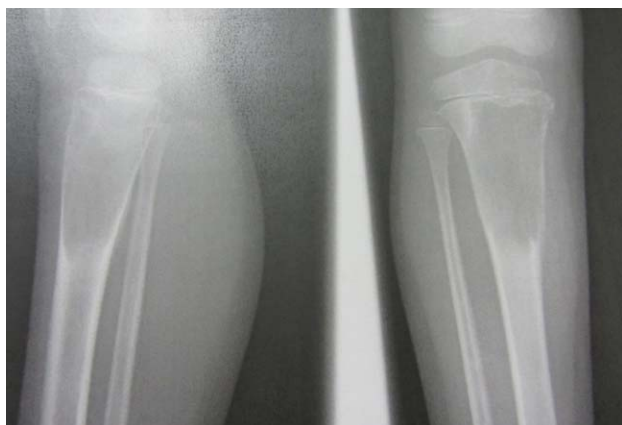

Figure 2. Rapid expansion of lesion after three months

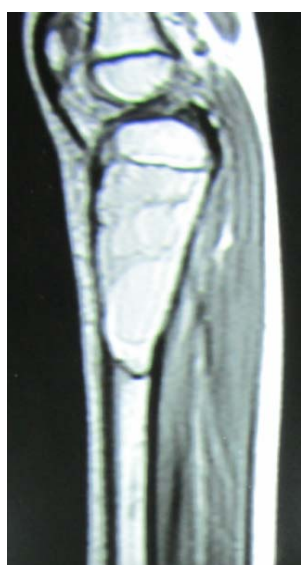

Figure 3. Sagittal view shows expansile centric, septated cystic lesion

The patient was admitted to orthopedics ward for open biopsy. Macroscopically, there was blood accompanied by epithelial lining without straw fluid or infective discharge. Histological examination revealed highly vascular thin membranous lining composed primarily of epithelium-like cells and giant cells accompanied with hemosiderin deposition (Figure.4).

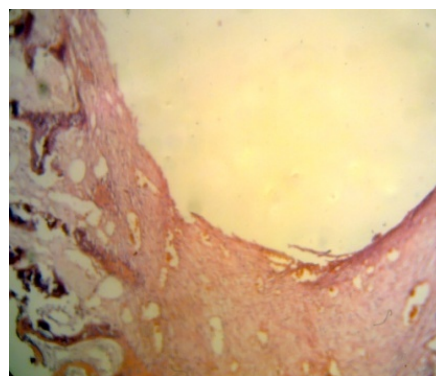


Figure 4. Histological examination shows highly vascular lining with giant cells and hemosiderin deposition

After confirmation of the diagnosis, the patient underwent curettage and grafted with bone substitute (Figure 5). The risk of progressive valgus deformity discussed with patient's parents thoroughly before proceeding with surgery and they were justified to be followed and evaluated postoperatively. At 3 months follow-up, the patient was asymptomatic and clinical examination was normal. The patient was able to walk without limping and pain.

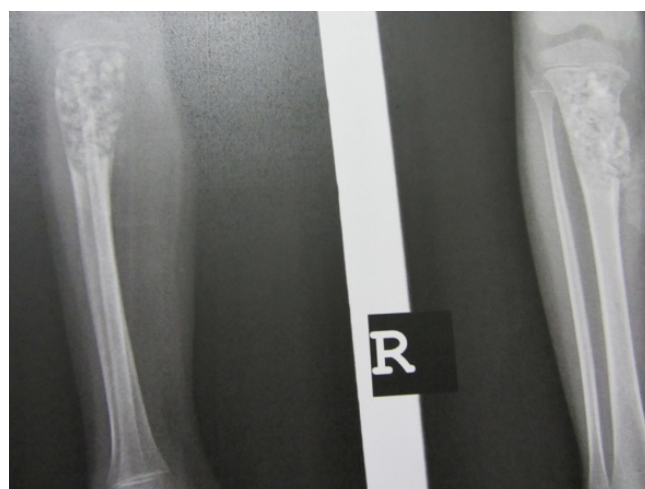

Figure 5. Curettage of lesion grafted with bone substitute

Discussion

Unicameral bone cysts (UBC) are benign, fluid-filled lesions which occur predominantly in children with average age of 9-11 years. The male-to-female ratio is 2-2.5 to 1.¹ 94% of UBCs occur in the proximal humerus and proximal femur, with the proximal humerus being affected 2-3 times more frequently than the proximal femur.² The remaining 6% occur in other bones including the calcaneus (2%), ilium (2%), talus, tibia, fibula, metatarsals, ischium, pubic rami, sacrum, vertebral bodies, forearm, and craniofacial bones.³ The exact incidence is difficult to determine as many lesions are silent prior to fracture.⁴ Although UBCs were first recognized by Virchow in 1876, the exact etiology remain unknown, however a number of etiologies have been proposed to explain UBC, such as venous obstruction, blocked drainage of interstitial fluid, invagination of synovial membrane, and traumatic hematoma with cystic resorption.^{5,6,7} Pain in the affected region may be present, but in approximately 70% of cases the first and only symptom is a pathological fracture following a trivial trauma.⁸

The radiological features on plain x-rays include a centrally located, expansile lesion of the metaphysis. Cortical thinning without disruption is seen.⁹ Fallen fragment sign is virtually pathognomonic of a multiloculated bone cyst.^{3,9} The growth plate moves away from the cyst as the child grows. This explains why two-thirds of these lesions are not in contact with the growth plate when discovered in children older than 10 years.⁹ In MRI, prolonged T1 and T2 relaxation times suggest a cyst, although T1 shortening may reflect proteinaceous content resulting in signal which is higher than water.¹⁰

Conflict of Interests

Authors have no conflict of interests.

Authors' Contributions

All authors planned and conducted the study procedure and wrote. All authors read and approved the final draft of the manuscript.

The most characteristic histopathologic finding is the thin membranous lining of the cyst, composed primarily of flattened to plump epithelium-like cells; the lining may also possess osteoclast-type giant cells, cholesterol cells and fat cells. Hemosiderin, fibrin, calcification, and reactive bone may be seen in focal areas of the cyst.¹¹

There is no consensus or official guideline for when and how to treat UBCs.¹² As Ahn et al.¹³ stated age, site, size, degree of loculation and cortical erosion, the stage of the cyst and whether it is active or not are all factors to be considered. There is a risk of recurrence in cysts which are lying within 2 centimeter of growth plate.¹⁴ Progressive tibia valga seem to be relatively common in patients younger than 10 years who have had curettage of the proximal tibial metaphysis.¹⁵

The major differential diagnoses include aneurysmal bone cysts, monostotic fibrous dysplasia, and atypical eosinophilic granuloma.¹⁶ All of these lesions may be radiolucent. However, features typically associated with these lesions usually help differentiate them from simple bone cysts.

Findings appear somewhat interesting but unusual characteristics of this case were female gender with low age (5 years), being painful although there was no cortical disruption in plain x-ray and MRI, rapid progression of the lytic lesion (in three months), and the site of lesion which unfortunately is accompanied by relative risk of tibia valga.

Acknowledgements

The authors thank Reza Tahririan MD, senior resident, department of pathology for reviewing the histopathological specimen and providing a photograph of it.

References

1. Zehetgruber H, Bittner B, Gruber D, Krepler P, Trieb K, Kotz R, et al. Prevalence of aneurysmal and solitary bone cysts in young patients. *Clin Orthop Relat Res* 2005; 439: 136-43.
2. Pireau N, De GA, Mainard-Simard L, Lascombes P, Docquier PL. Fracture risk in unicameral bone cyst. Is magnetic resonance imaging a better predictor than plain radiography? *Acta Orthop Belg* 2011; 77(2): 230-8.
3. Baig R, Eady JL. Unicameral (simple) bone cysts. *South Med J* 2006; 99(9): 966-76.
4. Milbrandt T, Hopkins J. Unicameral bone cysts: etiology and treatment. *Current Opinion in Orthopaedics* 2007; 18(6): 555-60.
5. Sung AD, Anderson ME, Zurakowski D, Hornicek FJ, Gebhardt MC. Unicameral bone cyst: a retrospective study of three surgical treatments. *Clin Orthop Relat Res* 2008; 466(10): 2519-26.
6. Cohen J. Simple bone cysts. Studies of cyst fluid in six cases with a theory of pathogenesis. *J Bone Joint Surg Am* 1960; 42-A: 609-16.
7. Davies AM, Sundaram M, James SJ. *Imaging of Bone Tumors and Tumor-Like Lesions*. New York: Springer; 2009. p. 426-9.
8. Glowacki M, Ignys-O'Byrne A, Ignys I, Mankowski P, Melzer P. Evaluation of volume and solitary bone cyst remodeling using conventional radiological examination. *Skeletal Radiol* 2010; 39(3): 251-9.
9. Plessis JD, Andronikou S, Hayes M, Mapukata A. Radiological features of simple (unicameral) bone cysts: case report. *SA Journal of Radiology* 2007; 11(3): 63-4.
10. Parman LM, Murphey MD. Alphabet soup: cystic lesions of bone. *Semin Musculoskelet Radiol* 2000; 4(1): 89-101.
11. Jaffe HL, Lichtenstein LL. Solitary unicameral bone cyst: with the emphasis on the roentgen picture, the pathologic appearance and the pathogenesis. *Arch Surg* 1942; 44(6): 1004-25.
12. Hou HY, Wu K, Wang CT, Chang SM, Lin WH, Yang RS. Treatment of unicameral bone cyst: a comparative study of selected techniques. *J Bone Joint Surg Am* 2010; 92(4): 855-62.
13. Ahn JI, Park JS. Pathological fractures secondary to unicameral bone cysts. *Int Orthop* 1994; 18(1): 20-2.
14. Haidar SG, Culliford DJ, Gent ED, Clarke NMP. Distance from the growth plate and Its relation to the outcome of unicameral bone cyst treatment. *Journal of Children's Orthopaedics* 2011; 5(2): 151-6.
15. Heck RK, Jr., Sawyer JR, Warner WC, Beaty JH. Progressive valgus deformity after curettage of benign lesions of the proximal tibia. *J Pediatr Orthop* 2008; 28(7): 757-60.
16. Campanacci M, Capanna R, Picci P. Unicameral and aneurysmal bone cysts. *Clin Orthop Relat Res* 1986; (204): 25-36.