

# Postoperative anatomic and functional results of homograft cartilage tympanoplasty

Farhad Mokhtarinejad<sup>1</sup>, Seyed Hamidreza Abtahi<sup>1</sup>, Shabnam Noei Alamdary<sup>2</sup>

<sup>1</sup> Assistant Professor, Department of Otolaryngology, School of Medicine, Isfahan University of Medical Sciences, Isfahan, Iran.

<sup>2</sup> Resident of Otolaryngology, Department of Otolaryngology, School of Medicine And Student Research Committee, Isfahan University of Medical Sciences, Isfahan, Iran.

**BACKGROUND:** One of the materials, which have been used to strengthen the graft in tympanoplasty, is cartilage. This clinical trial aimed to assess the anatomic and functional results of homograft cartilage tympanoplasty. **METHODS:** This clinical trial study was conducted on 40 patients who underwent homograft cartilage tympanoplasty between 2008 and 2011 in Al-Zahra Hospital, Isfahan, Iran. All patients were followed up one month after surgery for recurrent retraction pocket cholesteatoma and re-perforation of the tympanic membrane. Periodic follow up visits were done every 3 months and all patients were followed up at least six months after the surgery. The results of the surgery were determined by otoscopic examinations and audiometric tests. **RESULTS:** One month after the surgery, there were no cases of retraction pocket, adhesive otitis, recurrent cholesteatoma, membrane re-perforation and cartilage atrophy. 6 months after surgery 20 patients (50%) had a normal tympanic membrane, 15 patients (37.5%) had some degrees of cartilage atrophy that was not associated with pathologic changes, and 5 patients (12.5%) had retraction pocket. Re-perforation, recurrent cholesteatoma and adhesive otitis were not observed in any of the cases. **CONCLUSIONS:** The findings of this study demonstrated that homograft cartilage tympanoplasty is an effective technique for tympanic membrane closure and prevention of retraction pocket cholesteatoma with acceptable hearing results.

**KEYWORDS:** Cartilage Tympanoplasty, Homograft Cartilage, Chronic Otitis Media, Tympanic Membrane Perforation

## BACKGROUND

Atelectasis and retraction pockets result from gradual thinning and medialization of the tympanic membrane (TM) secondary to persistent negative middle ear pressure, primarily caused by Eustachian tube dysfunction.<sup>[1]</sup> Adhesive otitis describes the more severe form of atelectasis in which TM adheres to the promontory; this may cause ossicular erosion and cholesteatoma formation.<sup>[1]</sup>

Since Wullstein and Zoellner popularized tympanoplasty in the 1950s, various materials have been used for the procedure, including fascia, skin, vein, dura, and cartilage.<sup>[2]</sup> Currently, temporalis muscle fascia is the most frequently used grafting material in tympanoplasty,<sup>[3]</sup> but unfortunately in atelectatic ears the fascia and perichondrium have been shown to undergo atrophy and subsequent failure in the postoperative period. Thus, it would be better to choose a grafting material that can resist the continuous negative middle ear pressure. Cartilage might be a better choice than fascia to resist the negative middle ear pressure, because it is rigid and more stable.<sup>[4-6]</sup>

In this method of surgery, the patient's own tragal cartilage is mostly used. This method has

some limitations such as the small volume of cartilage, cartilage with unsuitable thickness and long duration time of surgery. Therefore, homograft cartilage is an alternative material. However, few studies have been carried out on this topic. There have been some concerns about immunologic response to homograft cartilage, and graft atrophy. This study aimed to assess the anatomic and functional results of homograft cartilage tympanoplasty.

Different techniques used in cartilage tympanoplasty are:

1. Palisade technique
2. Shield graft
3. In lay Butterfly graft
4. Island flap cartilage

Palisade technique was identified in 1962 by Heermann.<sup>[7]</sup> In this technique, cartilage pieces are placed in parallel form by malleus handle. In 2005 Sismanis, Robertson and Aidonis from Virginia University used pieces of chonca cartilage for tympanoplasty, which were extracted from two sides of cartilages perichondrium, and areolar tissue instead of fascia temporalis in order to cover the surface of cartilage and one media cartilage was attached to malleus handle and it was covered by areolar tissue. This method was called cartilage shield tympanoplasty.<sup>[7]</sup>

**Address for correspondence:** Shabnam Noei Alamdary, Resident of Otolaryngology, Department of Otolaryngology, School of Medicine And Student Research Committee, Isfahan University of Medical Sciences, Isfahan, Iran. E-mail: dr\_alamdary@gmail.com

**Received:** 18-12-2011; **Revised:** 25-01-2012; **Accepted:** 22-02-2012

In cartilage foils technique, cartilage pieces without perichondrium with 0.2-0.3mm thickness were used. Then, the foils were covered by fascia. These pieces can have various shapes and sizes, although normal tympan's thickness is 0.1mm and pieces are about 0.2-0.3mm. They are thicker than normal membrane, but the acoustic quality compared to normal membrane is not altered much.<sup>[7]</sup>

## METHODS

### *Participants and settings*

This clinical trial study was conducted on 40 patients who underwent tympanoplasty with homograft cartilage (nasal septum cartilage) between 2008 and 2011 in Al-Zahra University Hospital, Isfahan, Iran, with at least 6 months follow up.

The sampling method was convenience sampling and participants were comprised of patients who were hospitalized with chronic otitis media and underwent homograft cartilage tympanoplasty. The inclusion criteria were recurrent perforation in tympanic membrane, membrane retraction pocket, severe atelectasis and middle ear intact canal cholesteatoma surgery. Patients who refused to come for the follow up visits were excluded.

The study protocol was approved by the Ethics Committee of the School of Medicine, Isfahan University of Medical Sciences (proposal registration number: 389259) and informed consents were obtained from all patients after explaining the study protocol and aims.

According to the FDA standard we used septal cartilage of patients who had negative serologic tests for HBS Ag, HCV Ab, HIV- Ab and underwent nasal septoplasty surgery.<sup>[8]</sup> The cartilages were kept inside alcohol and were used as homograft cartilage.

All patients were operated under general anesthesia by the first author (FM) and the post auricular approach was used in the surgery. Temporal muscle fascia was also harvested at the beginning of the operation, and this fascia was laid on the cartilage at the end of the operation in order to cover unwanted small openings between the slices and to improve the healing process. The perichondrium had been removed from two sides of the cartilage. The cartilage was then cut into several pieces to be used as fold grafts (with 0.2-0.3mm thickness). In some patients we used only one larger piece of cartilage, lateral to malleus as a shield graft.

Gelfoam was placed medial to the graft for stabiliza-

tion and the temporal muscle fascia, harvested at the beginning of the operation, was also laid on the cartilage pieces to improve the healing process. The wound was closed in two layers, and a mastoid dressing was applied.

Assessment included otoscopic examination and auditory tests; it was conducted before the surgery and was repeated one month and every three months after the surgery (at least six months after surgery). Post operative complications included retraction pocket, recurrent cholesteatoma, recurrent tympanic membrane perforation and cartilage atrophy were studied. In the follow up otoscopic examination, in cases that we could not see at least 1.3 of the cartilage or cartilage had become completely soft, have been considered as cartilage atrophy.

### *Statistical Analysis*

The data were analyzed with SPSS for Windows (version 18, SPSS, Chicago, IL), using t-test, Fisher exact test, and repeated measures analysis of variance (ANOVA). The descriptive data were presented as mean  $\pm$  standard deviation (SD). A P-value of  $< 0.05$  was considered statistically significance for analyses.

## RESULTS

There were 40 patients in this study, these patients underwent tympanoplasty with homograft cartilage and their follow up period was at least 6 months and at most 3 years. The mean age of the patients was 32.5 years (SD = 13.8, range: 8-68 years). 11 (27.5%) patients were male and 29 (72.5%) were female.

The pre-operative findings that had been considered as surgical indications are presented in figure 1. According to the diagram retraction pocket was observed in 13 patients (32.5%); in 7 of these patients (17.5%) only this symptom was observed, but in the other 6 patients (15%) other symptoms were also present. Adhesive otitis was observed in 9 patients (22.5%); in 2 of them (5%) only this symptom was present, but in the other 7 patients (17.5%) other symptoms were also present. Cholesteatoma was observed in 23 patients (57.5%) and 16 of them (40%) also had other symptom. Finally, recurrent tympanic membrane perforation (after one operation) was seen in 5 patients (12.5%).

Intact ossicular chain was observed in 6 patients (15%) but 34 (85%) suffered from ossicular erosion. The applied technique in 21 (52.5%) patients was shield graft, and in the others it was cartilage foils technique. The mean duration of follow up was 20.3 months (SD = 9.4, range: 6-34 months)

By tympanometry test, 11 (27.5%) patients had type A tympanogram, 25 (62.5%) had type B and 4 (10%) had type C tympanogram. One month after the surgery, all the patients were followed up. Retraction pocket, adhesive otitis, recurrent cholesteatoma, tympanic membrane perforation and cartilage atrophy were not seen in any patient. At least 6 months after surgery tympanic membrane in 20 (50%) patients was normal. The mean follow up duration was 17.9 months (SD = 8.8, range: 6-33). (Figure 2).

15 (37.5%) patients had some levels of cartilage atrophy without any pathologic changes. The mean follow up duration was 20.8 months (SD = 9.9, range: 6-34).

Recurrent retraction pocket was seen in 5 patients (12.5%) that in 3 of them (7.5%) was in anterosuperior part of the tympanic membrane, originating from technical defects, and in 2 (5%) was in posterosuperior part of the membrane. The mean follow up duration was 28.2 months (SD = 4.4). According to one way ANOVA, the mean follow up duration in 3 groups (patients by normal tympanic membrane, cartilage atrophy and retraction pocket) was not statistically significant ( $p = 0.084$ ).

Cartilage atrophy was seen in 9 patients (42.9%) with shield graft and in 6 patients (31.6%) with cartilage foils and according to Fisher exact test, there was no statistical difference between these 2 kinds of techniques ( $p = 0.38$ ).

According to the paired t-test, the mean of hearing thresholds in the air and bone transmission, before and after surgery was not statistically different ( $p > 0.05$ ).

Out of 40 patients, 25 (62.5%) had healthy stapes and 15 (37.5%) did not have this ossicle.

The mean pure-tone average air-bone gap (PTA-ABG) in 500, 1000 and 2000 frequencies in the group with intact stapes, before and after surgery was 29.3 (SD = 11.4) and 21.2 (SD = 14.6), respectively. Therefore, statistical improvement was obtained in hearing thresholds ( $p = 0.02$ ).

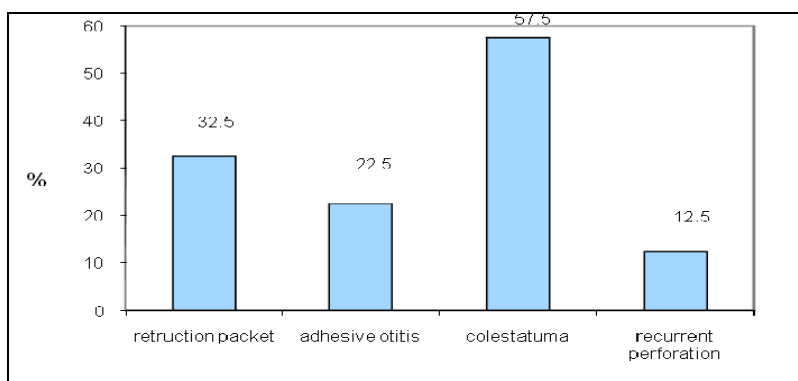
The same improvement on speech reception threshold (SRT) was also observed and the mean of hearing thresholds changed from 55.8 db (SD = 14.4) to 46.4 db (SD = 20.9). The difference between preoperative and postoperative thresholds, was statistically significant ( $p = 0.01$ ) (Table 1).

In the group of patients without stapes ossicle, the mean of ABG, preoperative and postoperative was 35.8 (SD=13.3) and 29.7 (SD= 12.3), respectively. There was no significant difference between these two groups in ABG ( $p = 0.24$ ) and no considerable improvement was observed. The mean of preoperative and postoperative SRT in patients without stapes was 63.2 (SD = 17) and 66.7 (SD = 17.5), respectively. No significant difference was seen between preoperative and postoperative SRT ( $p = 0.57$ ) (Chart 1).

**Table 1. Comparison of preoperative and postoperative ABG and SRT**

Variables	Stapes status	Preoperative	Postoperative	P-value
ABG	Intact stapes	29.3 ± 11.4	21.2 ± 14.6	0.02
	Without stapes	25.8 ± 12.3	29.7 ± 12.3	NS
SRT	Intact stapes	55.8 ± 14.4	46.4 ± 20.9	0.01
	Without stapes	63.2 ± 17	66.7 ± 17.5	NS

ABG: air-bone gap; SRT: speech reception threshold; Ns: not significant



**Figure 1. Frequency distribution of pathologic findings in preoperative examination**

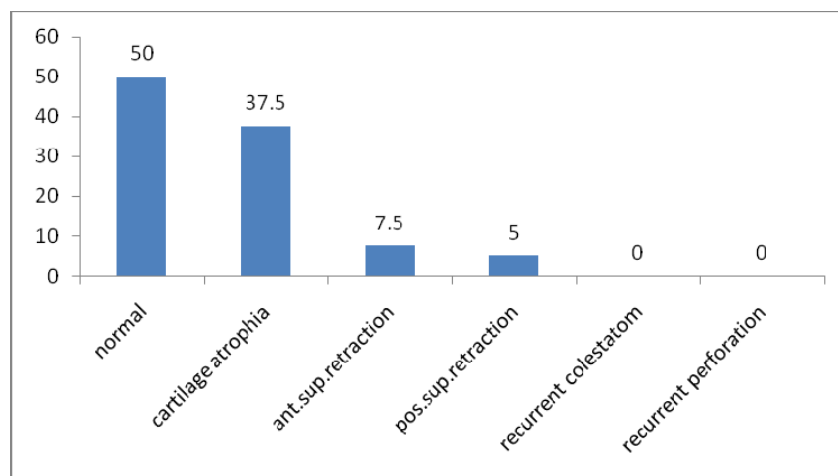


Figure 2. Frequency distribution of the complications, 6 months after surgery

## DISCUSSION

In our study, in the intact stapes group, there was a significant difference in the mean of pure-tone average air-bone gap (PTA-ABG), before and after surgery.

One month after surgery, there were no cases of retraction pocket, adhesive otitis, recurrent cholesteatoma, membrane re-perforation and cartilage atrophy. 6 months after surgery 20 patients (50%) had a normal tympanic membrane, 15 patients (37.5%) had some degrees of cartilage atrophy, which were not associated with pathologic changes, and 5 patients (12.5%) had retraction pocket. Re-perforation, recurrent cholesteatoma and adhesive otitis were not considered in any cases.

In the study by Ozbek et al., the mean follow up period was  $44.5 \pm 8.0$  months (range, 36–68 months). Closure of the tympanic membrane was achieved in 91% of ears. Otomicroscopic evaluation revealed nine (16%) mild and five (8%) moderate retractions, but none of the retractions was deep enough to necessitate tube placement. Postoperative PTA-ABG was less than 20 dB in 71% of ears.<sup>[1]</sup>

In the study by Dornhoffer, the mean of ABG before and after tympanoplasty with Homograft cartilage was similar to our study.<sup>[2]</sup>

Hashemi et al., in Shiraz University, reported the mean of SRT and air bone gap (ABG) in 4 frequencies of 500, 1000, 2000 and 4000 in patients who had undergone tympanoplasty to be 17, 15, 15 and 18 with Perichondrium-cartilage and 19, 18, 19 and 23 with fascia.<sup>[9]</sup>

One year after surgery the mean of SRT was 17.9 db (SD = 2) in the group with perichondrium –cartilage

graft and 20.6 db (SD = 2) in the group with fascia graft with obvious improvement in hearing in long-term follow up. Finally, patients who had undergone tympanoplasty with fascia benefited from more improvements in hearing than those who did tympanoplasty by cartilage. Moreover, the comparison between the two groups showed no statistical difference between them.<sup>[9]</sup>

In 2006 B. Morra studied 383 patients who had undergone tympanoplasty with autograft cartilage foils. He reported that 4.2% had recurrent perforation and 5% had recurrent cholesteatoma. The mean of preoperative and postoperative ABG in four frequencies (0.5-3 KHZ) was 29.2 db (SD = 12.2), and 16.3 db (SD = 9.9). Anatomic and functional results were both good.<sup>[7]</sup>

In a study done by Kirazli, 25 patients, who had undergone tympanoplasty with cartilage, were compared with 10 patients with fascia graft and no significant difference was seen.<sup>[10]</sup>

Of course, most of the mentioned studies have been conducted in tympanoplasty with autograft cartilage, and not many studies have been done on the homograft cartilage tympanoplasty.

The main limitation of this study was several follow up visits.

## CONCLUSIONS

The findings of this study demonstrated that homograft cartilage tympanoplasty is an effective technique for tympanic membrane closure and prevention of retraction pocket cholesteatoma with acceptable hearing results.

## ACKNOWLEDGEMENTS

This paper is derived from a specialty thesis in Isfahan University of Medical Sciences.

## REFERENCES

1. Ozbek C, Ciftci O, Ozdem C. Long-term anatomic and functional results of cartilage tympanoplasty in atelectatic ears. *Eur Arch Otorhinolaryngol* 2010; 267(4): 507-13.
2. Dornhoffer J. Cartilage tympanoplasty: indications, techniques, and outcomes in a 1,000-patient series. *Laryngoscope* 2003; 113(11): 1844-56.
3. Amedee RG, Mann WJ, Riechelmann H. Cartilage palisade tympanoplasty. *Am J Otol* 1989; 10(6): 447-50.
4. Duckert LG, Muller J, Makielski KH, Helms J. Composite autograft "shield" reconstruction of remnant tympanic membranes. *Am J Otol* 1995; 16(1): 21-6.
5. Luetje CM. Saddle blanket graft tympanoplasty and lateral attic wall reconstruction for defects produced by primary acquired cholesteatoma. *Laryngoscope* 2001; 111(8): 1497-9.
6. Page C, Charlet L, Strunski V. Cartilage tympanoplasty: postoperative functional results. *Eur Arch Otorhinolaryngol* 2008; 265(10): 1195-8.
7. Tos M. *Cartilage Tympanoplasty*. 1<sup>st</sup> ed. (2009). New York: Thieme; 2009: 7, 147.
8. Humphries LK, Mansavage VL. Quality control in tissue banking--ensuring the safety of allograft tissues. *AORN J* 2006; 84(3): 386-8.
9. Hashemi SB, Sohrabi H, Omranifard H. Comparison of tympanoplasty results with use of perichondrium- cartilage and temporalis fascia. *The Iranian Journal of Otorhinolaryngology* 2009; 21(56): 63-6.
10. Kirazli T, Bilgen C, Midilli R, Ogut F. Hearing results after primary cartilage tympanoplasty with island technique. *Otolaryngol Head Neck Surg* 2005; 132(6): 933-7.

**How to cite this article:** Mokhtarinejad F, Abtahi SH, Noei Alamdary Sh. Postoperative anatomic and functional results of homograft cartilage tympanoplasty. *J Res Med Sci* 2012; 17(Spec 1): S120-S124.

**Source of Support:**, **Conflict of Interest:** Authors have no conflict of interest.