

Original Article**Operative compared to non-operative treatment of displaced intra-articular calcaneal fractures ***Mohammad Hadi Nouraei¹, Farhad Mostafa Moosa²**Abstract**

BACKGROUND: The aim of this study was to compare outcomes of open reduction and rigid internal fixation of displaced calcaneal fractures with that of non operative treatment.

METHODS: Seventy two consecutive patients with displaced intra-articular calcaneal fractures were selected regarding inclusive and exclusive criteria and then were randomly allocated to surgical and non surgical groups. First group underwent open reduction and internal fixation with reconstruction plate and screws fixation and the other group were treated with closed reduction and cast immobilization. Data were collected by clinical observation and a check list. Data was analyzed by chi-square and student's t-test.

RESULTS: The results showed significant difference between outcomes of surgical treatment and nonsurgical method ($p = 0.001$). There were some differences between two methods in terms of decreasing pain [Odd Ratio (OR): 6.72, $p = 0.001$], swelling (OR: 6.80, $p = 0.001$), increased range of motion of the joints ($p = 0.001$), decreased late osteoarthritis (OR: 2.33, $p = 0.22$) in favor of surgical group.

CONCLUSIONS: Open reduction and internal fixation of displaced calcaneal fractures in absence of open fracture, severe osteoporosis, or comminution, poor general condition may be the preferred method of treatment.

KEYWORDS: Calcaneal Fracture, Reconstruction Plate, Rigid Internal Fixation, Open Reduction.

J Res Med Sci 2011; 16(8): 1014-1019

Incidence of calcaneal fractures is highly increasing due to falling from height, motor and car accidents.^{1, 2} Because of many complications and handicaps after these fractures, there is a need for new attention to prevent these disabilities.^{1, 3, 4} High velocity trauma including car accidents and falling is the major cause of calcaneal Fractures.¹⁻⁴ 75% of calcaneal fractures are intra-articular and 25% are extra-articular.¹ As a rule, treatment of displaced intra-articular fractures is by open reduction and rigid internal fixation.²⁻⁴ Calcaneal fractures include two percent of adult fractures and 60% of tarsal fractures.^{1, 5}

Most of calcaneal fractures are in young adult men.^{1, 6-8} Axial load in falling is the most common mechanism of fractures. In such me-

chanism, talus is forced downward and excessive load will fail calcaneus and reduces Bohler angle.¹ Using computerized tomography (C.T. scanning), Sander classified calcaneal fractures in four groups according to the fracture lines, medial, lateral and central body of calcaneus and subtalar joint involvement (Figure 1).⁶⁻⁹

Goals of treatment of calcaneal fractures are:

1. Restoration of congruency of the posterior facet of subtalar joint (Figure 2).
2. Restoration of the height of the calcaneus (Bohler angle).
3. Reduction of the width of the calcaneus (Figure 3).
4. Decompression of the subfibular space available for peroneal tendons.

* This Paper derived from a Specialty thesis in Isfahan University of Medical Sciences.

1- Assistant Professor, Department of Orthopaedic Surgery, School of Medicine, Isfahan University of Medical Sciences, Isfahan, Iran.

2- Resident, Department of Orthopaedic Surgery, School of Medicine And Student Research Committee, Isfahan University of Medical Sciences, Isfahan, Iran.

Corresponding Author: Mohammad Hadi Nouraei

E-mail: nouraei@med.mui.ac.ir

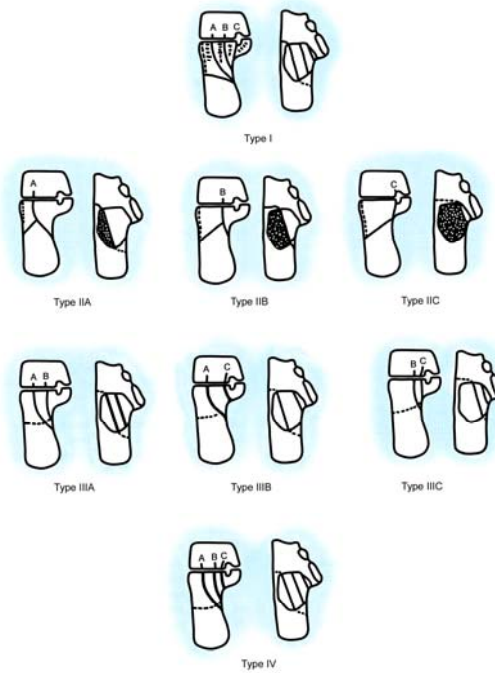


Figure 1. Sander's classification of calcaneal fractures

5. Realignment of the tuberosity fragment into normal valgus position.
6. Reduction of the calcaneo-cuboid joint, if fractured.^{1, 10}

Although there have been some research evidences showing open reduction is preferred method for treating calcaneal fractures, majority of orthopedic surgeons are clinically ambivalent to use this procedure because of some complications such as post operative infections, wound dehiscence, malreductions and long term osteoarthritis.

Methods

This study was a controlled clinical trial aiming to compare the outcomes of open reduction and rigid internal fixation of displaced calcaneal fractures with that of non operative treatment. The research proposal of this study was approved by research department of Isfahan University of Medical Sciences. Also the protocol of study was approved by ethical committee. During ten years, from December 1998 until January 2009, 72 patients with displaced intra-articular calcaneal fractures

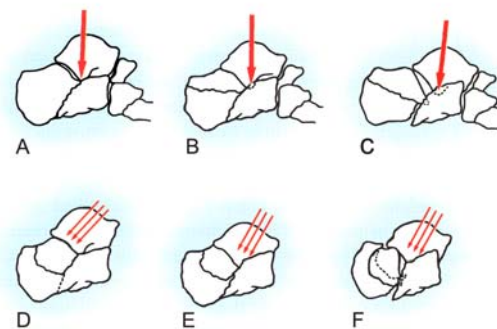


Figure 2. Radiologic classification and mechanism of fractures

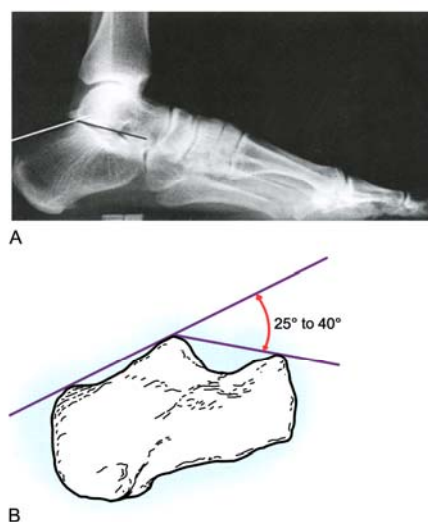


Figure 3. Normal Bohler Angle

admitted in Kashani University Hospital and were randomly allocated to surgical and non surgical groups. First group underwent open reduction and internal fixation with reconstruction plate and screws fixation and the other group were treated with closed reduction and cast immobilization.¹⁻³ Data were collected by clinical observation and a questionnaire six months following surgery.

Some reasons that patients were not selected for surgery were as follows: patient disagreement with surgery, open fractures (not suitable for open reduction internal fixation), combined injuries (Head trauma, cardiovascular disorders, severe osteoporosis...) also were not suitable for surgery^{1, 7-9} and severe comminution.

Post-operative exam after two weeks, one month, three months, six months and one year was recorded. The questionnaire was completed just after 6 months. Roentgenography was obtained and physical examination including pain scoring, swelling, limitation of activities, shoe wearing difficulties, range of motion and osteoarthritis in ankle and subtalar joints as well as patient satisfaction were also scored and recorded. Functional scoring based on Kerr's meta-analysis and pain scoring was used.¹¹⁻²¹ Data were analyzed by SPSS 18 software. The chi-square test was used.

Results

Seventy two patients with mean age 49 years (21-84 years old) were included. Eleven patients were excluded from the study (Unable to follow up after Hospital discharge). Eventually, 61 cases of calcaneal fractures enrolled and were also followed-up for averagely 3 years. Thirty one patients underwent operation and 30 cases had conservative treatment. Patients in operation group sub-classified in two categories: First group comprised of 17 cases with Essex-Lopresti technique (under fluoroscopy-X-ray control, closed reduction, internally fixed with pin fixation, and cast immobilization).²² Second group consisted of 14 cases with open reduction with lateral calcaneal approach and fixation with reconstruction plate (Figure 4). All patients in surgery group received intravenous antibiotic 2-4 days after operation. Ambulation with crutch walking and non-weight bearing continued for 6-10 weeks after surgery.

Thirty cases had non-surgical treatment, with splinting, ice pack, elevation the limb, then short leg cast and ambulation with crutch walking and non weight bearing. In non-surgery group ambulation with crutches started 3 days after casting and cast was removed after 6 weeks and physical therapy,

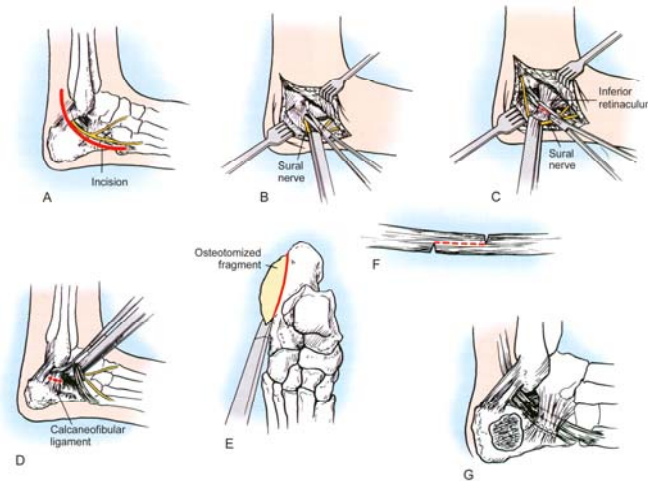


Figure 4. Lateral calcaneal approach with exostosectomy

home exercises and partial weight bearing was recommended.

Bilateral calcaneal fractures were detected in 11 patients. Non of surgically treated patients had post operative infection. The findings regarding the comparison between two groups for different variables are shown in Table 1.

In post operation examinations, range of motion of ankle in both groups were good (more than 50% of R.O.M) but in subtalar joints decreased range of motion in non-operative group compared to operative group was obtained (Odds Ratio: 6.75, $p = 0.002$). Last x-Ray examinations showed that traumatic osteoarthritis (Degenerative Joint Disease) in non-operative group was a major problem (26% compared to 9% in operative group). Shoe fitting difficulties was also a major problem (50% in non-operative compared with 12% in operative group).¹⁸

Pain in walking was 63% in conservative

group compared to 29% in operative group (Odds Ratio: 6.72, $p = 0.001$).^{21, 22} Swelling in ankle and foot, reflex sympathetic dystrophy including focal osteoporosis and-or spotty osteoporosis in non operative group was twice more than operative group (6 cases versus 3 cases; Odds Ratio: 6.80, $p = 0.001$) (Table 2).

Discussion

Our findings showed that open reduction and internal fixation of displaced calcaneal fractures in absence of open fracture, severe osteoporosis, or comminution and poor general condition may be the preferred method of treatment. Although surgical treatment of calcaneal fractures has recently received attention owing to good results and less morbidities,^{1-3, 9-11} most of orthopaedic surgeons prefer to treat them conservatively, probably because of many complications including post operative

Table 1. Fracture classification (Sander’s)

Number	Operative treated	Non operative treated	Total
	31 cases	30 cases	61 cases
age (years) mean ± SD	46 ± 8.2	52 ± 12.3	49 ± 10.5
Return to work after injury	6 months	8 months	7 months
Sander's classification	I = 1	I = 5	I = 6 cases
	II = 20	II = 8	II = 28 cases
	III = 8	III = 8	III = 16 cases
	IV = 2	IV = 5	IV = 7 case
	Sever comminution = 0	Comminution = 4 cases	Severs comminution = 4 cases

Table 2. Treatment outcomes

Item	Operative group	Non operative group	Total
Number of cases	31 cases	30 cases	61 cases
Decreased Range of motion (More than 50%)	Ankle: none	Ankle: none	none
	Subtalar: 6 cases	Subtalar: 10 cases	16 cases
Last X Ray: traumatic osteoarthritis (D.J.D)	3 cases	8 cases	11 cases
Joint narrowing	3 cases	8 cases	11 cases
Spur formation	2 cases	3 cases	5 cases
Metaphyseal cyst	1 cases	2 cases	3 cases
Increased width of heel (more than 10 mm)	4 cases	15 cases	19 cases
Pain (in walking)	9 cases	22 cases	31 cases
Shoe fitting difficulties	4 cases	15 cases	19 cases
Swelling: Ankle	6 cases	12 cases	20 cases
Foot	Non	5 cases	
R.S.D (Reflex Sympathetic Dystrophy)	3 cases	6 cases	9 cases

infections, wound dehiscence, malreductions and long term osteoarthritis. Most of calcaneal fractures are intra-articular and displaced. On the other hand, many of these fractures have ecchymosis, swelling, and blister which increase risk of open reduction and internal fixations (fracture- blister).¹⁴

Thornes et al.¹⁵ showed that surgically treated calcaneal fractures have better prognosis compared with those conservatively treated. Burdeaux's work also showed that shoe fitting and weight bearing difficulties were less in those underwent operation.¹⁶ Pain in daily living activities were dramatically less in patients with open reduction and internal

fixation, and range of motion in ankle and subtalar joints were desirable.¹⁷⁻²⁰

Conclusion

Open reduction and internal fixation of displaced calcaneal fractures in absence of open fracture, severe osteoporosis, or comminution, poor general condition may be the preferred method of treatment. Young and middle aged patients with calcaneal fracture who are in Sander's type II and III with mild comminution due to minor trauma, without soft tissue injuries may be the best candidates for open reduction and internal fixation.

Conflict of Interests

Authors have no conflict of interests.

Authors' Contributions

MHN and FMM participated in the design study, conduct the study and prepared the manuscript. Both authors read and approved the final manuscript.

References

1. Canale ST, Beaty JH. Campbell's Operative Orthopaedics. 11th ed. Philadelphia: Mosby; 2008. p. 4833-51.
2. Cohen M. Calcaneal Fractures. Foot and Ankle Surgery 2001; 2: 1819-63.
3. Juliano P, Nguyen HV. Fractures of the Calcaneus. Orthopedic Clinics of North America 2001; 32(1): 35-51.
4. Myerson M. Fractures of the Hind foot. In: Myerson M, editor. Foot and ankle disorders. Philadelphia: Saunders; 2000. p. 1297-340.

5. Buckley R, Tough S, McCormack R, Pate G, Leighton R, Petrie D, et al. Operative compared with nonoperative treatment of displaced intra-articular calcaneal fractures: a prospective, randomized, controlled multicenter trial. *J Bone Joint Surg Am* 2002; 84-A(10): 1733-44.
6. Sanders R, Fortin P, DiPasquale T, Walling A. Operative treatment in 120 displaced intraarticular calcaneal fractures. Results using a prognostic computed tomography scan classification. *Clin Orthop Relat Res* 1993; (290): 87-95.
7. Sanders R, Hansen ST, McReynolds IS. Trauma to the calcaneus and its tendon. Fracture of the calcaneus. *Disorders of the Foot and Ankle* 1991; 1: 2326-45.
8. Sanders R. Fractures and fracture-dislocations of the calcaneus. *Surgery of the Foot and Ankle* 1999; 2: 1422-64.
9. Sanders R. Intra-articular fractures of the calcaneus: present state of the art. *J Orthop Trauma* 1992; 6(2): 252-65.
10. Bohler L. Diagnosis, pathology, and treatment of fractures of the calcaneus. *J Bone Joint Surg* 1931; 13: 75-89.
11. Kerr PS, Prothero DL, Atkins RM. Assessing outcome following calcaneal fracture: a rational scoring system. *Injury* 1996; 27(1): 35-8.
12. Randle JA, Kreder HJ, Stephen D, Williams J, Jaglal S, Hu R. Should calcaneal fractures be treated surgically? A meta-analysis. *Clin Orthop Relat Res* 2000; (377): 217-27.
13. Pozo JL, Kirwan EO, Jackson AM. The long-term results of conservative management of severely displaced fractures of the calcaneus. *J Bone Joint Surg Br* 1984; 66(3): 386-90.
14. Varela CD, Vaughan TK, Carr JB, Slemmons BK. Fracture blisters: clinical and pathological aspects. *J Orthop Trauma* 1993; 7(5): 417-27.
15. Thornes BS, Collins AL, Timlin M, Corrigan J. Outcome of calcaneal fractures treated operatively and non-operatively. the effect of litigation on outcomes. *Ir J Med Sci* 2002; 171(3): 155-7.
16. Burdeaux BD, Jr. Fractures of the calcaneus: open reduction and internal fixation from the medial side a 21-year prospective study. *Foot Ankle Int* 1997; 18(11): 685-92.
17. Dooley P, Buckley R, Tough S, McCormack B, Pate G, Leighton R, et al. Bilateral calcaneal fractures: operative versus nonoperative treatment. *Foot Ankle Int* 2004; 25(2): 47-52.
18. Asik M, Sen C, Bilen FE, Hamzaoglu A. [Surgical management of intraarticular calcaneus fractures]. *Acta Orthop Traumatol Turc* 2002; 36(1): 35-41.
19. Campbell JT. Intra-articular neuropathic fracture of the calcaneal body treated by open reduction and subtalar arthrodesis. *Foot Ankle Int* 2001; 22(5): 440-4.
20. Koski A, Kuokkanen H, Tukiainen E. Postoperative wound complications after internal fixation of closed calcaneal fractures: a retrospective analysis of 126 consecutive patients with 148 fractures. *Scand J Surg* 2005; 94(3): 243-5.
21. Kennedy JG, Jan WM, McGuinness AJ, Barry K, Curtin J, Cashman WF, et al. An outcomes assessment of intra-articular calcaneal fractures, using patient and physician's assessment profiles. *Injury* 2003; 34(12): 932-6.
22. Essex-Lopresti P. The mechanism, reduction technique, and results in fractures of the os calcis, 1951-52. *Clin Orthop Relat Res* 1993; (290): 3-16.