

Short Communication**Biological plating of comminuted fractures of femur and tibia***Mohammad Javdan*, Ali Andalib**, Farinaz Fattahi******Abstract**

BACKGROUND: The treatment of comminuted fractures in long bones has continued to be a problem in orthopedic surgery. Recently, fixation without exploration of the fracture site, known as "biologic fixation", has been introduced. This study was performed to assess the results and complications of this method for the treatment of comminuted fractures of the tibia and femur.

METHODS: The study included 41 patients with comminuted fractures of the tibia and femur treated with biologic plating from 2003 to 2006 (25 femur fractures and 16 tibial fractures). After biological fixation joint motion was started but weight bearing was avoided until radiographic evidence of union was shown.

RESULTS: The mean time of union in the tibial fractures was 19 ± 2 weeks and 17 ± 2 weeks for the femur fractures. All patients had fracture union without any infection, non-union or implant failure. In one patient with a femur fracture there was a 10° internal rotation deformity. Two of the femoral fractures had shortening of 1 cm, and one patient had shortening of about 2 cm. Compared to similar studies, all results were statistically significant ($P < 0.05$).

CONCLUSIONS: The biologic plating method is a safe, simple and effective method of fixation for comminuted fractures of long bones. It has a high rate of union with minimal complications.

KEY WORDS: Biological fixation, plate, comminuted fracture.

JRMS 2007; 12(4): 186-189

The treatment of comminuted fractures of long bones has continued to be a problem in orthopedic surgery¹. High energy trauma causes endosteal blood flow damages¹. Periosteal blood flow damage, one of the main sources of blood flow in bones with comminuted fractures, is caused by the usual 'ORIF' method of separation of periosteum and bone, as well as the usage of lag screws and bone clamps^{2,3}. The usual methods of treatment in comminuted fractures are as follow: 1) classic fixation, 2) biological fixation, 3) intramedullary nailing, 4) pin and plaster, 5) external fixators. Although interlocking intra-medullary nailing is known as the golden treatment in comminuted

fractures, there are limitations within this modality. For instance:

1. It is not useful in diaphyseal fractures with spreading into metaphysis and joint.
2. Open growth plates in children makes the intramedullary nailing impossible.
3. The intramedullary nailing with interlocking usually needs special surgical tools (such as c-arm and orthopedic beds) which are not accessible in all surgery centers.
4. The duration of surgery for this method is long and not suitable for patients with time limitations. This method is also high-risk.
- 5-Problems in union, caused by lack of enough compression due to interlocking and sometimes it is necessary to use dynamization.

*Assistant Professor of Orthopedics, Isfahan University of Medical Sciences, Isfahan, Iran.

**Resident of Orthopedics. Isfahan University of Medical Sciences, Isfahan, Iran. e-mail: ali_andalib@yahoo.com (Corresponding Author)

***Medical Student. Isfahan University of Medical Sciences, Isfahan, Iran.

The advantages of indirect reduction and biological fixation are:

1. Soft tissue remains intact.
2. Correct alignment, length and rotation of the extremity remain intact.
3. There is some mobility in the fracture zone⁴ which accelerates the callus formation⁵.
4. With the average duration of surgery being two hours, the average reported blood loss with biological fixation will be 740 ml⁶.

Because of these advantages it is necessary for surgeons to use the biological fixation method as well as the intramedullary nailing.

Methods

All the patients admitted to Al- Zahra and Kashani hospitals from 2003 to 2006 with comminuted closed and open fractures type I in either femur or tibia and also intramedullary nailing was not technically possible or was contraindicated were included in the study. The total number of admitted patients in the given period was 50, of whom 9 were excluded for not being able to be followed up. Therefore, the total number of patients was 41 (36 males and 5 females), of whom 16 had tibial fractures and 25 had femur fractures. The mean age of patients with femoral fractures was 28.1 years, and in tibial fractures was 26.8 years. The femoral fractures were fixed by dynamic hip screw (DHS), dynamic compression screw (DCS) and dynamic compression plate (DCP), and the tibial fractures were fixed by DCP and T-PLATES. All surgeries were completed with the same surgical team. Prior to surgery, traction was applied for all cases with bone displacement in close reduction. In tibial fractures, which needed less traction, the traction was given by the assistant but in femur fractures, a fracture table was used. After traction, the biologic plate was sent downward from a small incision of about 4-5 cm length proximal to the fracture site, and was exposed from another incision of about 4-5 cm distal to the fracture site. After fixation of the proximal zone; the appropriate traction was given (figure 1). To avoid length variations, the length of extremity was measured and compared with the

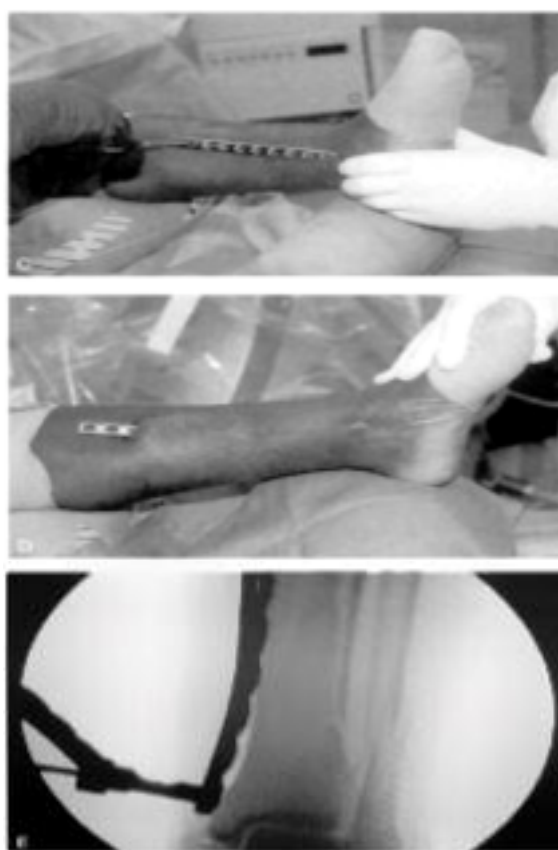


Figure 1. The incision site for the insertion of the plate.

healthy limb, during the surgery⁵. All the surgeries have been done with the same surgery team. In cases with intra-articular fractures or metaphyseal fractures with spreading into diaphysis, we began by fixing the intra-articular fracture with open reduction and internal fixation, (ORIF). Then, the plate was sent from metaphysis to the diaphysis. The exact reduction of the intra-articular fractions has a very important role in prevention from further osteoarthritis. In sub-trochanteric, inter-trochanteric comminuted fractures, or supra-condylar fractures with spreading into diaphysis, we began by inserting the nail in the neck (or condyle) of the femur, and then sent the side plate downward (or upward) and fixed it to the bone. The most important practical points in this surgery were as follow:

1. The reduction should be in a way that the fractured parts have the same rotation. This is

simple in tibial fractures but in femoral fractures needs more practice.

2. The traction should prevent length variations.

3. In tibia comminuted fractures associated with fibula fractures first fix the fibula with plate or other implants in order to prevent length variations.

After fixing the plate we inserted drain in the wound and sutured the wounds in different layers. After 2 days the drain was discharged and movement of the foot and knee joints began. Three days after surgery all cases were permitted to walk with walkers but weight bearing was forbidden until the union was complete.

Results

The total number of patients in this study was 41 (36 males and 5 females), of whom 16 had tibial fractures and 25 had femoral fractures. Distribution frequency of fixation tools according to pattern of fractures is located in table 1. The mean age of patients with femur and tibial fractures was 28.1 and 26.8 years respectively. The mean time of follow up was 22 weeks (17-45 weeks). In all cases union was completed. The mean time of union in femur fractures was 17 ± 2 weeks and in tibial fractures was 19 ± 2 weeks (figure 2). There were no wound infections, fistula or the need for secondary surgery due to non-union or implant failure. The mean of hip flexion after treatment was 130 degrees. The mean degree of knee flexion in both groups was 125° , and in only 3 patients with femur fracture the ROM of hip was limited in terminal 30° . Two patients had limitations in knee flexion which was improved with physiotherapy. There was no limitation in the extension of the knee and hip. Flexion and dorsiflexion of the foot was intact. In tibial fractures there was no malunion. In one femur fracture there was a 10° internal rotation deformity. Two femur fractures faced shortening of about 1cm. One femur fracture had 2 cm shortening which was caused by great bone defect from shooting. There was no shortening in tibial fractures. In comparison with other similar

studies all the results were statistically significant ($P < 0.05$).

Table 1. Distributing frequency of fixation tools according to pattern of fractures.

Pattern of fractures	Fixation tool	Number of patients
Subtrochanteric-intertrochanteric comminuted fractures of femur with / without spreading into diaphysis	DHS	15
Diaphyseal comminuted fractures of femur	DCP of femur	8
Supracondylar comminuted fractures of femur	DCS	2
Metaphyseal fractures of tibia with spreading into diaphysis	T-PLATE	3
Segmental/comminuted fractures of tibia	DCP of tibia	13

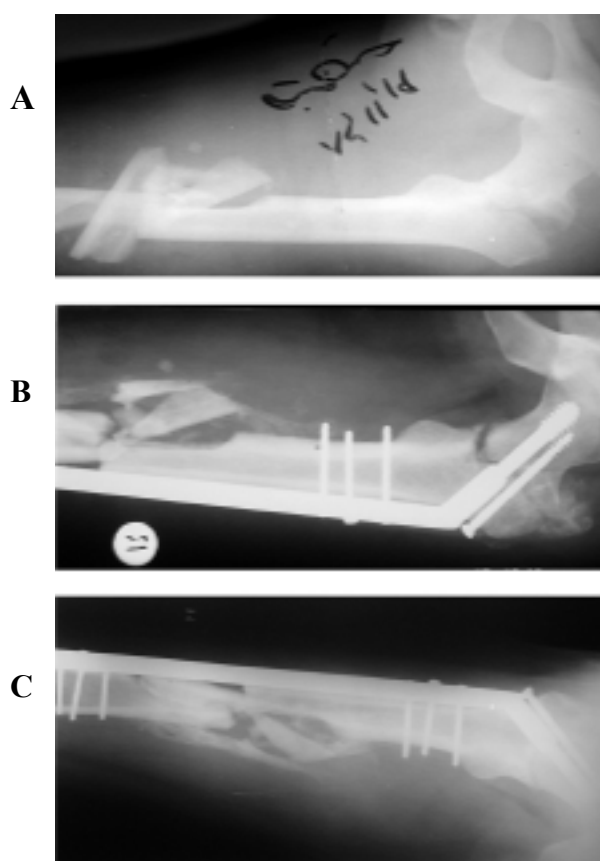


Figure 2. X-rays before and after the biologic fixation of femur

- A. the fracture zone before surgery in
 B. the fracture zone right after surgery.
 C. the fracture zone after beginning of callus formation and union.

Discussion

Despite the belief that soft tissues should be preserved during open reduction of fractures, surgeons traditionally have sought to achieve maximum stability regardless of the impact it might have on the soft tissues⁶. Baumgaertel et al⁷ demonstrated that indirect reduction and bridge plating was superior to direct fragment reduction and anatomical fixation in according to radiologic, biomechanics and microangiographic evidences. Faster gap filling and callus formation was shown beginning in the second or third week in indirect reduction, and in the sixth week in direct reduction. In the study of Agus et al⁴, 14 children (mean age 11.3 years) with a closed comminuted femur shaft fracture were surgically treated by biologic internal fixation using a bridging plate. The mean complete radiographic healing time was 12.4 weeks. After a mean follow-up period of 4 years, all patients were satisfied with the clinical outcome. It was concluded that biologic internal fixation by bridge plating was an effective surgical treatment method for closed comminuted fractures of the proximal and distal thirds of the femur shaft in children.

In 1994, Baumgaertel and Gotzen⁸ showed that in classic fixation 80% of the arteries were

damaged, but in biological fixation these vessels remain intact.

In the study of Tahmasebi et al⁵, in which 15 patients with closed comminuted fractures of the femur or tibia were treated through biological fixation, the mean time of union was 6.1 weeks in femur fractures and 8.3 weeks for tibial fractures (only 3 patients). There was no malunion, nonunion or complication, and they found this method to be useful. Finally, Sarafan et al⁹ showed that biological fixation is an appropriate method for closed comminuted fractures of long bones, yet is not suggested in open fractures due to the high rate of infection. According to these studies the number of cases in our study was sufficient, and the mean time of union was appropriate ($P < 0.05$). There were no complications or technical failure in this study. Only 3 patients had shortening, which did not cause any problems. Only 1 patient had 10° internal rotation deformity. This study found biological plating to be a cost beneficial and a technically easy procedure. This method which can be used in the treatment of comminuted fractures of long bones in situations in which "locked intramedullary nailing" is technically impossible or contraindicated.

References

1. Collinge C, Sanders R, DiPasquale T. **Treatment of complex tibial periarticular fractures using percutaneous techniques.** *Clin Orthop Relat Res* 2000;(375):69-77.
2. Burgess AR, Poka A, Brumback RJ, Flagle CL, Loeb PE, Ebraheim NA. **Pedestrian tibial injuries.** *J Trauma* 1987; 27(6):596-601.
3. Leunig M, Hertel R, Siebenrock KA, Ballmer FT, Mast JW, Ganz R. **The evolution of indirect reduction techniques for the treatment of fractures.** *Clin Orthop Relat Res* 2000;(375):7-14.
4. Agus H, Kalenderer O, Eryanilmaz G, Omeroglu H. **Biological internal fixation of comminuted femur shaft fractures by bridge plating in children.** *J Pediatr Orthop* 2003; 23(2):184-189.
5. Tahmasebi MT, Alami Harandi B, Navab E. **Treatment of comminuted fractures of femur and tibia with close reduction and plate fixation.** *Iranian journal of orthopedics* 1380; 1(1):1-9.
6. Vengsarkar NS, Goregaonkar AB. **"Biologic plating of comminuted femoral fractures".** *Bombay Hospital Journal* 2001; 43(1):169-174.
7. Baumgaertel F, Buhl M, Rahn BA. **Fracture healing in biological plate osteosynthesis.** *Injury* 1998; 29 Suppl 3:C3-C6.
8. Baumgaertel F, Gotzen L. **[The "biological" plate osteosynthesis in multi-fragment fractures of the pararticular femur. A prospective study].** *Unfallchirurg* 1994; 97(2):78-84.
9. Sarafan N, Maraashinejad A, Mehdinasab H. **Treatment of comminuted fractures of femur and tibia with biological fixation.** *Iranian journal of orthopedics* 1380; 1(3):40-45.