

Original Article**Cold dissection versus bipolar electrocautery tonsillectomy***Abdorrahim Kousha\**, *Rahmatollah Banan\**, *Nooshin Fotoohi\*\**, *Roosbeh Banan\*\*\****Abstract**

**BACKGROUND:** Tonsillectomy is one of the most common methods in Head and Neck operations and in ENT all over the world. Children are the most affected group. There are different methods of tonsillectomy including: the common method of using sharp instruments or a newer method the electrocautery, the monopolar or the bipolar, method. This study was conducted to compare cold dissection with bipolar electrocautery tonsillectomy.

**METHODS:** In a clinical trial carried on 60 patients between the ages of 6 to 15 at Amir-al-momenin Hospital in Rasht, one tonsil underwent the bipolar electrocautery tonsillectomy and the other underwent the cold dissection tonsillectomy. The amount of bleeding, duration of operation, throat pain and referral otalgia during hospitalization and after discharge were evaluated.

**RESULTS:** The average amount of bleeding related to electrocautery tonsillectomy was  $41.2 \pm 2.46$  ml and in cold dissection, tonsillectomy was  $73.13 \pm 3.37$  ml ( $P < 0.001$ ). The mean time of operation was  $9.1 \pm 0.39$  minutes and  $15.11 \pm 0.65$  respectively ( $P < 0.001$ ). On the second day after operation, 21.67% of the patients had more pain on the cauterized side and 31.67% experience pain on the other side. 46.66 of the patients had equal pain on the two sides. 15% of the patients had referral otalgia in the cauterized side and 16.67% in the other side. There was no pain in 68.37% of the patients.

**CONCLUSIONS:** The bipolar electrocautery appears to cause less bleeding and postoperative pain and it seems to be less time consuming in compare with the cold dissection tonsillectomy.

**KEYWORDS:** Tonsillectomy, cold dissection, bipolar electrocautery, postoperative complications.

JRMS 2007; 12(3): 117-120

**T**onsillectomy is one of the most common head and neck operations all over the world <sup>1</sup>. In the first century, "Celsus" performed tonsillectomy for the first time by using fingers or by using fingers and a sharp instrument. Then, various methods were introduced including cold dissection tonsillectomy, monopolar and bipolar electrocautery tonsillectomy, laser and cryosurgery <sup>2,4</sup>. Because most patients who undergo tonsillectomy are children, having a shorter duration in operation, less bleeding and pain after operation is very important <sup>5</sup>. We conducted this

research to find out which of these methods (bipolar electrocautery tonsillectomy or cold dissection tonsillectomy) offers us more advantages.

**Methods**

In a single-blind clinical trial, we included 60 patients (31 male, 29 female) between the ages of 6-15 in our study. The indications of tonsillectomy were mainly infected tonsil and obstructive symptoms. Throat infection for 10 days before the operation, the indication of malignancy or peritonsillar abscess, and the

\*Assistant professor, department of otolaryngology-head and neck surgery, Guilan university of medical sciences, Rasht, Iran. e-mail: a\_kousha\_enths@yahoo.com (Corresponding Author)

\*\*Resident of otolaryngology-head and neck surgery, Guilan university of medical sciences, Rasht, Iran

\*\*\*General practitioner, Rasht, Iran.

history of blood or cardiovascular disease were excluded in this study. It was a single-blind study, as patients were not aware of the operation technique and the electro-cauterized side was chosen randomly based on the even or odd ages. The operation procedure was explained for the patients before the surgery and they were asked to sign written consents. All the operations were done under general anesthesia and the same surgeon performed all the surgeries. Traditional cold dissection tonsillectomy was performed by scissors and snare and homeostasis was established by packing and 2-0 catgut sutures on one side. On the opposite side, bipolar electrocautery (4-4.5 w) and sharp instrument were used to remove the tonsils, but the lower pole of the tonsils were removed only by the use of electrocautery, and all the bleeding vessels were controlled by electrocautery and not by stitching. Bleeding on the each side was evaluated by measuring the amount of blood in the suction bag and the number of bloody gauze. Throat pain was evaluated by questioning the patients about the side of the tonsillectomy that they had more pain. Operation time was also measured for the each tonsil. Considering pain and referral otalgia and the disappearance of pseudomembrane tissue, the patients were evaluated on the second, 6th and the 8th day after the operation. Data analysis was done by paired-t-test and chi-square in SPSS software.

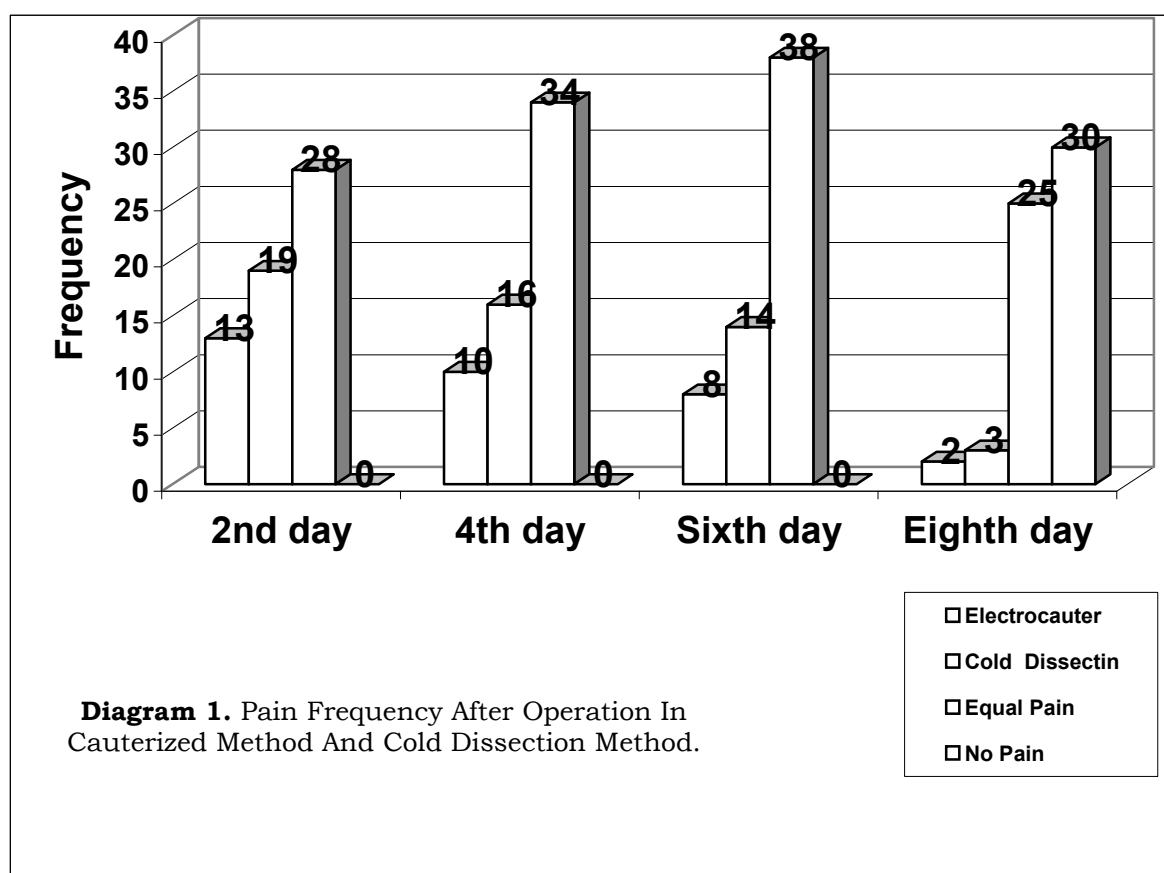
## Results

Using the electrocautery, the right side was operated in 31 patients and the left side was operated in 29 patients. Recurrent infection was the indication of the surgery in 53.33% of the patients and obstructive reasons were the indications in 46.67%. The average amount of the bleeding in cauterized side was  $41.2 \pm 2.46$  ml and on the other side was  $73.13 \pm 3.37$  ml. The maximum amount of bleeding on the cauterized side was 100 ml and minimum amount of bleeding was 10 ml. On the other side, maximum and minimum amounts of bleeding were 130 ml and 20 ml, respectively ( $P < 0.001$ ). The mean time of operation on the cauterized

part was  $9.1 \pm 0.39$  minutes and on the other side was  $15.11 \pm 0.65$  minutes ( $P < 0.001$ ). On the second day after the operation, 21.67% of the patients had pain on the cauterized side and 31.67% had more pain on the other side and 46.66% had equal pain on both sides. Eight days after the operation, 3.33% of the subjects had more pain on the cauterized side, 5% had more pain on the other side, 41.67% had equal pain on the both sides and 50% of the subjects had no pain at all. Statistical analysis of these findings indicated a significant difference in the two techniques ( $P < 0.001$ ) (figure 1). 15% of the subjects had referral otalgia on the cauterized side, 16.67% had it on the other side and 68.33% had no referral otalgia. 96.66% of the subjects on the 1<sup>st</sup> day, 1.67% on the 2<sup>nd</sup> day, 1.67% on the 3<sup>rd</sup> day and 11.66% on the 3<sup>rd</sup> day had pseudomembrane tissue on the cauterized side ( $P < 0.001$ ). After the 4<sup>th</sup> day, pseudomembrane tissue at all the cauterized sides disappeared. But on the other side, 80% of the patients had the tissue up to the 8<sup>th</sup> day and it only disappeared in the 20% of the cases after the 4<sup>th</sup> day after the operation ( $P < 0.001$ ). There was a significant difference in the formation and the disappearance of the pseudomembrane tissue in the two groups. Satisfaction and enjoyment of the surgeon was another important result of this study. In the common method, the surgeon always faces a bleeding field, making him anxious to stop it which is a very difficult task, especially at the inferior pole and the base of the tongue which leads to a mental and physical fatigue and sometimes results in less favorable results.

## Discussion

Using the electrocautery to remove tonsils has been the most common method in the United States since 1930. The monopolar and bipolar electrocautery may be used for tonsillectomy. However, the bipolar electrocautery transfers to a smaller part of the tissue. Therefore, the spread of heat to the tissue and its environment is less<sup>3,4,6</sup>. Due to the fast recovery and less pain in the



mechanical method which lead to the more protection and less damage to the tissue, it was believed that cold dissection was preferred to the other method <sup>6</sup>. Due to the tissue damage and heating injury of the electrocautery which may create pain after operation, epithelialization in surgical bed may be delayed <sup>6</sup>. All the above results are related to the monopolar electrocautery, which were demonstrated by Wexler <sup>7</sup>, Nunez <sup>5</sup>, Tay <sup>8</sup>, Leach <sup>9</sup> and Weimert <sup>10</sup>. Their studies indicated that monopolar tonsillectomy versus cold tonsillectomy has less operation time and intraoperative blood loss, but it has more pain <sup>2</sup>. However, bipolar electrocautery is preferred because of the less depth and the smaller area of involvement which contributes to less pain. Comparing the two methods in this study, the bipolar electrocautery

showed a less amount of bleeding and a shorter duration of operation than the cold dissection and it also indicated a significant difference. The observed differences are especially noteworthy in children and because its operation is more time preserving, the bipolar electrocautery is considered more economic. The results of this study confirm the results of the previous studies which were done to compare these two methods with monopolar electrocautery <sup>2</sup>. Considering pain on both sides, there was less pain in the cauterized side which showed a different result comparing the previous studies that showed more pain on the cauterized side after the operation by using monopolar electrocautery <sup>2</sup>. Our results partially were similar to Raut study (2000), which compared using a special scissor in bipolar electrocautery and

cold dissection method. However, in this study no significant difference was observed in pain of the both sides <sup>6</sup>. In our study, on the cauterized side, on the 8<sup>th</sup> day, the operation bed was completely similar to the normal tissue and the pseudomembrane tissue disappeared in 100% of the patients. However, on the non cauterized side, 80% of the patients had pseudo membrane tissue on the 8<sup>th</sup> day. On the cauterized side, a quick recovery of the tonsil tissue and returning to a normal situation was observed. Satisfaction and enjoyment of the surgeon was another important result of this study. We found the

electrocautery tonsillectomy a very versatile and an easy surgical method compared with the cold dissection tonsillectomy.

### Conclusions

Considering the less tissue damage, shorter operation time, less intraoperation blood loss, and having a quick recovery and less pain in the bipolar electrocautery tonsillectomy, this method is preferred to the cold dissection method and it is recommended as a perfect method of tonsillectomy, especially in children.

### References

1. Wiatrok B, Woolley A. **Pharyngitis and adenotonsillar disease**. In: Cummings CW, Haughey BH, Thomas JR, Harker LA, Flint PW, editors. *Cummings Otolaryngology: Head and Neck Surgery*. 4th ed. Philadelphia: Mosby; 2004. 4135-4165.
2. Leinbach RF, Markwell SJ, Colliver JA, Lin SY. **Hot versus cold tonsillectomy: a systematic review of the literature**. *Otolaryngol Head Neck Surg* 2003; 129(4):360-364.
3. Dyleski RA, Dennis M. **Tonsillitis, tonsillectomy and adenoidectomy**. In: Byron J Bailey, Byron J Bailey, Norman Friedman, Norman Friedman, Jeffrey T Vrabec, editors. *Atlas of Head & Neck Surgery-Otolaryngology*. 2nd ed. Lippincott Williams & Wilkins; 2001. 979-993.
4. Paradise JL. **Tonsillectomy and adenoidectomy**. In: Bluestone CD, editor. *Pediatric Otolaryngology*. 4<sup>th</sup> ed. Philadelphia: Saunders; 2003. 1210-1222.
5. Nunez DA, Provan J, Crawford M. **Postoperative tonsillectomy pain in pediatric patients: electrocautery (hot) vs. cold dissection and snare tonsillectomy--a randomized trial**. *Arch Otolaryngol Head Neck Surg* 2000; 126(7):837-841.
6. Raut V, Bhat N, Kinsella J, Toner JG, Sinnathuray AR, Stevenson M. **Bipolar scissors versus cold dissection tonsillectomy: a prospective, randomized, multi-unit study**. *Laryngoscope* 2001; 111(12):2178-2182.
7. Wexler DB. **Recovery after tonsillectomy: electrodissection vs. sharp dissection techniques**. *Otolaryngol Head Neck Surg* 1996; 114(4):576-581.
8. Tay HL. **Post-operative morbidity in electrodissection tonsillectomy**. *J Laryngol Otol* 1995; 109(3):209-211.
9. Leach J, Manning S, Schaefer S. **Comparison of two methods of tonsillectomy**. *Laryngoscope* 1993; 103(6):619-622.
10. Weimert TA, Babyak JW, Richter HJ. **Electrodissection tonsillectomy**. *Arch Otolaryngol Head Neck Surg* 1990; 116(2):186-188.