

## Case Report

### First report of Griscelli syndrome from Afghan population in IRAN

*Shirin Sayyahfar\**, *Abdollah Karimi\*\**, *Alireza Fahimzad\*\*\**, *Javad Ghorubi\*\*\*\**,  
*Atoosa Gharib\*\*\*\*\**, *Shahnaz Armin\*\*\**

#### Abstract

A 4 month old Afghan male infant presented with partial albinism, hepatosplenomegaly and pancytopenia. Skin and hair shaft microscopic examination revealed large clumped melanosomes and Griscelli syndrome was diagnosed. Unless treated with bone marrow transplantation, it is a fatal disease in accelerated phase. Pediatricians should consider this syndrome in infants with abnormal light hair because early diagnosis could be life saving.

**KEYWORDS:** Griscelli syndrome, partial albinism, hemophagocytic lymphohistiocytosis

JRMS 2008; 13(1): 38-40

**G**riscelli syndrome (GS) is a fatal rare autosomal recessive disorder, which was first reported by Griscelli et al in 1978<sup>1-4</sup>. It is characterized by gray silvery scalp hairs, eyelashes and eyebrows, hypopigmented areas of fundus and finally, variable degrees of humoral and cell mediated immunodeficiency<sup>1</sup>. We report a 4 month old Afghan male infant with generalized gray silvery hair, hepatosplenomegaly and pancytopenia. This is the first report of GS from Afghan population.

#### Case Report

A 4 month old Afghan male infant with irritability, abdominal distention and low grade fever for 7 days was admitted to a local hospital in outskirts of Tehran capital city with impression of idiopathic thrombocytopenic purpura. His parents were not relative and all of his

three siblings were normal with no family history of immunodeficiency. On examination, he had generalized silvery gray hair but normal skin, iris and retinal pigmentation (figure 1). His growth and developmental scales were within normal limits and he had no neurologic symptoms. He was referred to Mofid children hospital in Tehran and was admitted to the hematologic pediatric ward. Bone marrow aspiration was normal and thrombocytopenia persisted despite intravenous immunoglobulin and corticosteroid therapy. Liver and spleen began to enlarge in the third week and pancytopenia was developed. Investigations revealed a hemoglobin of 7.1 g/dL, a total leukocyte count of 900/mL (25% polymorphonuclears, 75% lymphocytes), a platelet count of 37,000/mL and a reticulocyte count of 0.2%. Liver function tests were within normal

\*Subspecialist, Pediatric Infectious Research Center, Shaheed Beheshti Medical University, Tehran, IRAN.

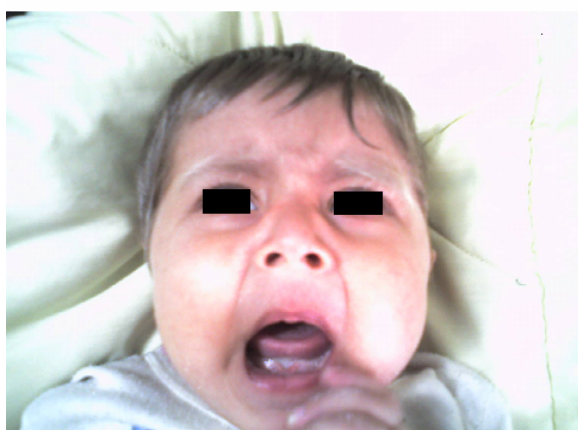
\*\*Professor, Pediatrics Department & Pediatric Infectious Research Center, Mofid Children Hospital, Tehran, IRAN.  
e-mail: info@pedirc.org (Corresponding Author).

\*\*\*Assistant Professor, Pediatric Infectious Research Center, Shaheed Beheshti Medical University, Tehran, IRAN.

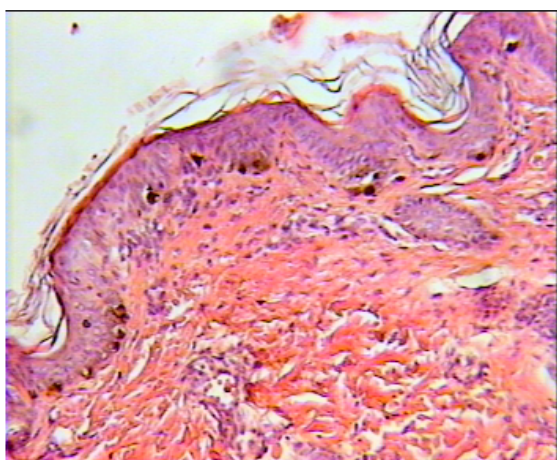
\*\*\*\*Assistant Professor, Department of Pediatric Surgery, Shaheed Beheshti Medical University, Tehran, IRAN.

\*\*\*\*\*Assistant Professor, Department of Pathology, Shaheed Beheshti Medical University, Tehran, IRAN.

ranges. Because of no abnormal granules on peripheral granulocytes and normal urine amino acid chromatography, Chediak Higashi syndrome and cystinosis were excluded, respectively. Despite broad spectrum antibiotic therapy, fever persisted and he was transferred to pediatric infectious ward. Viral serologic tests including HIV, HBV, HCV and EBV were negative. PPD test was non-reactive. The serum triglyceride, cholesterol and ferritin were 426 mg/dL, 660 mg/dL and 1788 ng/mL, respectively. Skin biopsy showed prominent melanocyte aggregations in the basal layer in nonhomogenous pattern. Hair shaft microscopic examination revealed large melanocyte aggregation in heterogeneous pattern, which is diagnostic for Griscelli syndrome (figure 2).



**Figure 1.** Generalized silvery gray hair of the patient.



**Figure 2.** Pathologic view of Griscelli syndrome.

The parents were informed about the nature of the disease and the available therapeutic options, but unfortunately he was discharged on his parents request before any investigation for immunodeficiency or genetic study and he died two months later.

## Discussion

Griscelli syndrome is a rare autosomal recessive disorder and most reports are from Turkish and Mediterranean populations<sup>4,5</sup>. The usual age of the onset is between 4 months to 4 years. Clinical manifestations are silvery scalp hairs, eyebrows and eyelashes, hypopigmented areas in the fundus and neurologic abnormalities. The accelerated phase of this syndrome (histiocytic infiltration of multiple organs due to viral or bacterial infections) is characterized by lymphadenopathy, hepatosplenomegaly and laboratory abnormalities such as pancytopenia, hyperlipidemia, hypofibrinogenemia and hemophagocytosis in bone marrow aspiration. It is one of the several syndromes of albinism associated with systemic findings<sup>6</sup>. Defects in package of melanin and other cellular proteins is the major pathology in GS but oculocutaneous albinism is associated with defects in production of melanin<sup>6</sup>. Defects in either of three distinct genes of *MAYO5A* (GS1), *RAB27 A* (GS2) or *MLPH* (GS3) all located on chromosome 15 q 21, are associated with this syndrome<sup>6</sup>. Patients with GS and defect in *RAB27A* gene develop an uncontrolled T lymphocyte-macrophage activated syndrome known as hemophagocytic lymphohistiocytosis secondary to infectious agents such as EBV. But, children with a defect in the *MYO5A* gene have neurological defects such as psychomotor retardation and progressive neurologic deterioration with no immunologic problems<sup>7</sup>. Hair microscopic examination in this syndrome reveals nonhomogenous clusters of aggregated melanin pigments that accumulate mainly in the medullary area of the hair shaft instead of the homogenous distribution of small pigment granules seen in normal hair. Skin light microscopic examination shows large clumps of melanin granules in melano-

cytes in the basal cell layer. GS is clinically similar to Chediak Higashi syndrome (CHS) but giant intracytoplasmic granules, which are seen in CHS are never observed in GS<sup>4</sup>. On the other hand, in GS the clusters of melanin pigments on the hair shaft are six times larger than those in CHS<sup>4</sup>. Elejalde syndrome or melanolysosomal neuroectodermal syndrome is another differential diagnosis of GS with MYO5 mutation. It is characterized with hypopigmentation and severe psychomotor retardation without immunodeficiency. Our patient had no neurologic developmental delay but, unfortunately he died before any investigation for immunodeficiency or genetic study. The long term survival in GS with Rab 27a mutation is relatively poor due to fatal accelerated phase. There are two options for treatment; one is chemotherapy with etoposide, methotrexate, cyclosporine, and immunomodulatory agents (e.g., anti-thymocyte globulin and steroids) with variable success rates and the other is allogenic bone marrow transplantation (BMT) that remained the only curative treatment for this disorder. In MYO5a defect there is no role for BMT in treating neurologic impairments. Our major limitations were inability to perform genetic and immunologic studies due to noncompliance of the patient's parents. Although gene study is helpful to confirm the syndrome and inform the parents, but the findings of skin and hair biopsies are distinctive and pathognomonic. Most cases found in the literature, have not reported gene study.

Rath et al reported an eight month old male infant with silvery scalp hair and eyelashes, generalized lymphadenopathy, hepatosplenomegaly, microcephaly, developmental delay and a history of recurrent infections with diagnosis of Griscelli syndrome in view of clinical features and characteristic skin biopsy findings<sup>3</sup>. Manglani et al reported a 22 month old female with silvery gray hair, abdominal distention, jaundice, anasarca and hepatosplenomegaly with diagnosis of Griscelli syndrome documented with microscopic examination of the hair shaft<sup>1</sup>. Dinakar et al reported a six year old girl presented with silvery gray hair, massive hepatosplenomegaly, icterus, anasarca, regression of growth and development milestones and recurrent fever with diagnosis of Griscelli syndrome in view of clinical manifestations and typical skin and hair pathology<sup>2</sup>. Malhotra et al reported a four month old male infant with silvery gray hair, abdominal distention, hepatosplenomegaly, pallor and recurrent fever with diagnosis of Griscelli syndrome documented with light microscopy of scalp hair and skin biopsy findings<sup>8</sup>. Our patient had similar symptoms such as silvery gray hair and signs of activated phase in addition to characteristics of skin and hair biopsy compatible with Griscelli syndrome.

## Conclusion

Pediatricians should be alert and consider GS in infants with abnormal light hair because early diagnosis could be life saving.

## References

1. Manglani M, Adhvaryu K, Seth B. **Griscelli syndrome - a case report.** *Indian Pediatr* 2004;41:734-737.
2. Dinakar C, Lewin S, Kumar KR, Harshad SR. **Partial albinism, immunodeficiency, hypergammaglobulinemia and Dandy-Walker cyst - a Griscelli syndrome variant.** *Indian Pediatr* 2003;40:1005-1008.
3. Rath S, Jain V, Marwaha RK, Trehan A, Rajesh LS, Kumar V. **Griscelli syndrome.** *Indian J Pediatr* 2004;71:173-175.
4. Sheela SR, Latha M, Injody SJ. **Griscelli syndrome: Rab 27a mutation.** *Indian Pediatr* 2004;41:944-947.
5. Scheinfeld NS. **Syndromic albinism: a review of genetics and phenotypes.** *Dermatol Online J* 2003;9:5.
6. Aslan D, Sari S, Derinoz O, Dalgic B. **Griscelli syndrome: description of a case with Rab27A mutation.** *Pediatr Hematol Oncol* 2006;23:255-261.
7. Ashrafi MR, Mohseni M, Yazdani S, Alizadeh H, Ramyar A, Aghamohammadi A, et al. **Bilateral basal ganglia involvement in a patient with Griscelli syndrome.** *Eur J Paediatr Neurol* 2006;10:207-209.
8. Malhotra AK, Bhaskar G, Nanda M, Kabra M, Singh MK, Ramam M. **Griscelli syndrome.** *J Am Acad Dermatol* 2006;55:337-340.