

## Case Report

### Primary Kaposi's Sarcoma of Penis

P. Mahzooni MD\*, D. Taheri MD\*\*, A. Gookizadeh MD\*\*\*

#### ABSTRACT

Kaposi's sarcoma rarely involves penis and is usually accompanied by other cutaneous, mucous or visceral lesions. We report a case of Kaposi's sarcoma of penis.

Although Kaposi's sarcoma is known to be associated with an altered immune status, acquired immunodeficiency syndrome (AIDS) and other causes of immunodeficiency were not found in this case.

**Key Words:** Kaposi's sarcoma, Acquired Immunodeficiency Syndrome

**K**aposi's sarcoma (KS) is a multifocal process of vascular origin that may involve skin as well as viscera. Cutaneous involvement is most frequent, since it is usually the first and in many cases the only location. Other frequent sites of involvement are oral cavity, lymph nodes, gastrointestinal tract, and lungs<sup>1</sup>.

It appears as sporadic, endemic or in association with HIV and non-HIV induced immunosuppression<sup>2</sup>.

Kaposi's sarcoma is the most common neoplasm seen in AIDS patients. More than half of all HIV positive homosexual men develop kaposi's sarcoma lesions<sup>1</sup>.

As a whole, almost 20% of patients with kaposi's sarcoma have lesions on their genitalia, yet in only 3% of these, the initial lesion appears on penis<sup>3</sup>.

However, the initial and exclusive involvement of penis is extremely rare.

Here, we present a case of primary Kaposi's sarcoma of penis.

#### Case Report

The case is a 57- year-old white man who was hospitalized for the appearance of a purple lesion on his penis from 2 months earlier.

The routine physical examination performed revealed nothing abnormal except a soft, non-tender

papule on his glans penis. It measured 5 mm in diameter and was red-wine colored with a smooth surface and well defined margins.

There were no similar lesions on any other cutaneous or mucous membranes. Neither lymph adenopathy nor organomegaly was found. Cardiovascular, respiratory and central nervous system examinations showed no abnormalities either.

He gave no history of immunosuppression, intravenous drug abuse, hemophilia, or homosexuality. Excisional biopsy of the lesion revealed proliferation of spindle-shaped cells lining erythrocyte-filled vascular slits and dilated capillaries lined with prominent endothelial cells. The stroma contained extravasated erythrocytes. Occasional atypia or mitosis were seen (Fig 1).

Based on these histopathological features, Kaposi's sarcoma was diagnosed. Routine laboratory findings were within the range of normal. Serological test for HIV-infection was negative. Chest and abdominal X-rays besides CT scan of the abdomen and pelvis were normal.

The patient was scheduled to have 14 sessions of radiotherapy, 250 CGY, each session with a total amount of 3500 GCY.

One year follow-up showed no evidence of local or distant recurrence.

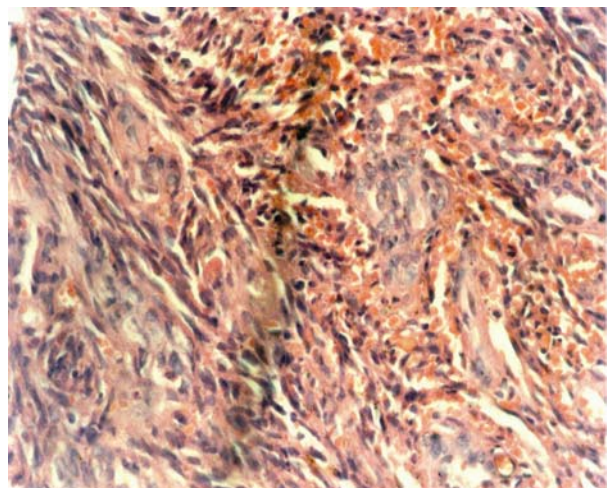
---

\*Associate Professor, Department of pathology, Isfahan University of Medical Sciences, Isfahan, Iran.

\*\*Assistant Professor, Department of pathology, Isfahan University of Medical Sciences, Isfahan, Iran.

\*\*\*Assistant professor, Department of Radiotherapy and Oncology, Isfahan University of Medical Sciences, Isfahan, Iran.

Correspondence to: Dr. Parvin Mahzooni, Department of pathology, Isfahan University of Medical Sciences, Isfahan, Iran. Email: Mahzooni@med.mui.ac.ir



**Figure 1.** Histologic findings of Kaposi's sarcoma depicting numerous vascular spaces and extravasated erythrocytes.

## Discussion

Kaposi's sarcoma was first described by Moriz Kaposi in 1872<sup>1</sup>. It involves both skin and viscera. It can involve skin of any part of the body including mucous membranes of mouth, pharynx, conjunctiva and penis<sup>2</sup>. The involvement of genitalia has been described in patients having generalized Kaposi's sarcoma, but exclusive involvement of genitalia is rare<sup>4</sup>. In our patient, the primary site of involvement was penis. No further lesions were noticed on other parts of the body.

The etiology of Kaposi's sarcoma remains obscure. Prior to the epidemics of AIDS, many cases of Kaposi's sarcoma had been reported in Europe and sub-Saharan Africa<sup>4</sup>.

HIV infection associated with Kaposi's sarcoma was first recognized in 1979 as one of the manifesta-

tions of severe immunodeficiency seen in homosexual men<sup>4</sup>. It has been known for many years that patients may develop Kaposi's sarcoma when immunosuppressed for reasons other than HIV infection, for example, Human Herpes Virus type 8 (HHV-8) may play a major role in inducing these tumors<sup>2,5</sup>.

Treatment of Kaposi's sarcoma depends on the extent of lesions and the severity of symptoms. Local therapy is recommended when possible because it is generally less toxic<sup>3</sup>. Therapy includes local excision, external radiation, cryotherapy and intralesional chemotherapy. Local excision and external beam radiation are used primarily in cases of local, symptomatic disease or for cosmetic purposes<sup>3</sup>.

Certain patients with rapidly progressive disease require poly-chemotherapy with cytotoxic drugs<sup>3</sup>. Treatment in our patient was excision of penile lesion plus local irradiation, however systemic therapy did not seem necessary.

In our review of literature, we found two reports of primary Kaposi's sarcoma of penis, one of which ended in spontaneous regression of the lesions.

This phenomenon is not easy to explain<sup>6-7</sup>. There is some evidence that Kaposi's sarcoma is not a malignant neoplasm but a benign, potentially controllable and reversible hyperplasia, and its development could possibly be related to a previous viral infection (Cytomegalovirus, Epstein-Barr virus and Human Immunodeficiency Virus)<sup>7</sup>.

We wish to remind urologists and dermatologists to consider the diagnosis of Kaposi's sarcoma whenever a red-wine lesion is noted on penis so that the proper workup can be done.

## References

1. Rappersberger K, Sting LG, Wolff K. Kaposi's sarcoma. In: Freedberg IM, et al. Fitzpatrick's dermatology in general medicine. New York, MC Grow-hill, 1999:1195-1203.
2. Frederick JS, Ramzi SC. Blood vessels. In: Cotran RS, Kumar V, Collins T Robbins Pathologic Basis of disease. Philadelphia, WB Saunders, 1999: 535-537.
3. Weil D, Ruckle H, Lui P, Saukel GW. Kaposi sarcoma of the testicle. *Infection in urology*, 1999; 12:79-83.
4. Govalkar RM, Wangnoo SK. Localized Genital kaposi sarcoma. *Annals of saudi medicine (ASM)*; 1994 : 146.
5. Rosai J. Skin. In: Rosai J. Ackerman's surgical pathology. St louis, Mosby, 1996:184-188.
6. Koyuncuoglu M, Yalcin N, Ozkan S, Kirkali. Primary Kaposi's sarcoma of the glans penis. *Brithish journal of urology*, 1996; 77,614-615.
7. Casado M, Jimenez F, Borbujo J, Almagro M. Spontaneous healing of kaposi's angiosarcoma of the penis the journal of urology, 1988;139: 1313-1315.