

Original Article**Evaluation of keratoconus by videokeratography in subjects with vernal keratoconjunctivitis (VKC)***M.R. Shoja\*, M.R. Besharati\****Abstract**

**BACKGROUND:** To assess demographic variables and the incidence of keratoconus in patients with VKC and to evaluate the characteristics of Vernal Keratoconjunctivitis (VKC) associated with keratoconus.

**METHODS:** One hundred and fifty patients with VKC were studied at Ophthalmology Department of Shaheed Sadoughi medical center between October 2004 and June 2005. Both eyes of VKC patients were evaluated by Orbscan topography for the diagnosis of keratoconus. Corneal topography maps were examined with modified Robinowitz-McDonnell test. The characteristics of VKC were recorded in keratoconus patients.

**RESULTS:** The study included 93 male and 57 female subjects. The patients mean age was  $13.07 \pm 4.71$  (range 8-24) years. The clinical forms of VKC were as follows: 45.2% mixed, 38% palpebral and 16.7% limbal types. Fifty four (36%) of 150 subjects with VKC had complications of pseudogerontoxon, punctate keratitis and shield ulcer. Eighty-four eyes (42 subjects) of 150 patients with VKC were detected as having keratoconus by videokeratography maps (28%). There were 27 males and 15 females in keratoconus group. 16.7% of the eyes had mild, 33.3% had moderate and 50% had severe keratoconus. Eyes with severe keratoconus presented at younger age ( $12.7 \pm 3.35$  years) than moderate keratoconus ( $18.3 \pm 2.15$  years). Keratoconus was more common in male gender, long-standing disease, mixed and palpebral VKC.

**CONCLUSION:** Screening of keratoconus subjects with corneal topography allows early detection and management of keratoconus. The higher incidence of keratoconus in our study is due to videokeratography study of early keratoconus.

**KEYWORDS:** VKC, videokeratography, keratoconus.

JRMS 2006; 11(3): 164-169

Vernal keratoconjunctivitis (VKC) is an ocular allergic disease predominantly observed in children and young adults<sup>1</sup>. VKC occurs more commonly in males than females, with an onset typically between 8 and 10 years of age<sup>2</sup>. VKC is more prevalent in areas which are hot and dry such as Mediterranean area and Middle East<sup>3</sup>. The disease occurs in palpebral, limbal and mixed forms<sup>4</sup>. Corneal involvement occurring in about 50% of the cases is manifested as pseudogerontoxon, punctate epithelial keratitis, shield ulcer and superficial pannus<sup>5,6</sup>.

Keratoconus is a bilateral non-inflammatory

corneal ectasia with an incidence of approximately 1/2000 in general population<sup>7,8</sup>. Physical manifestations include Vogt's striae, stromal thinning, and irregular corneal astigmatism. Positive association of keratoconus with VKC<sup>9,10</sup>, eye rubbing, atopy and Down syndrome<sup>11,12</sup> have been described. Computerized videokeratography (orbscan topography) is now recognized an important tool in assessing, diagnosing and treating keratoconus. Early forms of keratoconus may go undetected unless videokeratography is applied<sup>13-15</sup>.

In previous reports, the incidence of keratoconus in VKC might be less than its actual

\* Associate Professor, Department of Ophthalmology, Shahid Sadoughi University of Medical Sciences, Yazd, Iran.

Correspondence to: Dr Mohammad Reza Shoja, Department of Ophthalmology, Shahid Sadoughi University of Medical Sciences, Yazd, Iran. e-mail: shoja99@yahoo.com

occurrence, because none of them used corneal topography in detecting keratoconus<sup>16</sup>.

The purpose of this study was to evaluate the incidence of keratoconus in VKC population by quantitative analysis of topographic maps to find the overall incidence of keratoconus in general population, and to detect clinical characteristics of VKC associated with keratoconus.

## Methods

A prospective database at corneal service of Department of Ophthalmology, Shaheed Sadooghi Medical Sciences University in Yazd (Iran) for all VKC patients from October 2004 to June 2005 provided information for this study. One hundred and fifty patients with VKC were assessed.

The subjects were interviewed as to age of onset of itching, frequency of abnormal eye rubbing, visual difficulties and presence of atopic disease. Each subject underwent a complete ophthalmic examination. The diagnosis of VKC was made on the history of severity of itching, with giant papillae on the palpebral conjunctiva and Horner-Trantas dots. Other corneal signs including pseudogerontoxon and punctate epithelial keratitis were noted. VKC was categorized as palpebral, limbal, or mixed as described by Cameron<sup>17</sup>. The diagnosis of keratoconus was based on slit-lamp biomicroscopy, keratometry and computerized videokeratography. Slit-lamp biomicroscopic findings of keratoconus such as Vogt's line, fleischer ring, stromal thinning, stromal scarring and keratometric findings of irregular mires consistent with diagnosis of keratoconus were recorded for each subject.

All patients underwent Orbscan corneal topographic analysis. We defined keratoconus on characteristic clinical features as in CLEK study<sup>18</sup>. Corneal topographic data were quantitatively analyzed by using the modified Rabinowitz-McDonnell criteria; i.e. patients with average simulated keratometry of more than 46 D, central corneal power of more than 47.3 D or infero-superior asymmetry (I-S)

higher than 1/4 D were considered to have keratoconus.

To calculate the I-S value, we measured the dioptric power at five points along the inferior cornea at 30° intervals and five points on the superior cornea. Superior values were subtracted from the inferior values and expressed as I-S values. A positive I-S value therefore, indicates a relative steeper inferior cornea, whereas a negative I-S value indicates a steeper superior cornea.

Quantitative analysis of corneal videokeratographic maps taken by Bausch & Lomb (Technolas 100) Orbscan with Rabinowitz-McDonnell test is an objective clinical method with sufficient sensitivity and specificity for detection of keratoconus. Keratoconic eyes without definite signs were identified based on the I-S values of the above mentioned topographic criteria.

VKC subjects with keratoconus were classified into three categories of mild (<45 D), moderate (45-52 D) and severe (>52 D) on the basis of steep keratometric readings.

Findings were analyzed and the results were reported on the incidence of keratoconus and associated corneal findings in patients with VKC. Chi-square test performed for each category of variables, and  $P < 0.05$  was considered significant.

## Results

The study included 93 male and 57 female subjects. The mean age of patients was  $13.07 \pm 4.71$  years (range of 5-21 years). The mean duration of symptoms was  $5.12 \pm 4.29$  years. VKC was mixed in 68 subjects, palpebral in 57 and limbal in 25 subjects (16.7%). Fifty-four cases (36%) of 150 subjects with VKC had keratopathy along with corneal complications such as pseudogerontoxon (44.4%), epithelial keratitis (46.3%) and shield ulcer (9.3%). The symptoms were seasonal in 122 subjects and throughout the year in 28 subjects. Eighty subjects with VKC rubbed their eyes frequently (>8 times daily) and thirty subjects (20%) rubbed their eyes occasionally (<4 times daily). The

incidence of keratoconus detected by slit-lamp biomicroscopy, keratometry and videokeratography in our study were 14%, 40% and 100%, respectively.

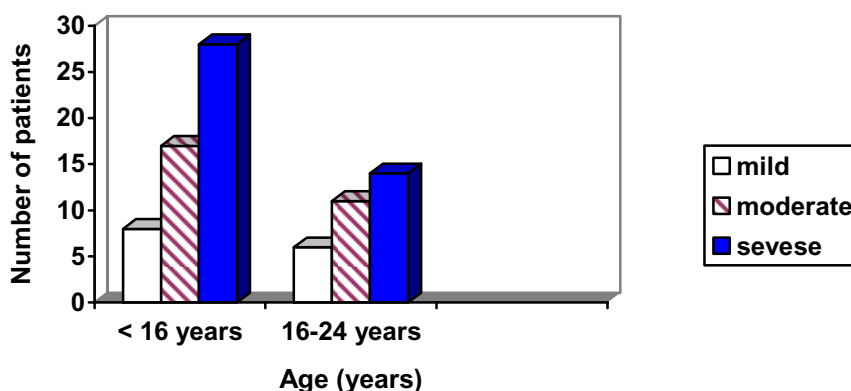
Eighty four eyes of 42 subjects (28%) were detected as having keratoconus according to modified Rabinowitz-Mc Donnell criteria quantitative evaluation of videokeratography. Based on average keratometric values and topography, 42 eyes (50%) had severe and 28 (33.4%) had moderate and 14 eyes (16.6%) had mild keratoconus. Onset of VKC symptoms preceded the visual complaints. Seventy two eyes with keratoconus (85.5%) presented at age <20 years. Twenty eight eyes of 21 patients with severe keratoconus presented at age <16

years (66.6%), compared to seven eyes (25%) with moderate form (figure1). Patients with severe keratoconus in either eye, presented at a younger average age ( $14.21 \pm 2.13$  years) compared with mild to moderate keratoconus ( $14.15 \pm 4.35$  years).

There were 27 male and 16 female subjects with keratoconus. The subjects with keratoconus had a mean age of  $14.5 \pm 5.34$  years at presentation and mean duration of symptoms was  $7.65 \pm 4.32$  years. The keratoconus group consisted of 16 subjects (32 eyes) with mixed, 18 patients (36 eyes) with palpebral and 8 cases (16 eyes) with limbal VKC. Slit-lamp signs were observed more frequently in severe keratoconus (table 1).

**Table 1.** Biomicroscopic signs in keratoconus patients with VKC.

Keratometry	Vogt's Striae	Fleischer Ring	Corneal Scarring	Hydrops	No Signs
45-52 D (n = 42 eyes)	8 (19%)	10 (23.8%)	1(2.3%)	-	9 (21.4%)
>52 D (n = 42 eyes)	28 (66.6%)	27 (64.3%)	12 (28.5%)	4 (9.5%)	4 (9.5%)
P value	0.02	0.08	0.002	0.138	0.006



**Figure 1.** Age distribution of mild, moderate and severe keratoconus.

Twenty eight severe keratoconus eyes (66.6%) demonstrated Vogt's striae compared to only 8 with mild to moderate keratoconus. Apical sub-epithelial scarring of the cornea was observed in 13 eyes. Twelve of these (92.3%) had severe keratoconus and this difference was significant ( $P = 0.001$ ).

Thirty five keratoconic eyes (41.6%) demonstrated prominent corneal nerves on slit-lamp examination.

Keratoconus was progressive in many VKC patients resulting in gross visual loss, often not correctable with glasses or contact lenses and thus require penetrating keratoplasty. How-

ever, because of complications such as prematurely loosened sutures and steroid-induced cataract are more common in the coexistence of VKC with keratoconus, closer monitoring is necessary in these cases. Four eyes (4.5%) presented with corneal hydrops and this early occurrence of hydrops indicates coexisting of keratoconus with VKC.

Association of keratoconus with VKC and atopic disorders is also stressed. Summary of keratoconus cases associated with VKC is shown in table 2.

**Table 2.** Summary of VKC patients with keratoconus.

Clinical Characteristic	Data
Age at presentation	
Range (mean $\pm$ SD)	8-20 (14.5 $\pm$ 5.34)
Duration of VKC symptoms	
Range (mean $\pm$ SD)	5-16 (7.65 + 432)
Sex	
(male/female)	27/15
Type of VKC	Number of subjects
Mixed	16
Palpebral	18
Limbal.	8
Corneal Complications	Number of eyes
Punctate epithelial keratitis	28
Pseudogerontoxon	24
Shield ulcer	5
Severity of keratoconus	Number of eyes
Mild or Moderate	42
Advanced	42

**Table 3.** Complications of VKC and severity of keratoconus.

Clinical Characteristic	Data
Type of VKC	Number of subjects
Mixed	16
Palpebral	18
Limbal	8
Corneal complications	Number of eyes
Punctate epithelial keratitis	28
Pseudogerontoxon	24
Shield ulcer	5
Severity of keratoconus	Number of eyes
Mild or Moderate	42
Advanced	42

## Discussion

Keratoconus is a bilateral asymmetrical disease<sup>7</sup> and there is a strong association between VKC, atopy and keratoconus. In a series of 530 cases of VKC examined with slit-lamp biomicroscope and keratometry, Khan et al<sup>19</sup> reported a 7% incidence of keratoconus. Totan<sup>9</sup> in a videokeratographic study reported a 26.8% incidence of keratoconus in VKC. In our study, the incidence of keratoconus detected by videokeratography in VKC was 28%. The higher incidence rate in our study may have resulted from higher sensitivity of our method of topography maps for screening keratoconus compared with traditional methods of biomicroscopy and keratometry applied in Khan's study. Quantitative analysis of corneal videokeratographic maps is an objective clinical method for early detection of keratoconus when compared with the traditional methods including biomicroscopy, keratometry and keratometry<sup>14,20</sup>.

In our study, males outnumbered females in incidence of keratoconus (27 versus 15). The male predominance in the study in combined VKC and keratoconus reflects the high prevalence of VKC in males, which is in agreement with the previous studies<sup>17,19,21</sup>.

In our study, the distribution of clinical forms of VKC was as follows: 45.2% mixed, 38% palpebral and 16.7% limbal types. In a similar study by Totan<sup>9</sup> this distribution was 46.34%, 43.90% and 9.76%, respectively which was slightly different from our report.

We showed a high incidence of complicated corneal findings of VKC (36%), such as punctate keratitis pseudogerontoxon and shield ulcer that was in agreement with Totan<sup>9</sup> study with incidence rate of 31.7%. In Barr's study<sup>22</sup> corneal scar was seen in 15.3% of advanced keratoconus, which was far less than that in our study (28.5%).

This prominent association of corneal complications in VKC may be considered to cause secondary degeneration in corneal structure, predisposing to keratoconus in susceptible subjects<sup>23,24</sup>.

In VKC, eye rubbing is common, because of complaint of intense itching. The role of chronic eye rubbing has been described in the pathogenesis of keratoconus<sup>25</sup>. Kerseras and Ruben<sup>26</sup> elicited a history of eye rubbing in 66% of their patients, while Rahi<sup>27</sup> reported that 48% of patients in their study rubbed their eyes from a fair amount to a great deal. We reported a similar frequency of the eye rubbing in moderate and severe keratoconus indicating a possible role in progression of keratoconus.

Hydrops in keratoconus associated with VKC is a common complication and it may be a presenting clinical sign of keratoconus in children with VKC<sup>28</sup>. Khan et al reported 12.5% of acute hydrops in 48 subjects with VKC<sup>9</sup>. In the study of Cameron<sup>17</sup>, acute hydrops occurred in 13% of keratoconus subjects with VKC. In our study, 8 eyes (9%) presented with acute corneal hydrops. It seems that eye rubbing could be a possible risk factor responsible for corneal thinning or acute hydrops. Tuft<sup>29</sup> reported that acute hydrops developed in younger males, who had advanced corneal ectasia and poor corrected VA at the diagnosis of their keratoconus and the development of hydrops was a very significant risk factor for subsequently receiving a penetrating keratoplasty.

The greater rate of eyes rejection than eyes grafted without hydrops is due to prematurely loosened sutures and more common steroid induced cataract<sup>30</sup>. Close monitoring is necessary for penetrating keratoplasty in eyes with keratoconus and VKC<sup>31</sup>. Zadnik and co-work-

ers found that more advanced keratoconus was associated with a greater proportion of at least one positive slit-lamp finding<sup>32</sup>. In our study, 85.8% of patients with severe keratoconus elicited one or more slit-lamp signs, compared with 54% of those with mild to moderate keratoconus. Our data showed that disease severity as measured by average Simulated Keratometry is associated with higher prevalence of biomicroscopic signs and increased apical sub-epithelial scarring that is in agreement with Saini study<sup>33</sup>. A total of 85.5% of our keratoconic patients presented before the age of 20 years, whereas in Saini's study<sup>33</sup>, 52% of patients were younger than 20 years old. Our study showed that in severe keratoconus, the average age at first presentation was  $14.21 \pm 2.13$  years, whereas in Crew's report it was  $18.8 \pm 5.35$  years<sup>34</sup>.

These observations indicated that in Persian eyes, keratoconus often progresses rapidly with severe grades at younger ages. We believe that the objective method for assessment of topography maps allowed us to detect keratoconus at an early stage.

## Conclusion

Our findings showed a strong association of keratoconus with VKC. Severe visual loss was probably due to corneal complications of VKC, including scar and keratoconus. The association of vernal conjunctivitis with keratoconus may contribute to the early occurrence of hydrops.

## References

1. Buckley RJ. **Vernal keratoconjunctivitis**. *Int Ophthalmol Clin* 1988; 28:303-308.
2. Heidemann DG. **Atopic and vernal keratoconjunctivitis**. *Focal points. Am Acad Ophthalmol* 2001; 19:1-11.
3. Kanski JJ. **Clinical Ophthalmology**. 4 ed. Oxford: Butterworth-Heinemann, 1999.
4. Tuft SJ, Cree IA, Woods M, Yorston D. **Limbal vernal keratoconjunctivitis in the tropics**. *Ophthalmology* 1998; 105:1489-1493.
5. Colby K, Dohlman C. **Vernal keratoconjunctivitis**. *Int Ophthalmol Clin* 1996; 36:15-20.
6. Kosrirukvongs P, Vichyanond P, Wongsawad W. **Vernal keratoconjunctivitis in Thailand**. *Asian Pac J Allergy Immunol* 2003; 21:25-30.
7. Krachmer JH, Feder RS, Belin MW. **Keratoconus and related noninflammatory corneal thinning disorders**. *Surv Ophthalmol* 1984; 28:293-322.

8. Rabinowitz YS. **Keratoconus.** *Surv Ophthalmol* 1998; 42:297-319.
9. Totan Y, Hepsen IF, Cekic O, Gunduz A, Aydin E. **Incidence of keratoconus in subjects with vernal keratoconjunctivitis: a videokeratographic study.** *Ophthalmology* 2001; 108:824-827.
10. Tabbara KF. **Ocular complications of vernal keratoconjunctivitis.** *Can J Ophthalmol* 1999; 34:88-92.
11. Bawazeer AM, Hodge WG, Lorimer B. **Atopy and keratoconus: a multivariate analysis.** *Br J Ophthalmol* 2000; 84:834-836.
12. Pierse D, Eustace P. **Acute keratoconus in mongols.** *Br J Ophthalmol* 1971; 55:50-54.
13. Auffarth GU, Wang L, Volcker HE. **Keratoconus evaluation using the Orbscan Topography System.** *J Cataract Refract Surg* 2000; 26:222-228.
14. Maeda N, Klyce SD, Smolek MK. **Comparison of methods for detecting keratoconus using videokeratography.** *Arch Ophthalmol* 1995; 113:870-874.
15. Rabinowitz YS. **Tangential vs sagittal videokeratographs in the "early" detection of keratoconus.** *Am J Ophthalmol* 1996; 122:887-889.
16. Wilson SE, Lin DT, Klyce SD. **Corneal topography of keratoconus.** *Cornea* 1991; 10:2-8.
17. Cameron JA, Al Rajhi AA, Badr IA. **Corneal ectasia in vernal keratoconjunctivitis.** *Ophthalmology* 1989; 96:1615-1623.
18. Zadnik K, Barr JT, Gordon MO, Edrington TB. **Biomicroscopic signs and disease severity in keratoconus. Collaborative Longitudinal Evaluation of Keratoconus (CLEK) Study Group.** *Cornea* 1996; 15:139-146.
19. Khan MD, Kundi N, Saeed N, Gulab A, Nazeer AF. **Incidence of keratoconus in spring catarrh.** *Br J Ophthalmol* 1988; 72:41-43.
20. Zarnowski T, Haszcz D, Zagorski Z. **[Corneal topography of keratoconus].** *Klin Oczna* 1997; 99:21-24.
21. Lapid-Gortzak R, Rosen S, Weitzman S, Lifshitz T. **Videokeratography findings in children with vernal keratoconjunctivitis versus those of healthy children.** *Ophthalmology* 2002; 109:2018-2023.
22. Owens H, Gamble G. **A profile of keratoconus in New Zealand.** *Cornea* 2003; 22:122-125.
23. Barr JT, Zadnik K, Wilson BS, Edrington TB, Everett DF, Fink BA et al. **Factors associated with corneal scarring in the Collaborative Longitudinal Evaluation of Keratoconus (CLEK) Study.** *Cornea* 2000; 19:501-507.
24. Szczotka LB, Barr JT, Zadnik K. **A summary of the findings from the Collaborative Longitudinal Evaluation of Keratoconus (CLEK) Study. CLEK Study Group.** *Optometry* 2001; 72:574-584.
25. Harrison RJ, Klouda PT, Easty DL, Manku M, Charles J, Stewart CM. **Association between keratoconus and atopy.** *Br J Ophthalmol* 1989; 73:816-822.
26. Karseras AG, Ruben M. **Aetiology of keratoconus.** *Br J Ophthalmol* 1976; 60:522-525.
27. Rahi A, Davies P, Ruben M, Lobascher D, Menon J. **Keratoconus and coexisting atopic disease.** *Br J Ophthalmol* 1977; 61:761-764.
28. Rehany U, Rumelt S. **Corneal hydrops associated with vernal conjunctivitis as a presenting sign of keratoconus in children.** *Ophthalmology* 1995; 102:2046-2049.
29. Tuft SJ, Gregory WM, Buckley RJ. **Acute corneal hydrops in keratoconus.** *Ophthalmology* 1994; 101:1738-1744.
30. Iqbal A, Jan S, Babar TF, Khan MD. **Corneal complications of vernal catarrh.** *J Coll Physicians Surg Pak* 2003; 13:394-397.
31. Egrilmez S, Sahin S, Yagci A. **The effect of vernal keratoconjunctivitis on clinical outcomes of penetrating keratoplasty for keratoconus.** *Can J Ophthalmol* 2004; 39:772-777.
32. Zadnik K, Barr JT, Edrington TB, Everett DF, Jameson M, McMahon TT et al. **Baseline findings in the Collaborative Longitudinal Evaluation of Keratoconus (CLEK) Study.** *Invest Ophthalmol Vis Sci* 1998; 39:2537-2546.
33. Saini JS, Saroha V, Singh P, Sukhija JS, Jain AK. **Keratoconus in Asian eyes at a tertiary eye care facility.** *Clin Exp Optom* 2004; 87:97-101.
34. Crews MJ, Driebe WT, Jr., Stern GA. **The clinical management of keratoconus: a 6 year retrospective study.** *CLAO J* 1994; 20:194-197.