

Case Report**Slipped vertebral epiphysis (report of 2 cases)***Majid Reza Farrokhi\*, Mohammad Sadegh Masoudi\****Abstract**

Avulsion or fracture of posterior ring apophysis of lumbar vertebra is an uncommon cause of radicular low back pain in pediatric age group, adolescents and athletes. This lesion is one of differential diagnosis of disc herniation. We reported two teenage boys with sever low back pain and sciatica during soccer play that ultimately treated with diagnosis of slipped vertebral apophysis.

**KEY WORDS:** Ring Apophysis, vertebral fracture, sciatica, low back pain, disc herniation.

JRMS 2009; 14(1): 63-66

**S**lipped vertebral apophysis (Apophyseal Ring Avulsion) is very rare.<sup>1-14</sup> This lesion occurs in pediatric age group and young adult because fusion between ring apophysis and vertebral body do not occur fully until the skeletal growth, i.e. the age of 18-25 years. In children and young adults, specially in athletes, diagnosed for lumbar disc herniation, this lesion may be the proper diagnosis.<sup>3,5,7,8,9,11</sup> Although most of these lesions occur in lower lumbar area<sup>4,7,9,11,15,16</sup>, we saw these lesions in upper lumbar region as presented below.

**Case presentation**

We presented two boys with sever low back pain and sciatica during soccer play.

Case one was 13 years old and had severe sudden onset low back pain with radiation to anterior aspect of right thigh during extension of leg. Muscle powers and deep tendon reflexes were in normal range. The patient had flexion posture due to severe back pain. His pain was in territory of right L<sub>3</sub> root. He was managed conservatively for 2 months but there was no significant improvement.

Computerized tomography at L<sub>2</sub>-L<sub>3</sub> level (Figure1) showed a bony fragment similar to

an osteophyte extending to canal. In lumbosacral MRI we detected a L<sub>2</sub>-L<sub>3</sub> disc bulging with impingement of L<sub>3</sub> root and thecal sac compression (Figure 2-3). The second case was 14 years old and had sudden onset low back pain with radiation to right lower extremity for one month. He had pain in territory of L<sub>5</sub> root with intact muscle power and deep tendon reflexes. He had positive straight leg raising test (SLR test).

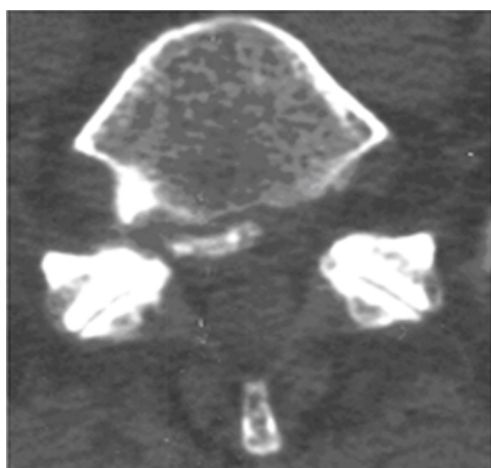Lateral lumbosacral radiography showed a small bony extension into vertebral canal at L<sub>4</sub>-L<sub>5</sub> intervertebral disc level (Figure 4). He was disable and had no recovery after several medical and conservative management and physiotherapy.

In his lumbosacral MRI, he had a herniated L<sub>4</sub>-L<sub>5</sub> disc herniation with compression effect on the thecal sac and right L<sub>5</sub> root (Figure 5).

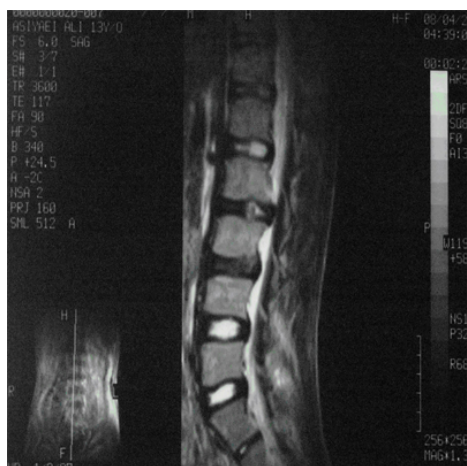Due to failed conservative management by other referral centers, we operated them in prone position. Extensive bilateral laminectomy was done. Good exposure was achieved after removal of adhesive tissue and epidural fat. Avulsed, hard and sharp particles of the posterior rim of vertebral body, including overlying cartilage of the annulus fibrosus

\*Associate professor, Department of Neurosurgery, Neurosciences Research Center, Shiraz University of Medical Sciences, Shiraz, Iran.

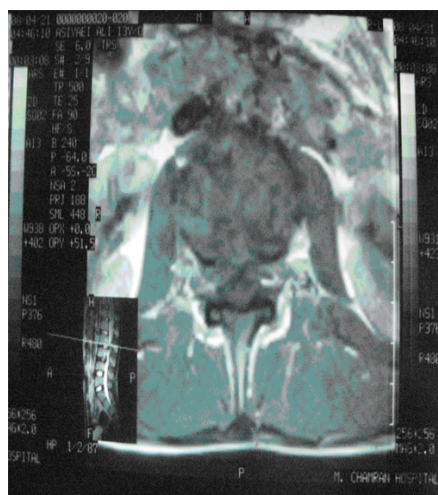
Correspondence to: Majid Reza Farrokhi, Associate professor, Department of Neurosurgery, Neurosciences Research Center, Shiraz University of Medical Sciences, Shiraz, Iran. E-mail: farokhim@sums.ac.ir




**Figure 1.** Computerized CT-scan from L2-L3 intervertebral disc. Note the avulsed bony particle from apophyseal rim.



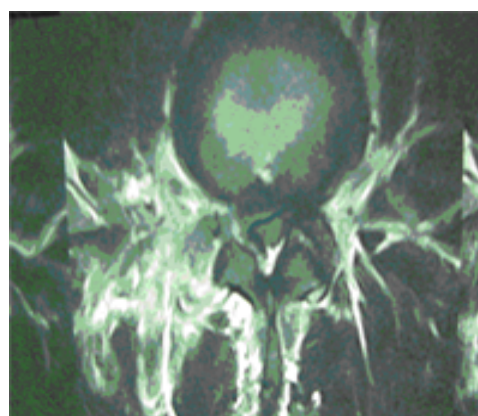
**Figure 2.** Intervertebral disc herniation at level of L2-L3 in sagittal view.



**Figure 3.** MRI (axial view) from L2-L3 intervertebral disc.



**Figure 4.** Lateral lumbar X-ray .Small bony particle adjacent to posterior margin of L4 rim is seen



**Figure 5.** MRI(axial view) from L4-L5 intervertebral disc .

similar to Takata classification type-II were seen. These particles were irregular in shape because there was some bone in the fragment. Associated herniated intervertebral disc was also seen. Retropulsed bony fragment was removed after careful separation from peripheral tissue. Then herniated intervertebral disc was removed through discectomy procedure. Their problems were completely relieved after the operations.

### Discussion

Superior and inferior surface of a developing vertebra are covered by thin cartilaginous plate. These cartilaginous plates are thickened peripherally and called ring apophysis.

The calcification of the cartilaginous rim occurs around age 13 and fused with the ver-

tebral body by the end of skeletal growth, i.e. by the age of 18-25 years.<sup>3,7,9,10,11</sup>

The development occurs at different rates in various spinal segments. The progress is faster in females than in males. Intervertebral disc of immature spine is fastened to the ring apophysis by the outermost fibers of annulus fibrosis (Sharpey's fibers).<sup>3</sup> Avulsion of lumbar vertebral apophyseal rim is very rare and there are two possible mechanisms by which the fracture can occur. First, the force transmitted to Sharpey's Fibers by annulus pulpous during herniation may cause disruption at the weak point of osteocartilagenous junction, thus resulting in an avulsion fracture. Second, migration of the nucleus pulpous may occur through the weak point, similar to the mechanism which results in limbus vertebra.<sup>3,7,10</sup>

Apophyseal avulsion is a very rare lesion and accurate diagnosis is often delayed because of concerns for neoplasm, infection and spondylolisthesis.<sup>4, 11-13,17</sup>

Takata et al<sup>3</sup> have classified these fractures in three types on basis of CT-scan studies: type I, a simple separation of the entire arcuate posterior margin of the vertebra, type II, an avulsion fracture of the posterior rim of the vertebral body, including the overlying cartilage of the annulus fibrosus, resulting in a thicker and larger fragment and type III, a more localized fracture involving a large amount of the vertebral body so that the resulting fragment is larger than the vertebral rim.<sup>3,17</sup> According to Ta-

kata classification, type I and type II can be treated conservatively and type III and IV require surgical intervention. Surgery is also indicated when there is a failure of conservative treatment.

Epstein et al proposed an additional category: type IV, a fracture of both cephalad and caudal end plates, which spans the full length of the posterior margin of vertebral body.<sup>3,17</sup>

These fractures need to be accurately diagnosed compared to simple disc herniations, specially in children and adolescents.<sup>5,6,7,11</sup> These type of fractures require more suspension and knowledge for diagnosis and need more extensive exposure during laminectomy for better resection of pathology and decompression of nerve roots.<sup>3,13</sup> So, unilateral laminotomy is not recommended in these patients because mobile and sharp retropulsed particle can displace cephalad or caudal and can damage neural structures.

For early detection of epiphyseal fracture, computerized tomography is recommended to show bony component of herniated material.<sup>6,9,12</sup>

Computerized tomography scans can be a good diagnostic technique for early detection of epiphyseal slipping, so we recommend it.

### Acknowledgment

We would like to thank Ms Hosseini from Shiraz Neurosciences Research Center for her kind assistance.

### Conflict of interest

Authors have no conflicts of interest.

### Authors' Contributions

MRF: Carried out the design, coordinated the study and participated in most of the experiments and prepared the manuscript.

MSM: Participated in manuscript preparation.

All authors have read and approve the content of the manuscript.

### References

1. Brown SH, Gregory DE, McGill SM. Vertebral end-plate fractures as a result of high rate pressure loading in the nucleus of the young adult porcine spine. *J Biomech* 2008; 41(1):122-7.
2. Smorgick Y, Floman Y, Millgram MA, Anekstein Y, Pekarsky I, Mirovsky Y. Mid- to long-term outcome of disc excision in adolescent disc herniation. *Spine J* 2006; 6(4):380-4.

3. Krishnan A, Patel JG, Patel DA, Patel PR. Fracture of posterior margin of lumbar vertebral body. *Ind J Orthop* 2005; 39(1):33-8.
4. Martinez-Lage JF, Poza M, Arcas P. Avulsed lumbar vertebral rim plate in an adolescent: trauma or malformation? *Childs Nerv Syst* 1998; 14(3):131-4.
5. Sward L, Hellstrom M, Jacobsson B, Karlsson L. Vertebral ring apophysis injury in athletes. Is the etiology different in the thoracic and lumbar spine? *Am J Sports Med* 1993; 21(6):841-5.
6. Dake MD, Jacobs RP, Margolin FR. Computed tomography of posterior lumbar apophyseal ring fractures. *J Comput Assist Tomogr* 1985; 9(4):730-2.
7. Handel SF, Twiford TW, Jr., Reigel DH, Kaufman HH. Posterior lumbar apophyseal fractures. *Radiology* 1979; 130(3):629-33.
8. Lowrey JJ. Dislocated lumbar vertebral epiphysis in adolescent children. Report of three cases. *J Neurosurg* 1973; 38(2):232-4.
9. Rothfus WE, Goldberg AL, Deeb ZL, Daffner RH. MR recognition of posterior lumbar vertebral ring fracture. *J Comput Assist Tomogr* 1990; 14(5):790-4.
10. Ehni G, Schneider SJ. Posterior lumbar vertebral rim fracture and associated disc protrusion in adolescence. *J Neurosurg* 1988; 68(6):912-6.
11. Techakapuch S. Rupture of the lumbar cartilage plate into the spinal canal in an adolescent. A case report. *J Bone Joint Surg Am* 1981; 63(3):481-2.
12. Resnick D. *Diagnosis of bone and joint disorders*. 4<sup>th</sup> ed. Philadelphia: Saunders; 2002. p. 3007-15.
13. Handel SF, Twiford TW, Jr., Reigel DH, Kaufman HH. Posterior lumbar apophyseal fractures. *Radiology* 1979; 130(3):629-33.
14. Baruah RK. Osteochondral fracture of lumbar vertebra with intervertebral disc prolapse in adolescent. A case report. *Ind J Orthop* 1993; 27(2):130-1.
15. Bradford DS, Garcia A. Lumbar intervertebral disk herniations in children and adolescents. *Orthop Clin North Am* 1971; 2(2):583-92.
16. Callahan DJ, Pack LL, Bream RC, Hensinger RN. Intervertebral disc impingement syndrome in a child. Report of a case and suggested pathology. *Spine* 1986; 11(4):402-4.
17. Epstein NE, Epstein JA, Mauri T. Treatment of fractures of the vertebral limbus and spinal stenosis in five adolescents and five adults. *Neurosurgery* 1989; 24(4):595-604.