

Original Article**Neurosensory changes of palatal mucosa following Le Fort I osteotomy***Bijan Movahedian Attar^{*a}, Navid Farzad Far^b***Abstract**

BACKGROUND: This study evaluated the sensation of palatal mucosa before and after Le Fort I osteotomy and compared it based on whether greater palatine nerve has been dissected or not.

METHODS: Sixteen patients were studied within one week before surgery and then one week, 6 weeks, 3 months and 6 months after surgery. Four tests including sharp-blunt discrimination, cold perception, pin prick sensation and electrical stimulation were performed.

RESULTS: Mean values of electrical stimulation were significantly higher 6 months after surgery ($p < 0.05$), on the other hand mean values of pin-prick sensation were significantly lower ($p < 0.05$). All patients regardless of the condition of greater palatine nerve were responsive to cold perception and sharp-blunt discrimination 6 months after surgery.

CONCLUSIONS: Following Le Fort I osteotomy, palatal responsiveness to electrical stimulation decreases and mechanical hyper sensitization occurs. Dissection of greater palatine nerve was shown to have no effect on the results.

KEYWORDS: Le Fort I Osteotomy, Palatal Mucosa, Nerve Recovery.

JRMS 2009; 14(5): 269-275

The descending palatine artery (DPA) is the most common source of bleeding during and after LFI osteotomy because of its anatomic location in the posteromedial wall of the maxillary sinus.¹ Intentional ligation of the descending palatine neurovascular bundle (DPNB) during LFI osteotomy has been advocated to reduce the potential major hemorrhage² or manage hemorrhage when it occurs.^{2,3} However DPNB might be preserved intact during surgery. The effect of DPNB ligation on neurosensory recovery of palate has not yet been precisely determined.³ However, routine ligation of an apparently intact DPNB has been criticized because of the perceived potential for aseptic necrosis of the maxilla.⁴ Additionally, the purported potential for long-term neurosensory loss after ligation of DPNB has led some to advocate its preservation in all instances.⁵ Some studies

instances.⁵ Some studies have shown that neurosensory recovery occurs after LFI osteotomy which leads to complete or partial resolution of sensory deficit.⁶⁻⁹ In spite of various branches of maxillary nerve being cut during this surgery, patients rarely complain about postsurgical neurosensory deficit.⁶ After all, during down-fracture technique, DPNB might be dissected intentionally or inadvertently and considering its important role in sensation and perfusion of the palate, it can cause untoward consequences for the patients.

However, there are many researches regarding neurosensory recovery following Le Fort I osteotomy, but they mostly discuss changes that occur in facial skin and teeth. The objective of this prospective study is evaluation of sensation of palatal mucosa before and after Le Fort I osteotomy and having compari-

^a Department of Oral and Maxillofacial Surgery, School of Dentistry, Torabinejad Dental Research Center, Isfahan University of Medical Sciences, Isfahan, Iran.

^b Dentist, School of Dentistry, Isfahan University of Medical Sciences, Isfahan, Iran.

* Corresponding Author

E-mail: b_movahedian@dnt.mui.ac.ir

son between cases, based on whether DPNB has been dissected or not.

Methods

The study group for this investigation consisted of 16 adults (3 males and 13 females) who were consecutively operated over 7 months. The mean age of the group was 20.5 years, with a range of 18 to 27. All the patients underwent LFI osteotomy alone or simultaneously with BSSO or genioplasty. Patients with history of systemic disease leading to hospitalization or history of trauma in maxillofacial region were excluded.

Surgical Procedure

All surgeries were performed by one maxillofacial surgeon. A standard upper buccal sulcus incision was made from tooth 3 to 14 using scalpel. Then bone cuts at the LFI level were made by a reciprocating saw. The pterygoid plates and the nasal septum and the lateral nasal walls were separated by a series of osteotomies. After down fracture and mobilization, the maxilla was placed in the final position as planned and rigidly fixed by four titanium miniplates, each plate held by 4 screws. Preservation or division of the greater palatine nerve (GPN) was recorded.

Protocols for Testing

For all tests, two standard sites were chosen to be tested on each side of the palate, half way between the midpalatal raphe and the marginal gingiva on the line passing through inter proximal surfaces of 1st and 2nd molars on both sides. All tests were performed by one investigator. Tests were first carried out randomly on left or right side and the patients were asked to keep their eyes closed for the entire test in order to avoid any conditioning. Tests were performed once preoperatively and then 7 days, 6 weeks, 3 months and 6 months after operation. Pre-operative testing allowed direct comparison to be made with patients acting on their own control.

Methods of Testing

Pin-Prick Sensation: A strain gauge (CORREX

Company, Switzerland) with a range of 25 to 250 Newton was modified by luting a sharp needlepoint to the lever arm. The needle point was applied to the predetermined area of the palatal mucosa and the pressure increased until the patient had a sharp sensation rather than dull and announced it by raising his hands. Each hemipalate was tested 10 times and the mean strain gauge value was recorded.

Electrical Stimulation: For this test the pulp tester values of the greater palatine nerve were recorded. Measurement was done 10 times for each side and the mean value for each side was recorded.

Cold Sensation: The method that used in this study was inspired by Minnesota thermal disks, which is consisted of 4 disks, made of copper, stainless steel, glass and poly vinyl chloride (PVC). A normal person would always indicate copper and PVC disks as "cold" and "warm" respectively, although both disks are at room temperature. In this study only copper and PVC disks were used. Normally the copper disk should be felt colder than the other one. This test was repeated 10 times on each hemipalate and 8 or more correct responses were considered as positive.

Sharp-Blunt Discrimination: For this test, an applicator was used which consisted of two heads, one 0.5 mm and another 4 mm in diameter. For standardizing the test, the applicator was installed on the strain gauge and pressed against the palatal mucosa with 25 Newton. Two heads were used ten times on each hemipalate, each time saying the numbers "one" and "two". Scoring criteria was the same as the ones used for cold sensation.

Results

In 12 patients, the greater palatine bundles were sectioned: 3 bilaterally and 9 unilaterally. The 15 hemipalates with recorded division of the greater palatine nerve (GPN) were analyzed apart from the 17 hemipalates in which the nerve was grossly intact.

Intact Greater Palatine Bundles

Sharp-Blunt Discrimination: In one week, only one (5.9%) out of 17 hemipalates who examined was able to distinguish a sharp object from blunt one. Six weeks postoperative, 11 hemipalates (64.7%) responded positively which exceeded to 17 (100%) after the third month. (Table 1)

Cold Sensation: In one week, 17 hemipalates were examined. Of these, 3 (17.6%) had cold

sensation which exceeded to 15 (88.2%) after six weeks and from the third month on, both sides of all 17 patients (100%) had cold sensation. (Table 1)

Electrical Stimulation: Chart 1 demonstrates mean electrical stimulation values. The highest mean values were recorded in 6th week post operative. At 6th months mean electrical stimulation values were significantly different from preoperative values. ($p < 0.001$) (Table 2)

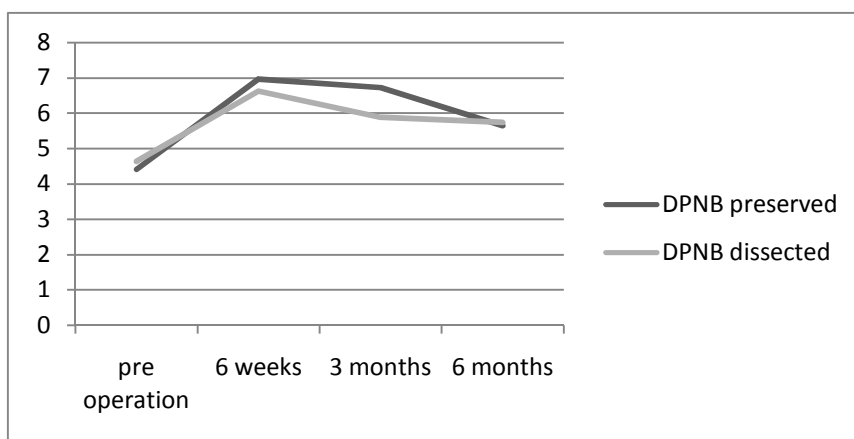


Chart 1. Mean values of electrical stimulation

Table 1. Sharp-blunt discrimination (SBD) and cold sensation in patients with intact greater palatine bundles

Examination time	Pre operative	1 week	6 weeks	3 months	6 months
No. of hemipalates examined	17	17	17	17	17
SBD present	17 (100%)	1 (5.9%)	11 (64.7%)	17 (100%)	17 (100%)
Cold sensation present	17 (100%)	3 (17.6%)	15 (88.2%)	17 (100%)	17 (100%)

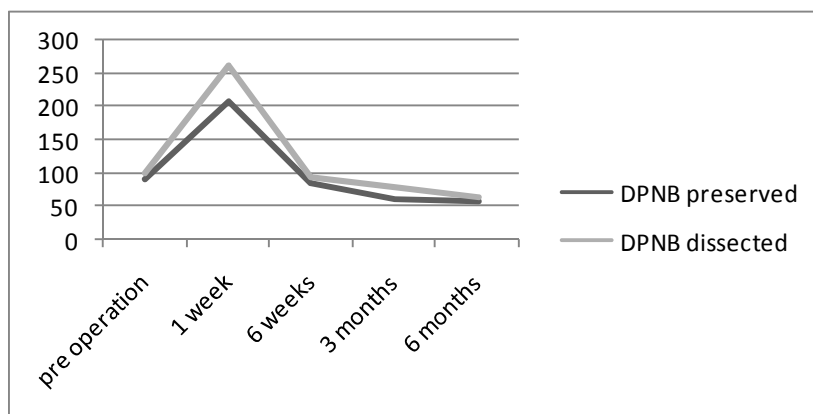


Chart 2. Mean values of strain gauge

Table 2. Mean values of electrical stimulator in patients with intact greater palatine bundles

Examination time	Pre operative	1 week	6 weeks	3 months	6 months
No. of hemipalates examined	17	17	17	17	17
No. of hemipalates responding	17 (100%)	3 (17.6%)	15 (88.2%)	16 (94.1%)	17 (100%)
Mean values of electrical stimulator	4.41	6	6.96	6.71	5.64

Pin-Prick Sensation: Chart 2 demonstrates the mean strain gauge values. The highest mean values were recorded in first week postoperative. One week after surgery 3 out of 17 hemipalates (17.6%) were able to feel the stimulation. This rate increased to 15 (88.2%) at sixth week and from the third month on all the hemipalates were responsive to this stimulation. Among these, sensation was present at preoperative level or even was lower in 14 hemipalates (82.3%) in sixth month. Mean strain gauge values at sixth month were significantly lower than preoperative values ($p < 0.05$). (Table 3)

Divided Greater Palatine Bundles

Sharp-Blunt Discrimination: After one week, none of the 15 hemipalates responded to this test. Meanwhile, in sixth month 4 (26.7%) and in third month 14 (93.3%) hemipalates were responsive positively. In sixth month all 15 hemipalates (100%) could distinguish sharp stimulus from blunt one. (Table 4)

Cold Sensation: After one week none of the 15 hemipalates responded to this test. Whereas, 9

(60%) responded positively at sixth week and from third month on all 15 (100%) sides could distinguish cold stimuli. (Table 4)

Electrical Stimulation: Mean electrical stimulation values are summarized in chart 1. In one week after surgery none of the 15 hemipalates responded to this test. In sixth week 8 (53.3%) and in third month 13 hemipalates (86.6%) were responsive. Six months after surgery all 15 hemipalates responded to this test. Among these, sensation was at preoperative level only in 6 hemipalates (40%). Mean values in sixth month was significantly different from preoperative mean value ($p < 0.05$). (Table 5)

Pin-Prick Sensation: Chart 2 shows the mean strain gauge values. In one week after surgery 2 (13.3%) hemipalates, after six weeks 9 (60%) and in third month and afterward all (100%) of the hemipalates responded to this test. Preoperative strain gauge mean values were significantly different from those in sixth month after surgery ($p < 0.05$). Strain gauge values in all 15 hemipalates in sixth month were lower than preoperative values. (Table 6)

Table 3. Mean values of strain gauge in patients with intact greater palatine bundles

Examination time	Pre operative	1 week	6 weeks	3 months	6 months
No. of hemipalates examined	17	17	17	17	17
No. of hemipalates responding	17 (100%)	3 (17.6%)	15 (88.2%)	17 (100%)	17 (100%)
Mean values of strain gauge	90	206.6	86	60.3	58.5

Table 4. Sharp-blunt discrimination (SBD) and cold sensation in patients with divided greater palatine bundles

Examination time	Pre operative	1 week	6 weeks	3 months	6 months
No. of hemipalates examined	15	15	15	15	15
SBD present	15 (100%)	0 (0%)	4 (26.7%)	14 (93.3%)	15 (100%)
Cold sensation present	15 (100%)	0 (0%)	9 (60%)	15 (100%)	15 (100%)

Table 5. Mean values of electrical stimulator in patients with divided greater palatine bundles

Examination time	Pre operative	1 week	6 weeks	3 months	6 months
No. of hemipalates examined	15	15	15	15	15
No. of hemipalates responding	15 (100%)	0 (0%)	8 (53.3%)	13 (86.6%)	15 (100%)
Mean values of electrical stimulator	4.63	-	6.62	5.88	5.73

Table 6. Mean values of strain gauge in patients with divided greater palatine bundles

Examination time	Pre operative	1 week	6 weeks	3 months	6 months
No. of hemipalates examined	15	15	15	15	15
No. of hemipalates responding	15 (100%)	2 (13.33%)	9 (60%)	15 (100%)	15 (100%)
Mean values of strain gauge	92.66	262.5	92.22	76	62.33

None of the tests at any time showed any significant differences between the two groups of hemipalates except for pin-prick values in third month ($p < 0.05$).

Patients with asymmetric dissection of GPN had the greatest decrease of pin-prick values after 6 months comparing to patients in whom GPN was whether symmetrically preserved or dissected. On the other hand, those with symmetric preservation of the GPN showed the least decrease in pin-prick values.

Discussion

Among the literatures on sensory deficit following orthognathic surgery that was reviewed, mandibular osteotomies have been more widely studied than those in maxilla. Even in researches on maxilla, palatal mucousa has been of least attention comparing to teeth and skin of the face.

Nociception

In previous studies nociception has been whether not investigated or measured improperly (by means of dental probe). Shehab Al-Din ⁶ has used a reliable mean for this test for the first time which was called algesimeter and consisted of a sharp tip which was pressed against palatal mucousa and the amount of pressure could be read between 2 to 10 grams. Later another device as strain gauge was used by Bouloux ¹⁰ which resembles the one that used in this study.

Formerly, De Jongh et al ⁷ found out that prick sensation decreases after 14 months comparing to control group, although GPN was not divided. Shehab Al-Din ⁶ concluded in his study that pin-prick sensation of the palate returns to preoperative level, in case GPN is preserved. On the other hand, the same study showed that only 63% of the hemipalates in which GPN was dissected recovered their sensation to preoperative level after 6 months. Bouloux et al ¹⁰ stated that no difference in pin-prick sensation exists between operated patients with preserved GPN, operated patients with divided GPN and the control group.

In present study, the mean pin-prick sensation values in 6 months after surgery were significantly less than those of before operation (Chart 2). It means that pain threshold in the patients has lowered or in other words patients were more sensitive to this stimulus than before the operation. It was also shown that post operative nociception is not significantly different between hemipalates with preserved GPN and those with divided GPN. In addition, patients with asymmetric dissection of GPN had the greatest decrease of pin-prick values after 6 months; while those with symmetric preservation of GPN had the minimal decrease.

It is a completely new finding which has not mentioned so far in the literature and because of small sample size in this study more inves-

tigation is needed to confirm this phenomenon.

Electrical Stimulation

Electrical evaluation of peripheral sensory nerves is a precise method with reproducible results.^{11,12} Notermans (1966) was probably the first to use electrical stimulation in clinical practice.¹² Turskey and O'Connell in 1972 concluded that sensory evaluation by means of electrical current is a reliable method.¹³

As shown in chart 1, GPN did not regain its responsiveness to electrical stimulation at pre-operative level 6 months after operation which suggests some kind of blockage in neural conduction.

For the classification of lesions of peripheral nerves, we used the classification of Seddon which comprises Neuropraxia, Axonotmesis and Neurotmesis.^{14,15}

In present study sensory function was not completely recovered 6 months after operation in those cases whose GPN was grossly intact. This can be due to a conduction problem and categorized under axonotmesis. It would be clear that in the other group of patients in whom GPN was dissected, the conduction problem is classified as Neurotmesis. Rosenberg et al has previously concluded the same.¹⁶

Conflict of Interests

Authors have no conflict of interests.

Authors' Contributions

BMA carried out the design, coordinated the study and did all of the surgeries, participated in most of the experiments and prepared the manuscript. NFF provided assistance in the design of the study, coordinated and carried out all the experiments and participated in manuscript preparation. Both authors have read and approved the content of the manuscript.

References

1. Lanigan DT, Hey JH, West RA. Major vascular complications of orthognathic surgery: hemorrhage associated with Le Fort I osteotomies. *J Oral Maxillofac Surg* 1990;48(6):561-73.
2. Bays RA. Orthognathic surgery: the practical use of functional principles. In: Shelton DW, Irby WB, editors. *Current advances in oral and maxillofacial surgery*. Vol 5. St Louis: Mosby; 1986. p. 144.
3. Lanigan DT, West RA. Management of postoperative hemorrhage following the Le Fort I maxillary osteotomy. *J Oral Maxillofac Surg* 1984;42(6):367-75.

Sharp-Blunt Discrimination (SBD)

SBD was one the two qualitative tests used in this study. It has been previously used by Gianni et al for orofacial sensory evaluation.^{17,18} But In the review of literature we could not find any study that has used it to evaluate palatal sensation.

In present study, in third month, all the hemipalates except one responded positively to this test regardless of whether GPN was preserved or not. Positive response to SBD returned earlier in patients whose GPN were preserved.

Cold Perception

As we could acknowledge no study before has tested cold sensation of palatal mucosa after Le Fort osteotomy. In this study, three months after surgery, all of the hemipalates regardless of the GPN status, responded to this test positively. However, again the positive response returned slightly earlier in those with preserved GPN.

Conclusions

Following Le Fort osteotomy, pain threshold decreases and sensitivity to electrical stimulus does not return to preoperative level. Sharp-blunt discrimination and cold perception return to preoperative condition. Dissection of GPN does not adversely affect the recovery of palatal sensation after 6 months.

4. Lanigan DT, Hey JH, West RA. Aseptic necrosis following maxillary osteotomies: report of 36 cases. *J Oral Maxillofac Surg* 1990;48(2):142-56.
5. Van Sickles JE. Prevention and management of complications in orthognathic surgery. In: Peterson LJ, Indresano AT, Marciani RD, Roser SM. *Peterson's principles of oral and maxillofacial surgery*. Philadelphia: Lippincott Williams & Wilkins; 1992. p. 1472.
6. Shehab Al-Din OF, Coghlan KM, Magennis P. Sensory nerve disturbance following Le Fort I osteotomy. *Int J Oral Maxillofac Surg* 1996;25(1):13-9.
7. De Jongh M, Barnard D, Birnie D. Sensory nerve morbidity following Le Fort I ostotomy. *J Maxillofac Surg* 1986;14(1):10-3.
8. Karas ND, Boyd SB, Sinn DP. Recovery of neurosensory function following orthognathic surgery. *J Oral Maxillofac Surg* 1990;48(2):124-34.
9. Posnick JC, al-Qattan MM, Pron G. Facial sensibility in adolescents with and without clefts 1 year after undergoing Le Fort I osteotomy. *Plast Reconstr Surg* 1994;94(3):431-5.
10. Bouloux GF, Bays RA. Neurosensory recovery after ligation of the descending palatine neurovascular bundle during Le Fort I osteotomy. *J Oral Maxillofac Surg* 2000;58(8):841-5; discussion 846.
11. Notermans SLH. Measurement of the pain threshold determined by electrical stimulation and its clinical application. II. Clinical application in neurological and neurosurgical patients. *Neurology* 1967;17(1):58-73.
12. Notermans SLH. Measurement of the pain threshold determined by electrical stimulation and its clinical application. I. Method and factors possibly influencing the pain threshold. *Neurology* 1966;16(11):1071-86.
13. Tursky B, O'Connell D. Reliability and interjudgment predictability of subjective judgments of electrocutaneous stimulation. *Psychophysiology* 1972;9(3):290-5.
14. Seddon HJ. Three types of nerve injury. *Brain* 1943;66(4):237-49.
15. Mackinnon S, Dellon AL. *Surgery of the peripheral nerve*. New York: Thieme; 1988. p. 35-63.
16. Rosenberg A, Sailer HF. A prospective study on changes in the sensibility of the oral mucosa and the mucosa of the upper lip after Le Fort I osteotomy. *J Craniomaxillofac Surg* 1994;22(5):286-93.
17. Gianni AB, Biglioli F, Brevi B, Brusati R. Recovery of infraorbital nerve function after zygomaticomaxillary cheek pedicled flap. *J Craniomaxillofac Surg* 1995;23(5):325-31.
18. Gianni AB, D'Orto O, Biglioli F, Bozzetti A, Brusati R. Neurosensory alterations of the inferior alveolar and mental nerve after genioplasty alone or associated with sagittal osteotomy of the mandibular ramus. *J Craniomaxillofac Surg* 2002;30(5):295-303.