

Case Diagnosis**An old man with a mass in the retropharyngeal space**

Mohammad Hashemi-Shahri^a, Roya Alavi-Naini^a, Taghi Naserpour^a,
Batool Sharifi-Mood^{*a}, Farshid Fayyaz-Jahani^b

Abstract

In this article, we discuss clinical manifestations, laboratory results, and radiological findings in an old man with suppurative tender mass in the neck, accompanied by, fever, weight loss, malaise, fatigue, night sweat, cough, vomiting, and dysphagia. Pharyngeal exam revealed a huge retropharyngeal abscess.

JRMS 2009; 14(3): 197-199

An 84 year-old man from Zahedan (South-Eastern Iran) came with an 11-month history of continuous non-radiating pain in the neck. He noticed swelling and bilateral neck sinus tracts with suppurative discharge 6 months later. During the first months of illness, he received variable medications including antibiotics, non steroidal anti-inflammatory drugs with no response. Three months before admission, fever, malaise, fatigue and night sweat along with cough, vomiting, weight loss occurred and a month before hospitalization, it progressed to dysphagia. He denied any contact with animals and had no history of recent travel. On physical examination he looked normal except for bilateral neck swelling with multiple draining sinuses, local tenderness and fluctuation. Examination of retropharyngeal space showed a huge mass just behind the tonsillar pillars. He was referred to surgeon and biopsy was taken under anesthesia. WBC = 10,000 cells/mm³ with 61% neutrophils, 33% lymphocytes, 3% monocytes, and 2% eosinophils. Hgb = 11.1g/dL platlet = 428,000/mm³, ESR = 55 mm/hr liver function test, urinalysis and biochemical tests were within normal limits. Chest X ray was normal. Axial computed tomography and sagittal

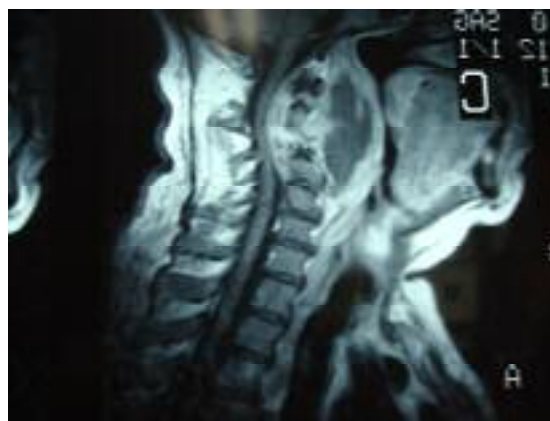

Figure 1. Sagittal T2-weighted MRI demonstrating a collection consistent with abscess formation.

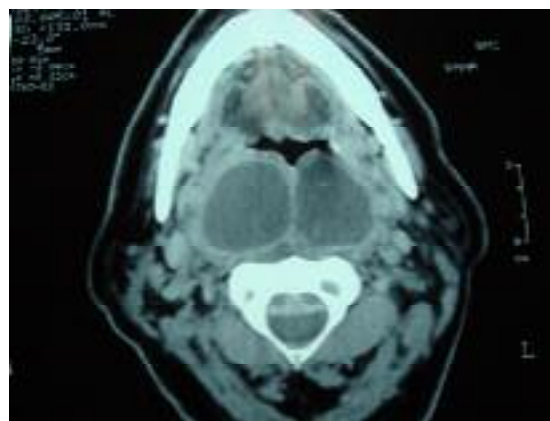


Figure 2. Axial CT scan shows abscess and calcification in the abscess and destruction of vertebral body (vertebral osteolysis).

^a Research Center for Infectious Diseases and Tropical Medicine, Zahedan University of Medical Sciences, Zahedan, Iran.

^b Boo-Ali Hospital, Zahedan University of Medical Sciences, Zahedan, Iran.

*Corresponding Author

E-mail: batoolsharifi@yahoo.com

T2- weighted MRI were as seen in figure 1, 2. A biopsy was taken along with aspirated pus sent to the laboratory for staining, culture, and histopathological examination.

What Is The Diagnosis?

Diagnosis: Tuberculous Retropharyngeal Abscess

Retropharyngeal tuberculous abscess is a rare presentation of tuberculosis and should be suspected in every person who presents with a destructive lesion of the cervical vertebra and a retropharyngeal mass.^{1,2,4} The classic symptoms of patients with tuberculous retropharyngeal abscess are dysphagia, odynophagia, and airway obstruction. Classic symptoms of tuberculosis are usually not observed.^{3,4} Diagnosis is based on radiological and bacteriological assessment.² Treatment with antituberculosis drugs leads to an excellent outcome.⁵ Magnetic Resonance Imaging plays an important role in early diagnosis of cervical spondylodiscitis because conventional radiographs and CT scans may be unremarkable at early stages.^{6,7} The reported case was an old man who was referred to the hospital with fever, malaise, night sweat, cough, vomiting,

weight loss and bilateral draining neck sinuses with discharge following six months of cervical pain. Fortunately he did not have odynophagia or signs of airway obstruction. Axial CT scan showed a retropharyngeal abscess with calcification and destruction of vertebral bodies (C1-C3) which were confirmed by MRI. Despite vertebral destruction, the patient had no neurologic deficit. Finally, histopathologic report of the excised specimen revealed caseous necrosis and granuloma formation compatible with TB. Zeil-Nelson and auramine rhodamine staining of the aspirated pus was positive for acid fast bacilli. Culture on Lowenstein-Johnson media was also positive for mycobacterium tuberculosis after 3 weeks of incubation. The patient was treated with anti-tuberculous drugs according to national TB guideline. Follow-up showed complete clinical response without sequelae and need for surgical reconstruction.

Retropharyngeal abscess is a very rare disease, and in developing countries with high endemicity of tuberculosis,⁸ this presentation should be considered in any patient presenting with neck swelling and sinus tract formation to ensure adequate attention for rapid treatment.

Conflict of Interests

Authors have no conflict of interests.

Authors' Contributions

BShM prepared the manuscript and was coordinator. RAN participated in manuscript preparation (revised it). TN carried out all the diagnostic tests. FFJ did the follow-up for the patient and took all photos. MHSh helped writing and preparing the manuscript.

All authors have read and approved the content of the manuscript.

References

1. Oktem F, Guvenc MG, Yilmaz S, Edizer DT, Kara B. Asymptomatic retropharyngeal abscess related to cervical Pott's disease. *Am J Otolaryngol* 2006;27(4):278-80.
2. Rosenberg AE. Bones, joints and soft tissue tumors. In: Cotran RS, Robbins SL, Kumar V, editors. *Robbins pathologic basis of disease*. Philadelphia: WB Saunders; 1994. P. 1213-73.
3. Leibert E, Haralambou G. Spinal tuberculosis. In: Rom WN, Garay SM, editors. *Tuberculosis*. Philadelphia: Lippincott Williams and Wilkins; 2004. P. 565-77.
4. Melchor Diaz MA, Domingo CC, Monge JR, Marino EJ, Ontanon MM. Tuberculous retropharyngeal abscess in an HIV patient. Report of a case. *Acta Otorrinolaringol Esp* 1993;44(6):467-70.
5. Benhammou A, Bencheikh R, Benbouzid MA, Boulaich M, Essakali L, Kzadri M. Cervical Pott's disease revealed by retropharyngeal abscesses. *Rev Stomatol Chir Maxillofac* 2007;108(6):543-6.

6. Sharif HS, Morgan JL, al Shahed MS, al Thagafi MY. Role of CT and MR imaging in the management of tuberculous spondylitis. *Radiol Clin North Am* 1995;33(4):787-804.
7. Lutterbey G, Lauer G. Spine. In: Vahlensieck M, Genant HK, Reiser M, editors. *MRI of the musculoskeletal system*. Philadelphia: Lippincott Williams & Wilkins; 2000. P. 19-47.
8. Sharifi-Mood B, Kheikha F. Seroprevalence of human immunodeficiency virus (HIV) in pregnant women in Zahedan, Southeastern Iran. *J Res Med Sci* 2008 Jun;13(4):186-8.