

Case Report**Hoarseness, a major presenting symptom
in a patient with multiple sclerosis***Vahid Shaygannejad*, Mojtaba Kazemi**, Ahmadreza Okhovat******Abstract**

Multiple sclerosis (MS) is a chronic neurological disease with different presenting symptoms. We introduce a case of MS presented with hoarseness. A 38-year-old man complaining of hoarseness was referred to our clinic for a sudden palsy of right IX and X cranial nerves. Neurological examination showed signs of right IX and X cranial nerves paralysis, hoarseness, fine unidirectional horizontal nystagmus to the left and bilateral loss of cutaneous abdominal reflexes. Brain MRI revealed McDonald criteria for diagnosing MS. Pulse therapy was started and he recovered in 2 months. Beta interferon 1a began for him and in 9 months follow up, no relapse occurred.

KEYWORDS: Multiple sclerosis, hoarseness, presenting symptom.

JRMS 2008; 13(5): 281-282

Multiple sclerosis (MS), initially described by Charcot in 1877, is a chronic neurological disease characterized by episodes of nervous system dysfunction that remit and recur over several decades. Commonly, long periods of normal function occur between these episodes. Common manifestations include paresthesia, upper motor neuron disease, cerebellar symptoms, language disorders, cognitive impairment, tremor, autonomic nervous system disorder, and cranial nerve disorders such as diplopia, dysarthria, and dysphagia.¹ Typical symptoms of voice dysfunction in patients with multiple sclerosis (MS) are summarized below.²

Voice symptoms may include hoarseness and poor control of volume and pitch.

Speech problems are more common and have been characterized as "scanning speech," in which each syllable is produced slowly and hesitantly with a pause after every syllable.

Here in, we report a case of MS with an uncommon presentation, hoarseness.

Case presentation

A 38-year-old man complaining of hoarseness was referred to our clinic for a sudden palsy of right IX and X cranial nerves (figure 1). He was working as a banker, but along this, he was an amateur singer. There was no past history of smoking, laryngitis, or other laryngeal trauma. His history included interrupted micturition intermittently since 10 years ago. At that time, urologic consultation including urodynamic evaluation and cystoscopy was normal. About nine years ago, he suddenly developed horizontal diplopia for which he took oral corticosteroids and vitamin E without a definite diagnosis, and diplopia resolved after a few days. He also reported a history of left upper limb numbness for 2 weeks, about 4 years ago. Electro-diagnostic survey including EMG-NCV

*Associate Professor, Department of Neurology, Isfahan University of Medical Sciences, Isfahan, Iran.

**Clinical Resident, Department of Neurology, Isfahan University of Medical Sciences, Isfahan, Iran.

***Associate Professor, Department of Otolaryngology, Isfahan University of Medical Sciences, Isfahan, Iran.

Correspondence to: Dr Vahid Shaygannejad, Department of Neurology, Isfahan University of Medical Sciences, Isfahan, Iran.
E-mail: shaygannejad@med.mui.ac.ir

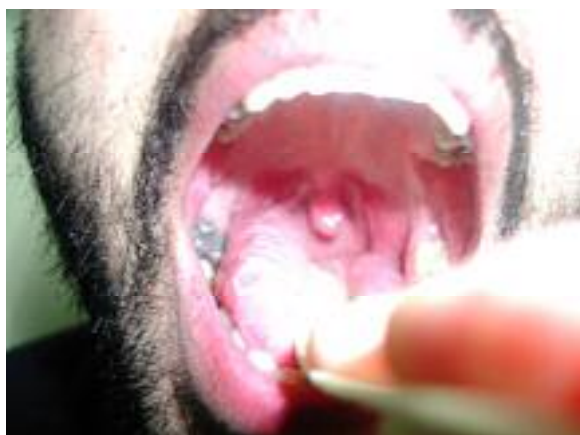

Figure 1. Paralysis of right IX and X cranial nerves.

was normal and after symptomatic treatment, he recovered. Family history for multiple sclerosis or laryngeal diseases was absent.

Neurological examination showed hoarseness, fine unidirectional horizontal nystagmus to the left, decreased right gag reflex, deviation of uvula to the left and bilateral loss of cutaneous abdominal reflexes. Laryngeal CT after admission showed no focal lesions. Brain MRI revealed multiple white matter high signal lesions on fluid-attenuated inversion recovery (FLAIR) images and high signal intensity on DWI and T2W images. The lesions fulfilled MRI data of McDonald criteria on multiple sclerosis (figure 2). To exclude MS mimics, we checked many serologic tests including ANA, anti-ds-DNA, antiphospholipid antibodies (IgM, IgG), anticardiolipin antibodies (IgM, IgG), lupus anticoagulant antibody, serum vitamin B₁₂ level, HTLV₁ antibody and HIV antibody, which were totally within normal limits. Visual evoked potential had normal latency and configuration in both eyes as well. CSF analysis was not performed. According to the above-mentioned information, the diagnosis of clinically definite multiple sclerosis was considered and pulse therapy was started for the

patient (methyl prednisolone succinate 1 g per day for 5 days). His symptoms recovered gradually in 2 months. Beta interferon 1a began for him and in 9 months follow up, no relapse occurred.

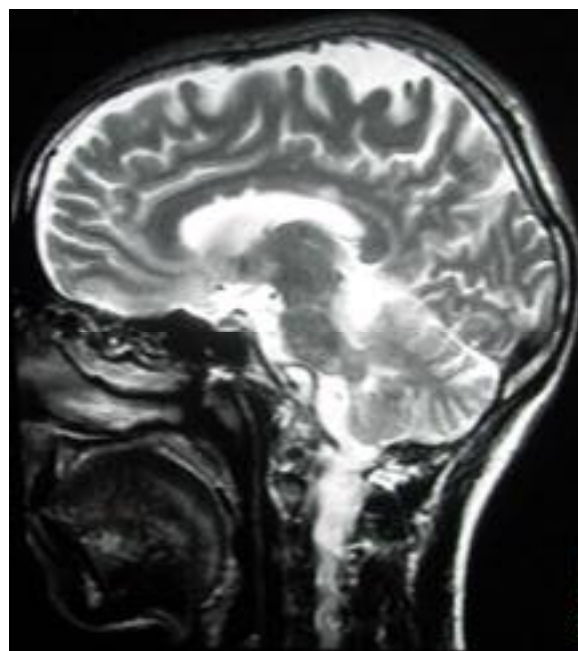


Figure 2. MRI images of the presented case.

Discussion

This report introduced a rare presenting symptom in multiple sclerosis patients. Among cranial nerves, paralyzes of glossopharyngeal and vagus nerves are hardly ever reported in the literature as a major presenting symptom of MS especially in the beginning of the disease. Sclerotic involvements of these nerves can happen along their pathways through brainstem and less probably in their nuclei in tegmentum of brainstem. Sudden onset of hoarseness in a young subject should add the possibility of multiple sclerosis to the list of differential diagnoses, which mainly involves local laryngeal diseases.

References

1. Feijo AV, Parente MA, Behlau M, Haussen S, de Veccino MC, Martignago BC. **Acoustic analysis of voice in multiple sclerosis patients.** *J Voice* 2004; 18: 341-7.
2. **What are the typical symptoms of voice dysfunction in patients with multiple sclerosis?** *Voice Dysfunction in Neurological Disorders*. Available at: <http://www.voiceproblem.org/disorders/nproblems/ms.asp>.