

# COVID-19-associated mucormycosis: A review of an emergent epidemic fungal infection in the era of COVID-19 pandemic

Vinay Chamola<sup>1,2</sup>, Rasoul Mohammadi<sup>3</sup>, Harish Nair<sup>4</sup>, Adit Goyal<sup>5</sup>, Aarya Patel<sup>6</sup>, Vikas Hassija<sup>5</sup>, Matteo Bassetti<sup>7</sup>, Pratik Narang<sup>8</sup>, Roger Paredes<sup>9</sup>, Jose R. Santos<sup>10</sup>, Seyed Jamal Hashemi<sup>11</sup>, Mahnaz Pejman Sani<sup>12</sup>, Kiana Shirani<sup>13</sup>, Neda Alijani<sup>14</sup>, Bahareh Abtahi Naeini<sup>15,16</sup>, Mohsen Pourazizi<sup>17</sup>, Seyed Hamidreza Abtahi<sup>18</sup>, Farzin Khorvash<sup>19</sup>, Mahdi Khanjari<sup>20</sup>, Kazem Ahmadikia<sup>11</sup>

<sup>1</sup>Medsupervision Pvt. Ltd., Faridabad, Haryana, India, <sup>2</sup>Department of Electrical and Electronics Engineering, Internet of Things Research Group, Birla Institute of Technology and Sciences, Pilani Campus, Pilani, Rajasthan, India, <sup>3</sup>Department of Medical Parasitology and Mycology, School of Medicine, Infectious Diseases and Tropical Medicine Research Center, Isfahan University of Medical Sciences, Isfahan, Iran, <sup>4</sup>Usher Institute, Edinburgh Medical School, University of Edinburgh, Edinburgh, Scotland EH8 9 AG, <sup>5</sup>Department of Computer Science and IT, Jaypee Institute of Information Technology, Noida, Uttar Pradesh, India, <sup>6</sup>Vitrana, a Lifesciences and Pharmacovigilance Company, Noida, Uttar Pradesh, India, <sup>7</sup>Department of Health Sciences, University of Genoa and Policlinico San Martino IRCCS Hospital, Genoa, Italy, <sup>8</sup>Department of Computer Science and Information Systems, Birla Institute of Technology and Sciences, Pilani Campus, Pilani, Rajasthan India, <sup>9</sup>Department of Infectious Diseases, irsiCaixa AIDS Research Institute, Germans Trias i Pujol University Hospital, Badalona, Spain, <sup>10</sup>Department of Infectious Diseases, AIDS Fight Foundation, Germans Trias i Pujol University Hospital, Badalona, Spain, <sup>11</sup>Department of Medical Parasitology and Mycology, School of Public Health, Tehran University of Medical Sciences, Tehran, Iran, <sup>12</sup>Endocrinology and Metabolism Research Center, Endocrinology and Metabolism Clinical Sciences Institute, Tehran University of Medical Sciences, Tehran, Iran, <sup>13</sup>Nosocomial Infection Research Center, Isfahan University of Medical Sciences, Isfahan, Iran, <sup>14</sup>Department of Infectious Disease, Shariati Hospital, Tehran University of Medical Sciences, Tehran, Iran, <sup>15</sup>Division of Pediatric Dermatology, Department of Pediatrics, Imam Hossein Children's Hospital, Isfahan University of Medical Sciences, Isfahan, Iran, <sup>16</sup>Skin Diseases and Leishmaniasis Research Center, Isfahan University of Medical Sciences, Isfahan, Iran, <sup>17</sup>Isfahan Eye Research Center, Department of Ophthalmology, Isfahan University of Medical Sciences, Isfahan, Iran, <sup>18</sup>Department of Otolaryngology, School of Medicine, Isfahan University of Medical Sciences, Isfahan, Iran, <sup>19</sup>Acquired Immunodeficiency Research Center, Isfahan University of Medical Sciences, Isfahan, Iran, <sup>20</sup>Department of Burn and Regenerative Medicine Research Center, School of Medicine, Guilan University of Medical Sciences, Rasht, Iran

At a time when the COVID-19's second wave is still picking up in countries like India, a number of reports describe the potential association with a rise in the number of cases of mucormycosis, commonly known as the black fungus. This fungal infection has been around for centuries and affects those people whose immunity has been compromised due to severe health conditions. In this article, we provide a detailed overview of mucormycosis and discuss how COVID-19 could have caused a sudden spike in an otherwise rare disease in countries like India. The article discusses the various symptoms of the disease, class of people most vulnerable to this infection, preventive measures to avoid the disease, and various treatments that exist in clinical practice and research to manage the disease.

**Keywords:** Black fungus, coronavirus, COVID-19, fungal infection, mucormycosis, pandemic

**How to cite this article:** Chamola V, Mohammadi R, Nair H, Goyal A, Patel A, Hassija V, *et al.* COVID-19-associated mucormycosis: A review of an emergent epidemic fungal infection in the era of COVID-19 pandemic. *J Res Med Sci* 2022;27:57.

## Access this article online

Quick Response Code:



Website:

www.jmsjournal.net

DOI:

10.4103/jrms.jrms\_1090\_21

This is an open access journal, and articles are distributed under the terms of the Creative Commons Attribution-NonCommercial-ShareAlike 4.0 License, which allows others to remix, tweak, and build upon the work non-commercially, as long as appropriate credit is given and the new creations are licensed under the identical terms.

**For reprints contact:** WKHLRPMedknow\_reprints@wolterskluwer.com

**Address for correspondence:** Dr. Rasoul Mohammadi, Department of Medical Parasitology and Mycology, School of Medicine, Infectious Diseases and Tropical Medicine Research Center, Isfahan University of Medical Sciences, Isfahan, Iran.

E-mail: dr.rasoul\_mohammadi@yahoo.com

Dr. Kazem Ahmadikia, Department of Medical Parasitology and Mycology, School of Public Health, Tehran University of Medical Sciences, Tehran, Iran.

E-mail: kazem\_ahmadikia@yahoo.com

**Submitted:** 16-Dec-2021; **Revised:** 08-Mar-2022; **Accepted:** 14-Mar-2022; **Published:** 29-Jul-2022

## INTRODUCTION

Mucormycosis is a fungal infection associated with high morbidity and mortality.<sup>[1]</sup> The mortality rate ranges from 40% to 80% and depends on the site of infection and the underlying conditions.<sup>[2]</sup> Although the infection is caused by a group of ubiquitously distributed hyaline genera under *Mucorales* order,<sup>[1]</sup> due to angioinvasion and subsequent tissue necrosis, which make a black appearance in the tissue, the infection is popularly known as black fungus.<sup>[3]</sup> The recent rise in the number of patients with mucormycosis is alarming, and it has been attributed to the fact that COVID-19 has forced many of its victims to be administered by corticosteroids in high doses.<sup>[1]</sup> These medicines taken over a long period are necessary to cure the COVID-19 infection in some severe cases.<sup>[4]</sup> However, these immunosuppressive agents have been found to cause a negative impact of leading to mucormycosis for a few patients, especially those having health conditions like diabetes.<sup>[1]</sup> As of June 2021, India has reported over 28,000 cases of COVID-19-associated mucormycosis (CAM).<sup>[5]</sup> Moreover, cases of mucormycosis have been reported in countries such as Iran, Pakistan, and Russia.<sup>[6,7]</sup>

Mucormycosis (previously referred to as zygomycosis) is caused by a group of molds called mucormycete.<sup>[2]</sup> It grows in damp and moist environments and is common in our surroundings. The infection transmits easily because the spores are easily aerosolized, dispersed, and inhaled.<sup>[1,2,8]</sup> Mucormycosis starts in the lungs or sinus when the spores

are inhaled along with oxygen.<sup>[1,2]</sup> Due to the fact that they are present ubiquitously, the chances of inhaling these spores in daily life are quite high. It is noteworthy that the healthy immune system does not allow the infection to grow, and hence it rarely causes disease in an immunocompetent host.<sup>[2]</sup>

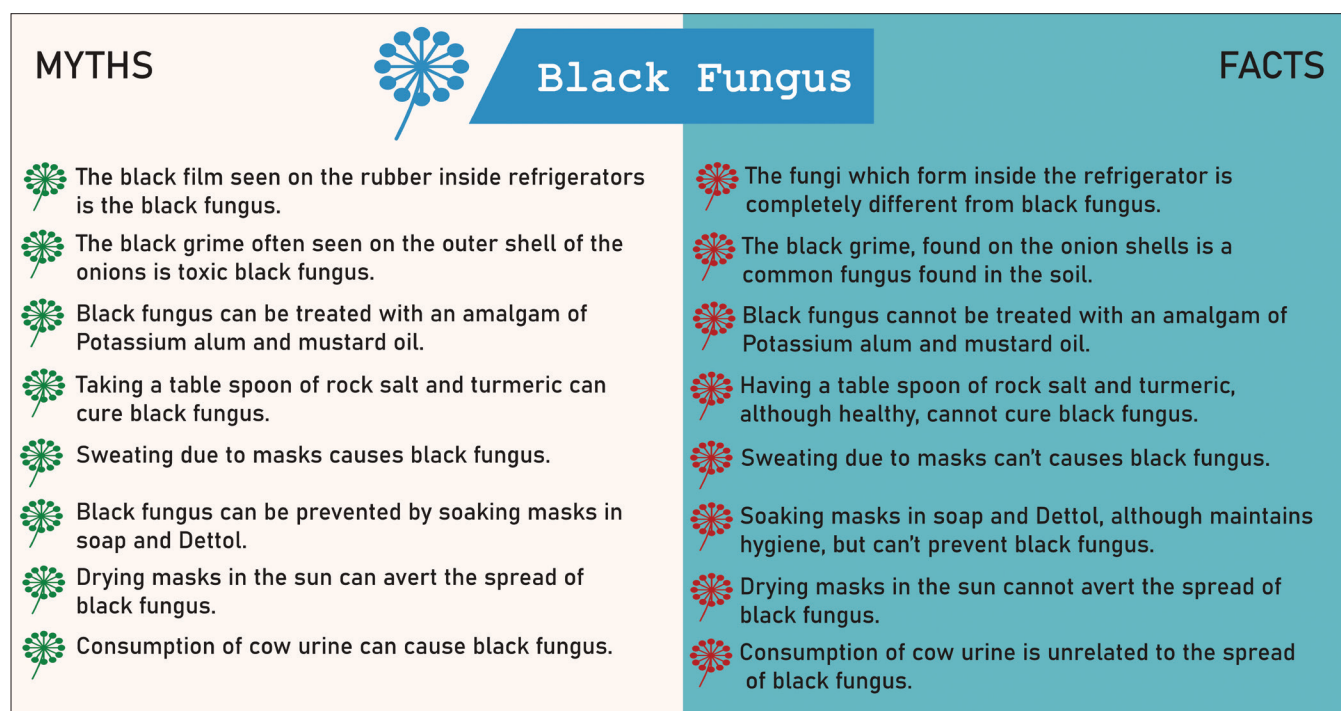## PREVIOUS WORKS AND CONTRIBUTIONS

Sahoo *et al.* provided a short case study of mucormycosis in India accompanying the COVID-19 wave.<sup>[9]</sup> Garg *et al.* gave a detailed case report of 8 patients who suffered from CAM.<sup>[10]</sup> In 2 recently published studies from Iran, 27 CAM cases were reported.<sup>[6,11]</sup> The number of studies reporting single or case series of CAM is still on an upsurge trend globally. Hoenigl *et al.* presented a detailed analysis on 80 COVID-19 affected patients suffering from mucormycosis worldwide.<sup>[7]</sup>

To the best of our knowledge, articles presenting a comprehensive overview of mucormycosis from the perspective of COVID-19 patients are scarce. In this article, we give a background on mucormycosis, explaining its epidemiology and giving some brief history and also discuss the main clinical characteristics, risk factors, diagnosis, and management of CAM.

## BACKGROUND

In general, the disease was rarely reported, and there have not been many outbreaks as such are currently happening



**Figure 1:** Debunking myths surrounding COVID-19-associated mucormycosis. Note: The figures are original figures which were drawn by ourselves and were not directly adopted from anywhere. Nonetheless, the sources and articles for the reports from which data has been taken to create Figures 2 and 3 have been provided

in COVID-19 settings. A set of 13 cases of cutaneous mucormycosis in Joplin, Missouri (USA), after a tornado in 2011, were investigated by Neblett Fanfair *et al.*<sup>[12]</sup> An outbreak of rhinocerebral mucormycosis occurred in 2006 at the pediatric oncology department of a hospital in the UK after some water damage.<sup>[13]</sup> A small outbreak of cutaneous *Rhizopus* infection due to ostomy bags in 2005 has been reported in Ohio (USA).<sup>[14]</sup> A community onset of the outbreak was seen in Argentina during 2010 – 2011, which could be associated with the trauma caused by some natural disasters.<sup>[15]</sup>

In developing countries, diabetes mellitus (DM) is the most predominant risk factor of mucormycosis, whereas, in developed countries with a high-income level, transplantation and hematological malignancy are the leading factors predisposing individuals to mucormycosis.<sup>[2]</sup> Nonetheless, with advancements and changes in the therapeutic approaches of diseases like cancer, the epidemiology of mucormycosis is also evolving due to the new immunomodulating agents.<sup>[16]</sup> Figure 1 presents some of the common myths and the respective counter-facts regarding the growth, prevention, and treatment of mucormycosis.

## TYPES OF MUCORMYCOSIS

Generally, the infection is anatomically classified into 5 different clinical forms including, rhinocerebral (30%–50%), cutaneous, pulmonary, gastrointestinal, and disseminated mucormycosis.<sup>[2,17]</sup>

Depending on the underlying conditions and the risk factors, mucormycosis shows a specific predilection to particular anatomic sites. For example, rhino-orbito-cerebral mucormycosis (ROCM) is a typical presentation in diabetic and patients diabetes ketoacidosis (DKA) (70%). This clinical form starts in the sinus and might involve the orbit and the brain eventually. Interestingly, in both COVID-19 and non-COVID-19 individuals, the infection is most predominantly presented as ROCM, while other forms of mucormycosis constitute the low percentages of the clinical form in COVID-19 patients (<10%).<sup>[7]</sup> Cutaneous and soft-tissue mucormycosis is the most common type of infection in people who are not immunocompromised and have with traumatic injury.<sup>[18]</sup> Patients with profound neutropenia and graft-versus-host disease, those suffering from hematological malignancy, solid organ transplant, and bone marrow recipients develop usually pulmonary mucormycosis; gastrointestinal mucormycosis is usually caused in neonates (premature infants with very less body weight) with very low immunity due to medications, malnutrition, antibiotics, or surgery. Disseminated form of mucormycosis is caused when the infection travels through the bloodstream and affects other parts of the body, like

the brain, spleen, skin, or heart which presented more frequently in patients receiving deferoxamine therapy.

## THE ETIOLOGICAL AGENTS OF MUCORMYCOSIS AND COVID-19-ASSOCIATED MUCORMYCOSIS

*Rhizopus*, *Mucor*, *Lichtheimia*, *Apophysomyces*, *Saksenaia*, *Cunninghamella*, *Rhizomucor*, and *Syncephalastrum* are some types of *Mucorales* fungi causing mucormycosis.<sup>[2]</sup> *Rhizopus* species and the *Mucor* species are the most etiologic agents. Results of the literature review regarding CAM cases indicate that in only 51% and 22.5% of cases, identification to genus and species level was described, respectively.<sup>[7]</sup> However, *Rhizopus* species were the most prevailing species identified. *Rhizopus arrhizus* was more frequently in ROCM cases while *Rhizopus microsporus* was mostly in cases with lung involvement.<sup>[7]</sup>

## SPREAD OF MUCORMYCOSIS IN COVID-19-AFFECTED PATIENTS

COVID-19 exacerbates the tendency of mucormycosis in the patients because, regardless of the management recommended for treatment of COVID-19, e.g., corticosteroids therapy and remdesivir, which exacerbate glucose homeostasis in both diabetic and nondiabetic patients, the infection on its own causes a diabetogenic state (as there is evidence suggesting that the virus induces damage of pancreatic islets which resulting in acute diabetes and DKA) and hyper-ferritinemic syndrome increasing both intracellular and free iron levels in patients with COVID-19 pneumonia that results in elevated iron uptake by *Mucorales* species and consequently stimulates rapid fungal growth.<sup>[1,7,19,20]</sup> This problem is further augmented in patients with severe COVID-19 and ketoacidosis, since the increased free iron is released from the binding proteins in the background of acidosis.<sup>[1]</sup> Excess free iron levels are also observed in patients with renal failure due to deferoxamine chelation which make them predisposed to develop mucormycosis.<sup>[21]</sup> The impairment of neutrophil migration to the infected tissue, ingestion and phagolysosome fusion caused as a result of corticosteroids taken during the treatment of COVID-19 also increases the chances of getting mucormycosis.<sup>[1]</sup> Moreover, a permissive environment for the growth of *Mucorales* is provided by the dysbiosis caused by excessive use of antibiotics along with damage of the epithelium.<sup>[20]</sup> Other factors that are supposed to be associated with the development of CAM in COVID-19 patients include cytokine storm, subsequent immune dysregulation, and endothelialitis.<sup>[19]</sup> Widespread endothelial injury, as observed in COVID-19 patients with severe form of disease might increase adhesion and penetration of *Mucorales* to the endothelium. Adhesion and penetration to the endothelium are critical initial steps in the pathogenesis of mucormycosis.<sup>[19]</sup>

By April 2021, while India was facing the second wave of the COVID-19 pandemic, a sudden rise in the number of mucormycosis cases, an otherwise rare disease, in the patients suffering or just recovered from the COVID attracted great attention and made a public menace. As discussed earlier, considering the COVID-19-associated medication and pathogenesis leading to suppressing immune system and factors aggravating the blood glucose control, CAM is most predominantly observed in cases with diabetes background, particularly those having a history of intravenously administered glucocorticoid agents.<sup>[5,6,19]</sup> Mucormycosis has been proven fatal if not promptly diagnosed or left unattended, as it may even invade the brain.<sup>[1,2,6]</sup> The Ministry of Health and Family Welfare and the Indian Council of Medical Research (ICMR) issued specific guidelines for the general public to handle the situation in an optimal and informed way.<sup>[22]</sup> On account of the spread of CAM, various states of India have declared the disease as a notifiable disease/epidemic.

The number of cases of mucormycosis has risen from around 100 cases annually across India (worst-case scenario) to around 100 cases in 20 days from a single hospital in New Delhi.<sup>[23]</sup> Figure 2 is a graphical representation of the distribution of the number of mucormycosis cases across India till June 10. On May 20, 2021, the Health Ministry of India asked all the states and union territories of the country to declare mucormycosis as an epidemic under the Epidemic Diseases Act of 1987.<sup>[24]</sup>

This letter was issued after the spike in the number of CAM cases was evidenced throughout the country. Before this, the state of Rajasthan had already declared this an epidemic, and the state government of Haryana formed The Haryana Epidemic Diseases (Mucormycosis) Regulations, 2021 to control the outbreak of this fungal infection. CAM reports were also elicited from other developing countries. A previous meta-analysis described the characteristics of 80 CAM cases dominantly presented as ROCM across

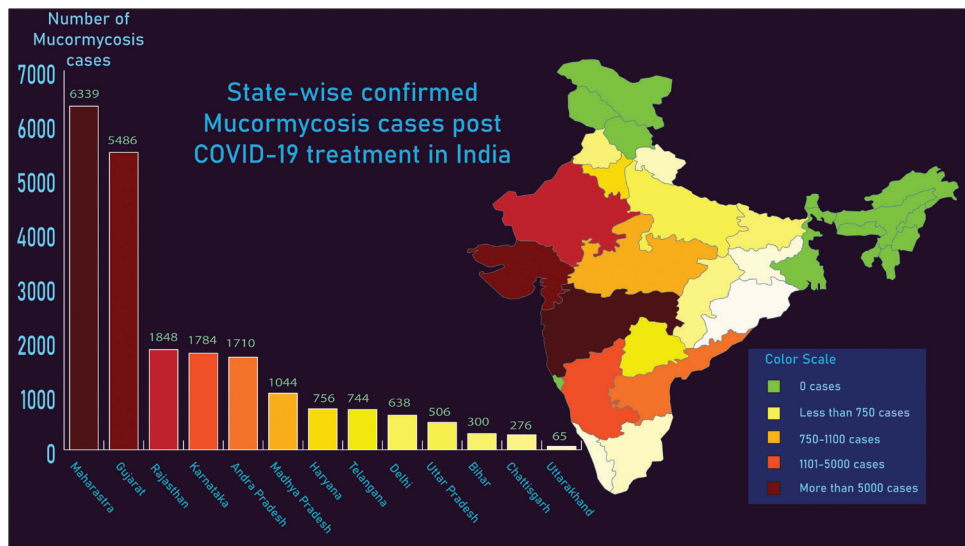


Figure 2: Distribution of number of COVID-19-associated mucormycosis cases reported from different states in India as of June 10, 2021<sup>[5]</sup>

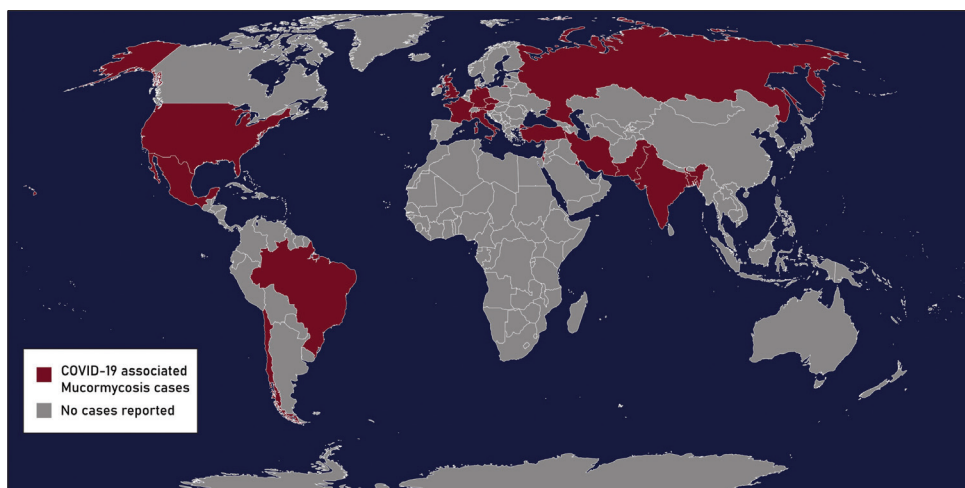


Figure 3: The countries having reported cases of mucormycosis in COVID-19 affected patients<sup>[7]</sup>

18 countries globally.<sup>[7]</sup> Figure 3 shows the countries that have reported mucormycosis cases in COVID-19 affected patients.<sup>[7]</sup> Obviously, the number of countries reporting CAM cases is daily increasing.

### WHO ALL ARE AT RISK?

The classical risk factors predisposing patients to mucormycosis are uncontrolled DM, neutropenia, hematological malignancies, organ transplantation, trauma and burn, and use of immunosuppressants such as corticosteroids.<sup>[1,2]</sup>

The people who recently recovered or are still infected with COVID-19 is the current vulnerable population most recently added to the risk list of acquiring mucormycosis, especially when the following conditions are present [Figure 4]: Hyperglycemia occurs in undiagnosed or uncontrolled diabetics but may also be induced by corticosteroids. Previous investigations concerning CAM, particularly those reported from India and Iran, are clearly shown that CAM cases are predominantly seen in patients with DM (94%), especially in those with poorly controlled DM (67%) and severe or critical COVID-19 (95%).<sup>[6,19]</sup> More so, in 75%–88% of CAM cases, history of systemic corticosteroids therapy was documented as the second common factor after diabetes outlining the high vulnerability of these groups of COVID-19 patients to CAM development.<sup>[1,6,7,19,20]</sup> Treatment with corticosteroids (e.g., IV dexamethasone), although recommended to be administered in COVID-19 patients, appears to be a double-edged sword potentially increasing the risk of developing invasive mold infections, particularly in patients with known DM.<sup>[1,4]</sup> Patients with diabetes and hyperglycemia often display an inflammatory state that elicits constant recruitment and local activation of immune cells, including macrophages and neutrophils that secrete

further proinflammatory cytokines and generate persistent inflammation.<sup>[7]</sup> In patients with SARS-CoV-2, the activation of antiviral immunity may paradoxically potentiate this inflammatory phenotype and thus may favor secondary infections.<sup>[7]</sup>

Furthermore, many COVID-19 subjects may have comorbidities (some disease along with COVID-19) and have been taking immunosuppressants/steroids/antibiotics and even antifungals as medication for a long time, favoring mucormycosis and other fungal infections.<sup>[1,4,7]</sup>

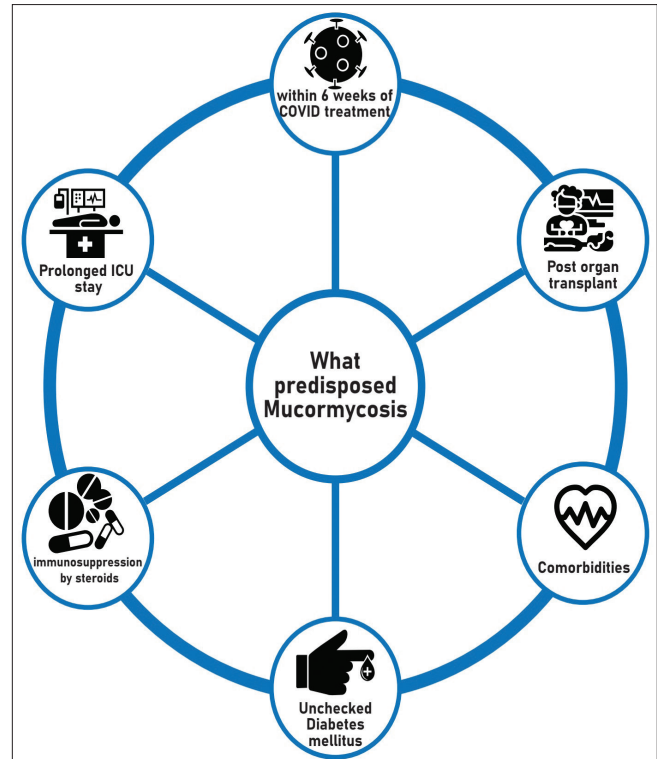


Figure 4: Factors predisposing hosts to mucormycosis

Table 1: Preventive measures minimizing exposure of COVID-19 patients to potential sources of mucormycosis

| The potential risk   | The appropriate preventive action  |
|--|--|
| Possible colonization of water used as humidifier in supplementary oxygen set  | Strict aseptic precautions are recommended while administering supplementary oxygen. Make sure that sterilized distilled water is used in humidifiers, daily change of the sterilized humidifier and the tubes is also recommended, if and when oxygen therapy is done for the treatment of COVID-19   |
| Poorly controlled diabetes, unrestrained increase of blood sugar   | Blood sugar levels should be continuously monitored in order to maintain them in the normal range  |
| Low personal and environmental hygiene lead to molds colonization, e.g., poor mouth hygiene, particularly during hospitalization, being in dusty places, unprotected agriculture | Personal and environmental hygiene should be considered<br>Covering face mask while going to dusty places like construction sites<br>Taking care of one's personal hygiene through daily baths and keeping the surroundings clean. One must make sure that he/she takes a thorough scrub bath every time after coming home from any public place<br>Avoiding of getting involved in any gardening activity, but if it is necessary, do not make direct skin contact with the soil, manure, etc.<br>Regularly washing nasal passage with normal saline or gargling betadine in high risk individuals may be effective in eradicating the inhaled Mucorales spores |
| Treatment with high doses of corticosteroids   | Medicines like steroids should be judiciously taken in high-risk patients, with proper dosage and schedule in compliance with the current preferred practice guidelines  |
| Extremely high risk individuals with COVID-19  | For those undergoing chemotherapy or organ transplant, some antifungal medications in order to prevent mucormycosis may be prescribe   |

**Table 2: The symptoms prompting high index of suspicion for mucormycosis in high-risk individuals**

| Form of mucormycosis          | Clinical clues   |
|-------------------------------|--|
| ROCM                          | Sinusitis (pansinusitis or maxillary and ethmoid involvement): Bloody or blackish secretions from the nasal area, along with congestion and pain in the cheekbone<br>Pain on one side of the face, inflammation, lack of sensation or unilateral facial swelling<br>Blackish discoloration on the bridge of the nose/palate, epistaxis<br>Aching teeth, degrading of tooth structures, or jaw involvement<br>Affected eyesight, i.e., double or hazy vision with pain, eyelid inflammation, ptosis, and proptosis<br>Necrosis and skin face necrotic lesion<br>Fever (50%), headache |
| Pulmonary mucormycosis        | Worsening of respiratory functions, and shortness of breath<br>Chest pain and excess build-up of fluid in the lungs<br>Fever (frequently manifested)<br>Coughing out blood   |
| Cutaneous mucormycosis        | Infected area on the skin may turn black, and may look like blisters, particularly in patients with disrupted cutaneous barriers, as a result of either traumatic implantation of soil, maceration of skin by a moist surface, burns, or even through direct access via intravenous catheters or subcutaneous injections<br>Pain, inflammation, redness and progressive necrotizing skin lesion around the affected area on the skin   |
| Gastrointestinal mucormycosis | Pain in the abdominal region (predominantly in the stomach, colon, and ileum) along with puking, nausea and vomiting<br>Gastrointestinal bleeding  |
| Disseminated mucormycosis     | If brain is the affected area, the patient might show changes in the mental state and even result in a coma<br>Evidence of infarction in multiple organs   |

ROCM=Rhino-orbito-cerebral mucormycosis

Given the usage of immunosuppressive agents, e.g., anti-interleukin 6 receptor antibody, the COVID-19 patients may become immunocompromised. Further, small fraction of the COVID-19 patients may simultaneously suffer from diseases impairing immune system like HIV, cancer, or because of organ transplant which put them at manifold risk for fungal infections.<sup>[1,7]</sup>

However, fortunately, mucormycosis is not contagious, and neither does it spread from person to person nor animal to person.<sup>[1,7]</sup>

## PRECAUTIONS

The spores of Mucorales species enter the body through the nose while breathing, and in individuals with suppressed or deficient immune system grow and invade.<sup>[1,7]</sup> Considering the fact that the fungi often get eradicated by the polymorphonuclear phagocytes in healthy people, COVID-19 patients with healthy immune system, e.g., those who did not have diabetes, did not take high doses of corticosteroids, or those experienced the mild form of the disease, are less needed to be concerned about CAM occurrence. However, public knowledge about the warning symptoms and preventive measures of CAM is issue of great importance because the infection has been shown to be near to be happened in those with higher risks.

It is noteworthy that the availability of spores is most likely in humid places with some decaying organic substances. To avoid mucormycosis, the precaution measures summarized in Table 1 are suggested to be taken, especially by the COVID-19 patients who have diabetes, history of

systemic corticosteroid therapy or those who have both last conditions.<sup>[22,25]</sup>

The aforementioned approaches can effectively minimize the patient exposure to potential sources of infection.

## SYMPTOMS

As per the guidelines issued by the ICMR,<sup>[22]</sup> the symptoms leading to rule in the diagnosis of different clinical forms of CAM in COVID-19 patients with diabetes or in those with suppressed immunity are summarized in Table 2.

The CAM-associated symptoms generally start in high-risk patients 8 – 10 days after testing positive for COVID-19, but might even occur after 2 months in some cases.<sup>[1,6]</sup> The patients should be the most vigilant for any signs and symptoms during the 2–6-week period after testing positive.<sup>[1,6,20]</sup>

## DIAGNOSIS AND ITS ASSOCIATED CHALLENGES

Given the acuteness, aggressiveness, high mortality and morbidity rate of CAM, an early diagnosis approach and timely initiation of antifungal therapy along with urgent surgical intervention is required upon suspicion of CAM.<sup>[1,2]</sup> Early diagnosis and management of CAM can prevent from eye exenteration, cerebral involvement and minimize the rate of mortality.<sup>[1,6]</sup> A complex of the patient's medical history, related risk factors, assessment of clinical presentations, and pulmonary or cranial CT scan or MRI (based on anatomical involvement), should be sequentially evaluated in cases with high suspicion.<sup>[2,6]</sup> If mucormycosis or aspergillosis

is a potential diagnosis, biopsy or fluid specimens collection from affected area is strongly recommended and pathological and mycological observations to confirm the presence of the septate (suggestive of aspergillosis) or aseptate hyphae (suggestive of mucormycosis) or even both simultaneously in cases with co-infection is required.<sup>[2,26]</sup> More so, differential diagnosis of mucormycosis from other deep mycoses and pathologies with similar clinical manifestations should be precisely considered. Based on anatomical involvement, the tests might involve analyzing a sample of fluid taken from the respiratory system, a tissue biopsy, and a CT scan of the parts of the body suspected to be infected.<sup>[1,2,6]</sup> The clinical specimens should be sent in parallel for pathological and mycological investigation to be screened for the presence of wide nonseptate or pauciseptate hyphae (at least 6-16  $\mu\text{m}$ ) in tissue usually appearing as ribbon-like with an irregular pattern of branching.<sup>[2]</sup> Direct mycological examination of tissue biopsy using 10%–15% potassium hydroxide or stained with fluorescent brighteners calcofluor white has lower turnaround time to establish the diagnosis than those tissue sections stained with hematoxylin and eosin, periodic acid Schiff stain, or Grocott Gomori's methenamine silver stain used for histopathological examination.<sup>[2]</sup> However, to verify an infection, tissue and vascular invasion of non-pigmented aseptate hyphae must be shown in pathological examination. The pathological and mycological investigations for evaluation of Mucorales hyphae and differentiate from those observed in other mold infections like aspergillosis is challenging and needs personal expertise.<sup>[2]</sup> *Aspergillus* hyphae are 3–5  $\mu\text{m}$  wide, regularly septated, and dichotomously branched (45° branching angle).<sup>[2,26]</sup> Despite capability of culture-based methods in discrimination between *Aspergillus* and Mucorales species and initial identification of causal agent, however, the positivity rate of the method in diagnosis of mucormycosis is scarcely exceeds 50%.<sup>[2]</sup>

The reverse halo sign predominantly presented in peripheral locations of the lung may be suggestive of pulmonary mucormycosis in immunodeficient patients and is useful for the initiation of preemptive antifungal therapy;<sup>[27]</sup> however, in COVID-19 patients, the pattern is less specific as it has also been described as one of the potential radiological features of COVID-19.<sup>[7]</sup> Furthermore, due to the fear of risk pertaining to airborne transmission of SARS-CoV-2 during aerosol-generating procedures, collecting bronchoalveolar lavage specimens for potential diagnosis of pulmonary mucormycosis has been scaled down which exacerbated the condition required for timely diagnosis of mucormycosis and probably pulmonary mucormycosis is under-diagnosed or under-reported.<sup>[1,7]</sup>

Unlike aspergillosis, no standardized serologic test for mucormycosis has been developed yet; however,

PCR-based techniques using Mucorales specific primers on either fresh or formalin-fixed paraffin-embedded tissue have been shown to be highly sensitive and specific.<sup>[2,28]</sup>

Considering the difference in antifungal susceptibility patterns of species under *Mucorales* order, precise identification of the etiology to the species level through molecular based methods is recommended for species-specific antifungal treatment.<sup>[2]</sup> As in infections caused by *Cunninghamella bertholletiae*, the highest rate of clinical failures was observed which is in line with the high amphotericin B MICs reported for this *Zygomycete*.<sup>[2]</sup>

The fact that is less considered is the dependence of all aforementioned diagnostic methods on biological specimens, e.g., bronchoalveolar lavage and biopsy collected by invasive procedures from clinically affected tissues, which make their application for detection of mucormycosis to be limited wherever the condition cannot be provided particularly in hematological setting with great number of patients with thrombocytopenia and which may result in delayed diagnosis and unintended consequences.<sup>[1,7]</sup> Nonetheless, the capacity of molecular methods for detection of *Mucorales* DNA from noninvasive specimens like serum specimen has appeared a bright horizon for prompt detection of mucormycosis and should be assessed as a new pivotal strategy for CAM diagnosis.<sup>[29]</sup>

## TREATMENT

The treatment of CAM should not be delayed under any condition as the sequela may be irreparable. Reduction of immunosuppressive therapy is desirable and surgical debridement of involved tissue is a priority whenever is possible.<sup>[2]</sup> The initial course of treatment is giving antifungal medicines either orally or intravenously, depending on how invasive the fungal attack is. Amphotericin B and isavuconazole are the two main antifungal agents currently recommended for the initial therapy of mucormycosis.<sup>[1,2]</sup> Posaconazole is an appropriate drug for salvage therapy in patients who are unable to tolerate amphotericin B. Liposomal amphotericin-B is the most effective medicine for mucormycosis.<sup>[2]</sup> The aim of this medication is to reduce the pace of fungal growth and to stop its activity. The standard recommended doses of liposomal amphotericin-B are 5 – 10 mg/kg intravenously per day. If a patient is not tolerant to amphotericin-B, a reduced dosage can be administered; however, it should be at least 5 mg/kg/day.<sup>[2]</sup> In patients with kidney failure, posaconazole or isavuconazole can be given. These medicines can also be given along with liposomal amphotericin-B if the infection is causing serious damage or if it is progressing

rapidly throughout the body. In the case of posaconazole, a step-down therapy can be considered once disease is controlled and the susceptibility confirmed.<sup>[2]</sup> Susceptibility testing to guide therapy may be important because of *in vitro* resistance demonstrated for some species (*Rhizomucor* sp. and *Rhizopus* sp.).<sup>[30,31]</sup> As said before, surgical debridement can also be performed to remove the necrotic tissues and should be considered along with the antifungal medicines as early as possible.<sup>[2]</sup>

Generally, the therapy should be continued until resolution of clinical signs and symptoms, resolution or stabilization of radiographic findings, and resolution of underlying immunosuppression. However, this treatment is usually needed for 6 weeks but can go up to 6 months with monitoring kidney function.<sup>[2]</sup>

## CONCLUSION

Mucormycosis is an extremely dangerous disease due to its high morbidity and mortality rate. Till now, it was a rare disease. There is not even a standardized test to detect the presence of this infection, and an experienced pathologist is required to differentiate this from other filamentous fungi present in the tissue. Surgical debridement and intravenously treatment with liposomal amphotericin-B are crucial for patient survival. Improvements in sanitary conditions are important and in the current times of COVID-19 pandemic, the optimization of metabolic complications of an uncontrolled DM or hyperglycemia associated with corticosteroids is mandatory. In this paper, we have provided comprehensive information available on mucormycosis that would be relevant to COVID-19 patients. However, other fungal infections, e.g., COVID-19-associated aspergillosis and candidiasis, have been reported in COVID-19 patients. Everyone must be aware of the symptoms to look out for and contact a doctor immediately for the differential diagnosis and timely management of the infection. It can get worse if proper care is not taken and prove to be fatal.

### Ethics approval statement

Neither human nor animal participants were involved in this review study. Therefore, taking an ethics approval was not required.

### Data availability statement

All data relevant to the study are included in the article.

### Financial support and sponsorship

Nil.

### Conflicts of interest

There are no conflicts of interest.

## REFERENCES

- Ahmadikia K, Hashemi SJ, Khodavaisy S, Getso MI, Alijani N, Badali H, *et al.* The double-edged sword of systemic corticosteroid therapy in viral pneumonia: A case report and comparative review of influenza-associated mucormycosis versus COVID-19 associated mucormycosis. *Mycoses* 2021;64:798-808.
- Cornely OA, Alastruey-Izquierdo A, Arenz D, Chen SC, Dannaoui E, Hochhegger B, *et al.* Global guideline for the diagnosis and management of mucormycosis: An initiative of the European Confederation of Medical Mycology in cooperation with the Mycoses Study Group Education and Research Consortium. *Lancet Infect Dis* 2019;19:e405-21.
- Rahman FI, Islam MR, Bhuiyan MA. Mucormycosis or black fungus infection is a new scare in South Asian countries during the COVID-19 pandemic: Associated risk factors and preventive measures. *J Med Virol* 2021;93:6447-8.
- Salehi M, Ahmadikia K, Badali H, Khodavaisy S. Opportunistic fungal infections in the epidemic area of COVID-19: A clinical and diagnostic perspective from Iran. *Mycopathologia* 2020;185:607-11.
- Mahalaxmi I, Jayaramayya K, Venkatesan D, Subramaniam MD, Renu K, Vijayakumar P, *et al.* Mucormycosis: An opportunistic pathogen during COVID-19. *Environ Res* 2021;201:111643.
- Pakdel F, Ahmadikia K, Salehi M, Tabari A, Jafari R, Mehrparvar G, *et al.* Mucormycosis in patients with COVID-19: A cross-sectional descriptive multicentre study from Iran. *Mycoses* 2021;64:1238-52.
- Hoeningl M, Seidel D, Carvalho A, Rudramurthy SM, Arastehfar A, Gangneux JP, *et al.* The emergence of COVID-19 associated mucormycosis: a review of cases from 18 countries. *Lancet Microbe* 2022;[In Press].
- Richardson M. The ecology of the Zygomycetes and its impact on environmental exposure. *Clin Microbiol Infect* 2009;15 Suppl 5:2-9.
- Sahoo JP, Mishra AP, Pradhan P, Samal KC. Misfortune never comes alone – The new “Black Fungus” accompanying COVID-19 wave. *Biot Res Today* 2021;3:318-20.
- Garg D, Muthu V, Sehgal IS, Ramachandran R, Kaur H, Bhalla A, *et al.* Coronavirus Disease (COVID-19) Associated Mucormycosis (CAM): Case report and systematic review of literature. *Mycopathologia* 2021;186:289-98.
- Avatef Fazeli M, Rezaei L, Javadirad E, Iranfar K, Khosravi A, Amini Saman J, *et al.* Increased incidence of rhino-orbital mucormycosis in an educational therapeutic hospital during the COVID-19 pandemic in western Iran: An observational study. *Mycoses* 2021;64:1366-77.
- Neblett Fanfair R, Benedict K, Bos J, Bennett SD, Lo YC, Adebajo T, *et al.* Necrotizing cutaneous mucormycosis after a tornado in Joplin, Missouri, in 2011. *N Engl J Med* 2012;367:2214-25.
- Garner D, Machin K. Investigation and management of an outbreak of mucormycosis in a paediatric oncology unit. *J Hosp Infect* 2008;70:53-9.
- LeMaile-Williams M, Burwell LA, Salisbury D, Noble-Wang J, Arduino M, Lott T, *et al.* Outbreak of cutaneous *Rhizopus arrhizus* infection associated with karaya ostomy bags. *Clin Infect Dis* 2006;43:e83-8.
- Chaves MS, Franco D, Nanni JC, Basaldúa ML, Boleas M, Aphalo G, *et al.* Control of an outbreak of postoperative bone mucormycosis: An intervention study of contiguous cohorts. *Am J Infect Control* 2016;44:1715-7.
- Song G, Liang G, Liu W. Fungal co-infections associated with global COVID-19 pandemic: A clinical and diagnostic perspective from China. *Mycopathologia* 2020;185:599-606.
- Roden MM, Zaoutis TE, Buchanan WL, Knudsen TA, Sarkisova TA, Schaufele RL, *et al.* Epidemiology and outcome of zygomycosis: A review of 929 reported cases. *Clin Infect Dis* 2005;41:634-53.



18. Kachuei R, Badali H, Vaezi A, Jafari NJ, Ahmadikia K, Kord M, *et al.* Fatal necrotising cutaneous mucormycosis due to novel *Saksena* species: A case study. *J Wound Care* 2021;30:465-8.
19. John TM, Jacob CN, Kontoyiannis DP. When uncontrolled diabetes mellitus and severe COVID-19 converge: The perfect storm for mucormycosis. *J Fungi (Basel)* 2021;7:298.
20. Pal R, Singh B, Bhadada SK, Banerjee M, Bhogal RS, Hage N, *et al.* COVID-19-associated mucormycosis: An updated systematic review of literature. *Mycoses* 2021;64:1452-9.
21. Reid G, Lynch III JP, Fishbein MC, Clark NM. Mucormycosis. *Semin Respir Crit Care Med* 2020;41:099-114.
22. ICMR. Evidence Based Advisory in the Time of COVID-19 (Screening, Diagnosis & Management of Mucormycosis). ICMR; Available from: [https://www.icmr.gov.in/pdf/covid/techdoc/Mucormycosis\\_ADVISORY\\_FROM\\_ICMR\\_In\\_COVID19\\_timepdf](https://www.icmr.gov.in/pdf/covid/techdoc/Mucormycosis_ADVISORY_FROM_ICMR_In_COVID19_timepdf). [Last accessed on 2021 Jun 05].
23. Sharma D. AIIMS Neurologist Says Black Fungus Cases cross 3-Digit Mark, Asks Diabetic Patients to Control Sugar. Available from: <https://www.hindustantimes.com/india-news/aiims-doctor-says-black-fungus-cases-cross-3-digit-mark-asks-diabetic-patients-to-control-sugar-101621426958616html>. [Last accessed on 2021 Jun 10].
24. Health Ministry asks States to Declare Black Fungus an Epidemic. Available from: <https://timesofindia.indiatimes.com/india/health-ministry-asks-states-to-declare-black-fungus-an-epidemic/articleshow/82795557.cms>. [Last accessed on 2021 May 31].
25. Honavar SG. Code mucor: Guidelines for the diagnosis, staging and management of rhino-orbito-cerebral mucormycosis in the setting of COVID-19. *Indian J Ophthalmol* 2021;69:1361-5.
26. Ardi P, Daie-Ghazvini R, Hashemi SJ, Salehi MR, Bakhshi H, Rafat Z, *et al.* Study on invasive aspergillosis using galactomannan enzyme immunoassay and determining antifungal drug susceptibility among hospitalized patients with hematologic malignancies or candidates for organ transplantation. *Microb Pathog* 2020;147:104382.
27. Georgiadou SP, Sipsas NV, Marom EM, Kontoyiannis DP. The diagnostic value of halo and reversed halo signs for invasive mold infections in compromised hosts. *Clin Infect Dis* 2011;52:1144-55.
28. Raiesi O, Hashemi SJ, Mohammadi Ardehali M, Ahmadikia K, Getso MI, Pakdel F, *et al.* Molecular identification and clinical features of fungal rhinosinusitis: A 3-year experience with 108 patients. *Microb Pathog* 2021;158:105018.
29. Millon L, Scherer E, Rocchi S, Bellanger AP. Molecular strategies to diagnose mucormycosis. *J Fungi (Basel)* 2019;5:24.
30. Dannaoui E. Antifungal resistance in mucorales. *Int J Antimicrob Agents* 2017;50:617-21.
31. Dannaoui E, Meletiadis J, Mouton JW, Meis JF, Verweij PE, Eurofung Network. *In vitro* susceptibilities of zygomycetes to conventional and new antifungals. *J Antimicrob Chemother* 2003;51:45-52.