

Comparison of susceptibility weighted imaging with conventional MRI sequences in multiple sclerosis plaque assessment: A cross-sectional study

Masoud Rabbani, Vahid Shaygannejad¹, Mahshid Bahrami, Sajad Badiei²

Department of Radiology, School of Medicine, Isfahan University of Medical Sciences, Isfahan, Iran, ¹Department of Neurology, Isfahan Neurosciences Research Centre, School of Medicine, Isfahan University of Medical Sciences, Isfahan, Iran, ²Students Research Committee, Isfahan University of Medical Sciences, Isfahan, Iran

Background: The current study was performed to compare susceptibility-weighted imaging (SWI) with magnetic resonance imaging (MRI) methods of T2-weighted (T2W) and fluid-attenuated inversion recovery (FLAIR) imaging in multiple sclerosis (MS) plaque assessment. **Materials and Methods:** This cross-sectional study was conducted among 50 MS patients referred to Shafa Imaging Center, Isfahan, Iran. Patients who fulfilled McDonald criteria and were diagnosed with MS by a professional neurologist at least 1 year before the study initiation were included in the study. Eligible patients underwent brain scans using SWI, T2W imaging, and FLAIR. Plaques' number and volume were detected separately for each imaging sequence. Moreover, identified lesions in SWI sequence were evaluated in terms of iron deposition and central veins. **Results:** Totally 50 patients (10 males and 40 females) with a mean age of 28.48 ± 5.25 years were included in the current study. Majority of patients (60%) had a disease duration of >5 years, and mean expanded disability status score was 2.56 ± 1.32 . There was no significant difference between different imaging modalities in terms of plaques' number and volume ($P > 0.05$). It was also found that there was a high correlation between SWI and conventional imaging techniques of T2W ($r = 0.97, 0.91, P < 0.001$) and FLAIR ($r = 0.99, 0.99, P < 0.001$) in the estimation of both the number and volume of plaques ($P < 0.001$). **Conclusion:** The results of the present study indicated that SWI and conventional MRI sequences have similar efficiency for plaque assessment in MS patients.

Key words: Magnetic resonance imaging, multiple sclerosis, susceptibility-weighted imaging

How to cite this article: Rabbani M, Shaygannejad V, Bahrami M, Badiei S. Comparison of susceptibility weighted imaging with conventional MRI sequences in multiple sclerosis plaque assessment: A cross-sectional study. *J Res Med Sci* 2021;26:128.

INTRODUCTION

Multiple sclerosis (MS) is a chronic inflammatory demyelinating disease of the central nervous system (CNS) which causes major permanent neurologic damages.^[1,2] MS is one of the most prevalent neurological diseases with more than two million patients are affected worldwide.^[3] Recent studies have shown a significant increase in the incidence and prevalence of MS in Central Iran.^[4] The cause of MS has not fully understood; however, it has been implicated that genetic and environmental factors are associated with

its etiology.^[5] The presence of large focal demyelinated plaques in the white and gray matters of the CNS is the pathological hallmark of the disease.^[6] The severity of the disease can be revealed by examining the number and volume of plaques in the brain by magnetic resonance imaging (MRI).^[7]

Conventional MRI plays an important role in the assessment of MS because of its sensitivity in the detection of the disease-related abnormalities and their changes over time.^[8] It has also been considered as a useful tool for the detection of atypical and

Access this article online	
Quick Response Code: 	Website: www.jmsjournal.net
	DOI: 10.4103/jrms.JRMS_726_17

This is an open access journal, and articles are distributed under the terms of the Creative Commons Attribution-NonCommercial-ShareAlike 4.0 License, which allows others to remix, tweak, and build upon the work non-commercially, as long as appropriate credit is given and the new creations are licensed under the identical terms.

For reprints contact: WKHLRPMedknow_reprints@wolterskluwer.com

Address for correspondence: Dr. Mahshid Bahrami, Department of Radiology, School of Medicine, Kashani Teaching Hospital, Isfahan University of Medical Sciences, Isfahan Iran.
E-mail: maedebahrami@rocketmail.com

Received: 01-Sep-2017; **Revised:** 29-Nov-2017; **Accepted:** 09-Nov-2018; **Published:** 22-Dec-2021

clinically silent MS. Brain MRI in patients with clinically isolated syndrome can help to predict the risk of MS development in the future.^[9,10] The MRI protocols which are used commonly for the evaluation of MS include T₂-weighted (T2W), fluid-attenuated inversion recovery (FLAIR), and T1-weighted sequence with or without contrast agent (usually gadolinium based) administration. However, it is not possible to use contrast-enhanced MRI imaging option in some cases such as patients with renal insufficiency or allergic reactions.^[11]

Susceptibility-weighted imaging (SWI) is a new neuroimaging option which generates highly contrasted images based on tissue magnetic susceptibility differences.^[1] Recently, some studies have investigated iron deposition and changes in the vascular structure of MS lesions to explore the pathology of the disease.^[12-14] It has been reported that SWI compared to conventional imaging methods shows different characteristics of lesions.^[15] Nonetheless, the role of SWI in MS plaque assessment in comparison with conventional MRI methods has not been focused enough. The current study aimed to compare SWI with MRI methods of T2WI and FLAIR in MS plaque assessment.

MATERIALS AND METHODS

Patients and setting

This cross-sectional study was conducted on MS patients who referred to Shafa Imaging Center, Isfahan, Iran, between 2015 and 2016. The study protocol was approved by the Ethical Committee of the Isfahan University of Medical Sciences (Project No. 395877). After a complete description of the study objectives, written consent was obtained from all patients. All patients who fulfilled McDonald criteria and had been diagnosed with MS by an experienced neurologist for at least 1 year before study initiation were included in the study. Patients who had the contraindication to MRI or did not consent to continue the research were excluded from the study.

Study measurements

At first, demographic information including age, sex, and age of disease onset have been recorded. Each patient was examined by an experienced neurologist who recorded clinical data and Expanded Disability Status Score (EDSS). Brain MRI was obtained with Siemens Magnetom Avanto 1.5T MRI system. Imaging parameters for conventional sequences were according to Table 1 similar to previous research.^[14] SWI sequence was obtained for each patient according to following parameters: slab of 64 slices

with 2 mm thickness, no gap, field of view of 256 mm, acquisition matrix of 512*256, repetition time/echo time of 85/83 ms, and the flip angle of 25°. Each sequence was interpreted by an experienced radiologist who documented the number and location of plaques. Central vein condition (according to yes or no) and blooming artifact caused by iron deposition (according to their number) have been reported too. Plaques' volume was estimated by TOADS-CRUISE software (TCG, Inc. of Washington, D.C., USA. <http://www.nitrc.org/projects/toads-cruise>).^[16]

Statistical analysis

Continuous and categorical data were presented as mean \pm standard deviation and frequency (percentage). Continuous normally distributed data were compared between groups using independent *t*-test and analysis of variance. Categorical data were compared between groups using Chi-square or Fisher's exact test. Pearson correlation was used for evaluating the association of volume and number of SWI, T2W, and FLAIR indices in three imaging methods. All statistical analyses were performed using SPSS software (version 16; SPSS Inc., Chicago IL, USA).

RESULTS

Totally 50 patients (10 males and 40 females) with a mean age of 28.48 ± 5.25 years were included in the current study. Majority of patients had a disease duration of >5 years (60%), and the mean EDSS score was 2.56 ± 1.32 [Table 2]. Patients with a disease duration of >5 years had a higher mean of plaques' number and volume compared to patients with a disease duration between 1 and 5 years ($P < 0.001$) according to SWI and conventional imaging methods. Furthermore, we found the mean EDSS score to be 3.08 in those with disease duration >5 years compared to a mean EDSS score of 1.77 in those with a disease duration of 1–5 years ($P < 0.001$). As shown in Figures 1 and 2, there was no significant difference between different imaging modalities in terms of plaques' number and volume totally and according to the disease duration (>5 and <5 years) ($P > 0.05$). It was also found that there was a positive significant correlation between SWI with T2W ($r = 0.97, 0.91, P < 0.001$) and FLAIR ($r = 0.99, 0.99, P < 0.001$) conventional imaging techniques in the estimation of both the number and volume of plaques [Table 3].

DISCUSSION

In the current study, we compared SWI with two conventional MRI methods in terms of plaque assessment

Table 1: Imaging parameters for T2-weighted and fluid-attenuated inversion recovery sequences at 1.5T

	Number of slices	Slice thickness (mm)	FOV (mm)	TR (ms)	TE (ms)	BW (Hz/pixel)	FA	Resolved (mm)
T2	45	3	256	2800	16	100	180°	1×1×3
FLAIR	45	3	240	8800	125	130	180°	1×1×3

FLAIR=Fluid attenuated inversion recovery; FOV=Field of view; TE=Time of Echo, TR=Time of Repetition; FA=Flip angle; BW=Bandwidth

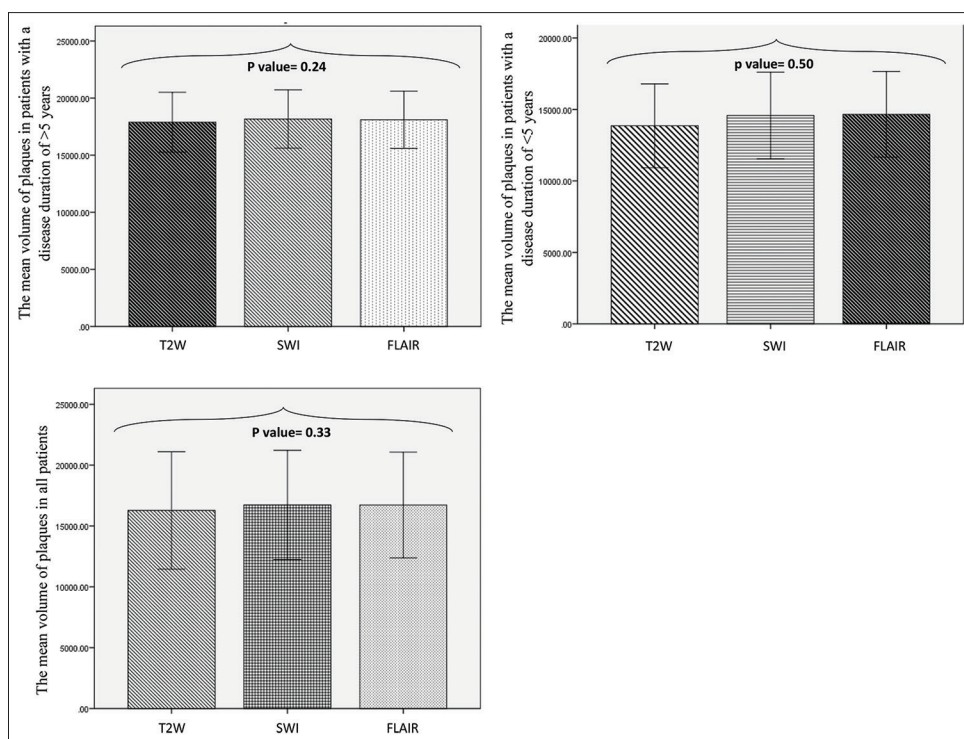


Figure 1: The mean of plaques' volume according to susceptibility weighted imaging, T2-weighted, and fluid-attenuated inversion recovery imaging in multiple sclerosis patients

Table 2: Basic demographic and radiological characteristics of patients

Variables	Mean±SD or n (%)	Disease duration (years)		P*
		>5	<5	
Age	28.48±5.25	28.10±4.66	29.05±6.12	0.54
Gender				
Female	40 (80)	24 (60)	16 (40)	0.64
Male	10 (20)	6 (60)	4 (40)	
EDSS	2.56±1.32	3.08±1.40	1.77±0.62	<0.001
Central vein detection (yes)	42 (84)	25 (59.5)	17 (40.5)	>0.99
T2W plaque number	20.36±8.87	26.07±7.93	13.30±4.43	<0.001
T2W plaque volume	16279.26±2414.44	17890.67±1312.40	13862.15±1468.10	<0.001
SWI plaque number	23.06±9.49	28.47±7.90	14.95±4.65	<0.001
SWI plaque volume	16735.44±2240.81	18174.43±1275.20	14576.95±1514.49	<0.001
FLAIR plaque number	22.20±9.26	27.33±7.92	14.50±4.62	<0.001
FLAIR plaque volume	16731.24±172.23	1811.37±1255.27	14661.05±149.41	<0.001

SWI=Susceptibility-weighted imaging; FLAIR=Fluid-attenuated inversion recovery; EDSS=Expanded disability status scores; SD=Standard deviation; T2W=T2-weighted

Table 3: The correlation between susceptibility-weighted imaging, T2-weighted, and fluid-attenuated inversion recovery imaging in multiple sclerosis plaque assessment

	Volume			Number		
	T2W	SWI	FLAIR	T2W	SWI	FLAIR
T2W	1	0.91*	0.91*	1	0.97*	0.97*
SWI	—	1	0.99*	—	1	0.99*
FLAIR	—	—	1	—	—	1

*P<0.001. SWI=Susceptibility-weighted imaging; FLAIR=Fluid-attenuated inversion recovery; T2W=T2-weighted

among a number of MS patients. According to our study results, higher EDSS was associated with higher disease

duration. We categorized disease duration into more and <5 years, and we found higher EDSS scores among the patients with longer disease duration. Similarly, a recent cohort study showed that increased EDSS rank stability was seen with prolonged disease. Furthermore, the authors concluded that after 4 years after disease onset, EDSS ranking would be helpful for predicting 5-year disease outcome.^[17] In addition, regard to conventional MRI sequences, it has been shown that lesions enhanced by gadolinium were correlated to higher EDSS in relapsing-remitting MS patients and the same correlation has been reported to be between 0.15 and 0.6 considering T2W MRI.^[18] However, using a composition of multiple MRI measures in MS patients

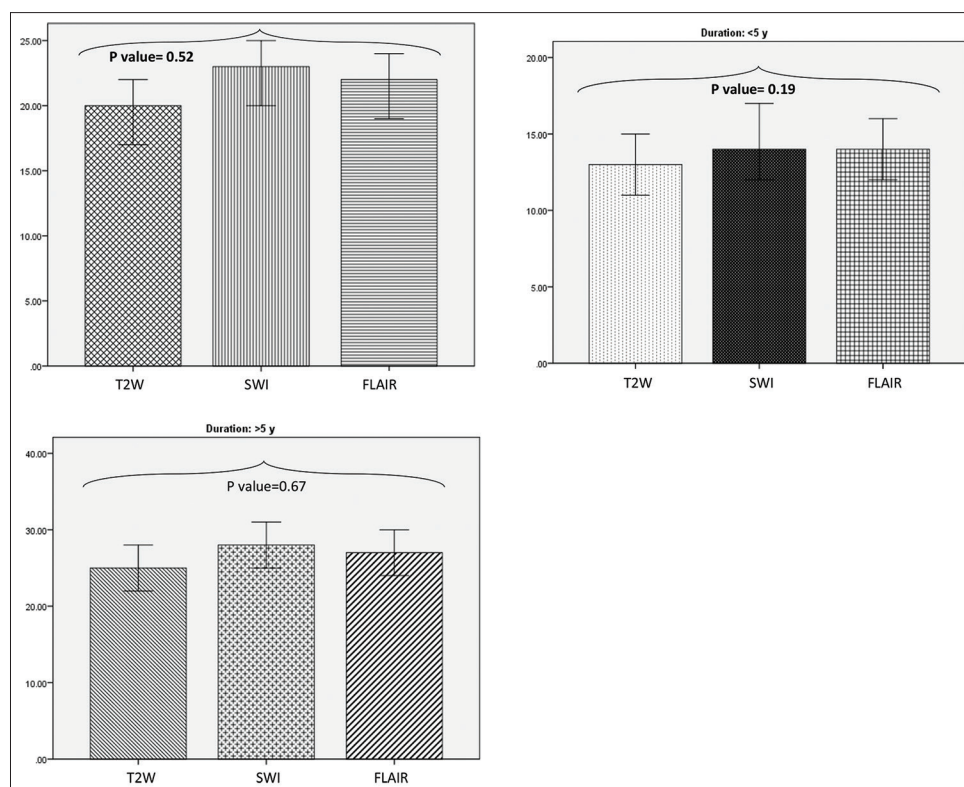


Figure 2: The mean of plaques' number according to susceptibility weighted imaging, T2-weighted, and fluid-attenuated inversion recovery imaging in multiple sclerosis patients

improves the mentioned correlation with EDSS and may provide broader understanding of disease process in the patient.^[19] In consistent with these findings, in our study, the number and volume of lesions that were detected in each sequence, in patients with MS for more than 5 years, were higher than corresponding variables in patients for <5 years. It suggests that more severe MS in a patient presents more detectable radiologic characteristics in comparison with mild or moderate disease.

On the other hand, the number and volume of detected plaques were too close in all sequences, comparing to each other. These results suggest that SWI is at least as efficient as usual sequences to detect MS lesions. Similarly, a recent study on 15 MS patients reported that there is no significant superiority of susceptibility-weighted angiography compared to FLAIR for detecting white matter lesions,^[20] while Haacke *et al.* reported that the number of detected plaques in SWI sequence is 50% more than detected plaques in other sequences.^[14] This controversy may be resulted of using 3T and 4T MRI systems in their study method while we used 1.5T MRI system in the current study. According to previous research, sensitivity and specificity of FLAIR sequence for detecting white matter lesions are different regard to lesions' location^[21] and mentioned sequence might be less sensitive to lesions in the posterior fossa.^[22] These findings, as a part of reasons, have supported developing

new imagery techniques such as SWI to be used for evaluating MS patients.

Early reports of SWI use in patients with MS were inspiring, and this group of sequences gives us much more information in comparison with other neuroimaging sequences. Basically, SWI sequence is the result of merging T2W images with filtered phase gradient echo images. While T2W images show susceptibility contrast, SWI shows susceptibility variation of tissues with higher quality. SWI major limitation was the quantitative evaluation of magnetic susceptibility that properly was resolved by quantitative susceptibility mapping and susceptibility tensor imaging methods.^[23-25]

SWI is an exclusive method, demonstrating tissues with iron deposition in several forms such as deoxyhemoglobin, ferritin, and hemosiderin. The iron deposition lesions/plaques were reported more frequently in our MS patients with prolonged disease. Several studies have shown that abnormal iron deposition in perivascular and parenchymal areas can be suggestive of MS.^[26] The importance of this is due to the fact that visualizing white matter lesions for instance in T2W images is not specific just for diagnosing MS and these lesions can be seen in various pathologic and inflammatory conditions in CNS as well.^[27,28] Hence, the iron deposition in the brain has been reported to be served as a surrogate biomarker for lesions caused

by MS, and this biomarker can be easily detected in SWI sequence, especially in filtered phase SWI.^[14] Furthermore, the presence of central veins within the white matter lesions has been investigated as another radiologic finding in favor of diagnosing MS.^[29,30] In contrast, research exists reporting that central vein detection is not specific for MS, and it should be noted that in our study, central veins in white matter lesions were not associated with disease duration.^[20]

However, there are some limitations to our study. It has been shown that higher magnetic field strength in 7T scanners helps delineating white matter lesions better than 1.5T scanners.^[31] We used 1.5T MRI system for evaluating our MS cases. Therefore, some smaller lesions could be missed in measured sequences. We did not investigate central veins quantitatively as well as iron deposition. Furthermore, we did not investigate our main study variables considering different types of MS such as relapsing-remitting, etc.

CONCLUSION

The results of the present study demonstrated that SWI is as efficient as conventional MRI sequences in the estimation of MS plaques' volume and number.

Acknowledgments

We would like to thank all the participants of this study.

Financial support and sponsorship

This research was funded by Isfahan University of Medical Sciences, Isfahan, Iran.

Conflicts of interest

There are no conflicts of interest.

REFERENCES

- Grabner G, Dal-Bianco A, Schernthaner M, Vass K, Lassmann H, Trattng S, *et al.* Analysis of multiple sclerosis lesions using a fusion of 3.0 T FLAIR and 7.0 T SWI phase: FLAIR SWI. *J Magn Reson Imaging* 2011;33:543-9.
- Suzuki M, Kudo K, Sasaki M, Takahashi S, Takahashi J, Fujima N, *et al.* Detection of active plaques in multiple sclerosis using susceptibility-weighted imaging: Comparison with gadolinium-enhanced MR imaging. *Magn Reson Med Sci* 2011;10:185-92.
- Karussis D. The diagnosis of multiple sclerosis and the various related demyelinating syndromes: A critical review. *J Autoimmun* 2014;48-49:134-42.
- Etemadifar M, Maghzi AH. Sharp increase in the incidence and prevalence of multiple sclerosis in Isfahan, Iran. *Mult Scler* 2011;17:1022-7.
- Ramagopalan SV, Dobson R, Meier UC, Giovannoni G. Multiple sclerosis: Risk factors, prodromes, and potential causal pathways. *Lancet Neurol* 2010;9:727-39.
- Lassmann H. Multiple sclerosis pathology. *Cold Spring Harb Perspect Med* 2018;8. pii: a028936.
- Gawne-Cain ML, O'Riordan JI, Thompson AJ, Moseley IF, Miller DH. Multiple sclerosis lesion detection in the brain: A comparison of fast fluid-attenuated inversion recovery and conventional T2-weighted dual spin echo. *Neurology* 1997;49:364-70.
- Filippi M, Rocca MA. Magnetization transfer magnetic resonance imaging in the assessment of neurological diseases. *J Neuroimaging* 2004;14:303-13.
- Frohman EM, Goodin DS, Calabresi PA, Corboy JR, Coyle PK, Filippi M, *et al.* The utility of MRI in suspected MS: Report of the Therapeutics and Technology Assessment Subcommittee of the American Academy of Neurology. *Neurology* 2003;61:602-11.
- Suwazono Y, Dochi M, Sakata K, Okubo Y, Oishi M, Tanaka K, *et al.* A longitudinal study on the effect of shift work on weight gain in male Japanese workers. *Obesity (Silver Spring)* 2008;16:1887-93.
- Bardin T, Richette P. Nephrogenic systemic fibrosis. *Curr Opin Rheumatol* 2010;22:54-8.
- Rumzan R, Wang JJ, Zeng C, Chen X, Li Y, Luo T, *et al.* Iron deposition in the precentral grey matter in patients with multiple sclerosis: A quantitative study using susceptibility-weighted imaging. *Eur J Radiol* 2013;82:e95-9.
- Zivadinov R, Poloni GU, Marr K, Schirda CV, Magnano CR, Carl E, *et al.* Decreased brain venous vasculature visibility on susceptibility-weighted imaging venography in patients with multiple sclerosis is related to chronic cerebrospinal venous insufficiency. *BMC Neurol* 2011;11:128.
- Haacke EM, Makki M, Ge Y, Maheshwari M, Sehgal V, Hu J, *et al.* Characterizing iron deposition in multiple sclerosis lesions using susceptibility weighted imaging. *J Magn Reson Imaging* 2009;29:537-44.
- Ge Y, Grossman RI, Haacke EM. Susceptibility weighted imaging in multiple sclerosis. In: Haacke EM, Reichenbach JR (ed.). *Susceptibility Weighted Imaging in MRI: Basic Concepts and Clinical Applications*. Hoboken, New Jersey, USA. Wiley-Blackwell 2011. p. 249-64.
- Shiee N, Bazin PL, Zackowski KM, Farrell SK, Harrison DM, Newsome SD, *et al.* Revisiting brain atrophy and its relationship to disability in multiple sclerosis. *PLoS One* 2012;7:e37049.
- Hughes S, Spelman T, Trojano M, Lugaresi A, Izquierdo G, Grand'maison F, *et al.* The kurtzke EDSS rank stability increases 4 years after the onset of multiple sclerosis: Results from the MSBase registry. *J Neurol Neurosurg Psychiatry* 2012;83:305-10.
- Barkhof F. MRI in multiple sclerosis: Correlation with expanded disability status scale (EDSS). *Mult Scler* 1999;5:283-6.
- Poonawalla AH, Datta S, Juneja V, Nelson F, Wolinsky JS, Cutter G, *et al.* Composite MRI scores improve correlation with EDSS in multiple sclerosis. *Mult Scler* 2010;16:1117-25.
- Lummel N, Boeckh-Behrens T, Schoepf V, Burke M, Brückmann H, Linn J, *et al.* Presence of a central vein within white matter lesions on susceptibility weighted imaging: A specific finding for multiple sclerosis? *Neuroradiology* 2011;53:311-7.
- Fernando MS, O'Brien JT, Perry RH, English P, Forster G, McMeekin W, *et al.* Comparison of the pathology of cerebral white matter with post-mortem magnetic resonance imaging (MRI) in the elderly brain. *Neuropathol Appl Neurobiol* 2004;30:385-95.
- Tanaka N, Abe T, Kojima K, Nishimura H, Hayabuchi N. Applicability and advantages of flow artifact-insensitive fluid-attenuated inversion-recovery MR sequences for imaging the posterior fossa. *AJNR Am J Neuroradiol* 2000;21:1095-8.
- Hagemeier J, Heininen-Brown M, Poloni GU, Bergsland N, Magnano CR, Durfee J, *et al.* Iron deposition in multiple sclerosis lesions measured by susceptibility-weighted imaging filtered phase: A case control study. *J Magn Reson Imaging* 2012;36:73-83.
- Habib CA, Liu M, Bawany N, Garbern J, Krumbein I, Mentzel HJ, *et al.* Assessing abnormal iron content in the deep gray matter of patients with multiple sclerosis versus healthy controls. *AJNR Am*

- J Neuroradiol 2012;33:252-8.
25. Manova ES, Habib CA, Boikov AS, Ayaz M, Khan A, Kirsch WM, *et al.* Characterizing the mesencephalon using susceptibility-weighted imaging. *AJNR Am J Neuroradiol* 2009;30:569-74.
 26. Nathoo N, Agrawal S, Wu Y, Haylock-Jacobs S, Yong VW, Foniok T, *et al.* Susceptibility-weighted imaging in the experimental autoimmune encephalomyelitis model of multiple sclerosis indicates elevated deoxyhemoglobin, iron deposition and demyelination. *Mult Scler* 2013;19:721-31.
 27. Launer LJ, Berger K, Breteler MM, Dufouil C, Fuhrer R, Giampaoli S, *et al.* Regional variability in the prevalence of cerebral white matter lesions: An MRI study in 9 european countries (CASCADE). *Neuroepidemiology* 2006;26:23-9.
 28. Wen W, Sachdev P. The topography of white matter hyperintensities on brain MRI in healthy 60- to 64-year-old individuals. *Neuroimage* 2004;22:144-54.
 29. Tallantyre EC, Brookes MJ, Dixon JE, Morgan PS, Evangelou N, Morris PG, *et al.* Demonstrating the perivascular distribution of MS lesions *in vivo* with 7-tesla MRI. *Neurology* 2008;70:2076-8.
 30. Tan IL, van Schijndel RA, Pouwels PJ, van Walderveen MA, Reichenbach JR, Manoliu RA, *et al.* MR venography of multiple sclerosis. *AJNR Am J Neuroradiol* 2000;21:1039-42.
 31. Kollia K, Maderwald S, Putzki N, Schlamann M, Theysohn JM, Kraff O, *et al.* First clinical study on ultra-high-field MR imaging in patients with multiple sclerosis: Comparison of 1.5T and 7T. *AJNR Am J Neuroradiol* 2009;30:699-702.