

The value of thoracic computed tomography scan comparing to reverse transcription–polymerase chain reaction for the diagnosis of COVID-19

Atoosa Adibi¹, Kimia Kazemi¹, Somaye Hajiahmadi¹, Azin Shayganfar¹, Ibrahim Abdollahpour², Amirreza Manteghinejad³, Golnaz Vaseghi⁴, Shaghayegh Haghjooye Javanmard⁵

¹Department of Radiology, Isfahan University of Medical Sciences, Isfahan, Iran, ²Isfahan Neurosciences Research Center, Isfahan University of Medical Sciences, Isfahan, Iran, ³Student Research Committee, School of Medicine, Isfahan University of Medical Sciences, Isfahan, Iran, ⁴Isfahan Cardiovascular Research Center, Cardiovascular Research Institute, Isfahan University of Medical Sciences, Isfahan, Iran, ⁵Applied Physiology Research Center, Isfahan Cardiovascular Research Institute, Isfahan University of Medical Sciences, Isfahan, Iran

Background: Novel coronavirus disease of 2019 (COVID-19) is the current pandemic causing massive morbidity and mortality worldwide. The gold standard diagnostic method in use is reverse transcription–polymerase chain reaction (RT-PCR) which cannot be solely relied upon. Computed tomography (CT) scan is a method currently used for diagnosis of lung disease and can play a substantial role if proved helpful in COVID-19 diagnosis. We conducted this study to evaluate the diagnostic value of CT scan compared to RT-PCR in the diagnosis of COVID-19. **Materials and Methods:** We recruited 291 hospitalized patients suspicious of COVID-19 according to typical clinical findings during February–March 2020. The patients underwent CT-scan and RT-PCR procedures on the day of hospital admission. CT scans were reported by two radiologists as typical, indeterminate, negative, and atypical. Statistical indices were calculated twice: once considering “typical” and “indeterminate” categories as positive and the other time counting “typical” results as positive. **Results:** The CT reports were classified as typical (64.95%), indeterminate (10.31%), atypical (11%), and negative (13.75%). Considering “typical” and “intermediate” as positive, sensitivity and specificity were 85.3% and 38.8%, respectively, and using the second assumption, the mentioned indices were 75.9% and 50.4%, respectively. **Conclusion:** According to our study, CT results do not create enough diagnostic benefit and could result in incorrect confidence if negative. Since widely available, CT integration in the clinical process may be helpful in screening of suspected patients in epidemics. Yet, suspected patients should be isolated till confirmed by (multiple) PCRs.

Key words: COVID-19, computed tomography scan, diagnosis, pandemic, polymerase chain reaction

How to cite this article: Adibi A, Kazemi K, Hajiahmadi S, Shayganfar A, Abdollahpour I, Manteghinejad A, *et al.* The value of thoracic computed tomography scan comparing to reverse transcription–polymerase chain reaction for the diagnosis of COVID-19. *J Res Med Sci* 2021;26:117.

INTRODUCTION

Novel coronavirus disease of 2019, abbreviated as COVID-19, is a viral disease currently affecting the whole world with World Health Organization (WHO) announcing the disease as pandemic on March 11, 2020. This new coronavirus has caused respiratory disease and in some cases severe pneumonia and death. The disease initially started in Wuhan, China, and being highly contagious – according to studies on the reproductive number – it has since spread around

the world.^[1,2] As of this moment, there is no specific pharmacological therapy for COVID-19 making early detection of infected patients and isolating them highly crucial for disease control.

The main diagnosis of COVID-19 is based on the reverse transcription–polymerase chain reaction (RT-PCR) or gene sequencing on respiratory samples. However, RT-PCR has some limitations such as sample collection, transportation, and 6–8 h delay time. The possibility of false negative RT-PCR in the case of insufficient viral load is another major drawback of this method.^[3]

Access this article online

Quick Response Code: 	Website: www.jmsjournal.net
	DOI: 10.4103/jrms.JRMS_1187_20

This is an open access journal, and articles are distributed under the terms of the Creative Commons Attribution-NonCommercial-ShareAlike 4.0 License, which allows others to remix, tweak, and build upon the work non-commercially, as long as appropriate credit is given and the new creations are licensed under the identical terms.

For reprints contact: WKHLRPMedknow_reprints@wolterskluwer.com

Address for correspondence: Dr. Kimia Kazemi, No. 31, Zeitoon Alley, Nakhil Alley, Yahya Ave., Chaharbaghbala Street, Isfahan, Iran.
E-mail: 73kimia@gmail.com

Submitted: 20-Dec-2020; **Revised:** 30-Dec-2020; **Accepted:** 05-Apr-2021; **Published:** 29-Nov-2021

Chest computed tomography (CT) scan, a routine imaging tool for diagnosis of pneumonia, is relatively easy to perform and can be helpful in the fast diagnosis of COVID-19. It has been reported that chest CT shows radiographic features in COVID-19 patients including notable peripheral ground-glass opacities (GGOs) and nodular or mass-like GGO that are often bilateral and multilobar. Additional imaging findings have also been reported as linear, curvilinear, or peribulbar opacities; diffuse GGO; and consolidation.^[4,5] An important concern about using CT scan as a diagnostic tool is similar imaging findings observed in different viral pneumonias rendered by their similar pathogenesis.^[6] Furthermore, typical features are observed in patients with negative RT-PCR results at times.^[7]

Considering PCR limitations and availability of CT-scan and controversial reports regarding its value so far, we have conducted this study to estimate the diagnostic value, specificity, and sensitivity of chest CT scans compared to RT-PCR.

SUBJECTS AND METHODS

This was an observational study aiming at determining the diagnostic value of CT scan compared with PCR, as the gold standard, in the diagnosis of suspected patients with COVID-19 in Isfahan, Iran. The study conformed to the ethical guidelines of the 1975 Declaration of Helsinki and was approved by the ethical committee of Isfahan University of Medical Sciences with Research number of IR.MUI.MED.REC.1399.002.

We recruited 291 hospitalized patients who were suspicious of having COVID-19 according to typical clinical findings for COVID-19 pneumonia and had undergone both CT-scan and PCR procedures on the day of admission to the hospital from 2020 to 02-20-2020-03 to 24. Subjects must have had fever, dyspnea, and cough accompanied with $SpO_2 \leq 93\%$ to be considered as suspicious. The RT-PCR assay was conducted based on the WHO protocol.^[8]

Thoracic CT scan without contrast was performed for all participants using PHILIPS 16-slice scanner with low-dose scan protocol recommended by the Iranian Society of Radiology for COVID 19 pneumonia with parameters of 100–120 Kvp, 50–100 mAs, Pitch = 0.8–1.5, slice thickness of 1–3 mm in the supine position during full inspiration from top to bottom.^[9] The gathered CT images were reported by two radiologists together who were expert in thoracic imaging and blinded to RT-PCR results. The CT-scan findings were subdivided into four categories, i.e., typical, indeterminate, atypical, and negative according to the Radiological Society of North America consensus [Table 1].^[5]

Analysis

Mean age as well as the gender frequencies was reported. Prevalence of patients with COVID-19 in the study sample was calculated by dividing the number of patients with COVID-19 diagnosed by PCR by the total number of recruited subjects. We calculated the diagnostic indices of CT scan, i.e., sensitivity (true positive/the number of COVID-19 patients classified by PCR), specificity (true negative/the number of COVID-19-free subjects classified by PCR), positive predictive value (PPV) (true positive/total positive [true + false]), and negative predictive value (NPV) (true negative/total negative [true + false]). All of the aforementioned indices were calculated twice employing two different approaches; the first time we categorized “typical” and “indeterminate” findings as positive CT results and the second time, we considered only “typical” results as positive and the remaining three categories were classified as negative. We also calculated the area under curve for the study screening test. For all of the above-mentioned indices, a 95% confidence interval (95% CI) was calculated. All of our analyses were done using STATA 12.

RESULTS

Our study included 291 hospitalized patients (161 [55.3%] males and 130 [44.6%] females). The mean age of participants was 53.8 years (standard deviation (SD) of 16.7). One hundred and seventy subjects (99 males, 71 females), composing 58.4% of all subjects, were confirmed with COVID-19 after the PCR test (mean age = 55.2, SD = 16.8). The rest of the subjects (121 patients) comprised 62 males and 59 females with mean age of 51.8 (SD = 16.6).

There was no statistically significant difference between the two groups regarding age and gender ($P = 0.08$ and 0.24 , respectively).

We performed two sets of analyses by using two different CT-scan result categorizations as explained earlier.

First analysis results

Table 2 demonstrates the comparison of PCR results and CT-scan findings of 291 patients in the first analysis. Of 170 patients with COVID-19 diagnosed by PCR, 145 (85.3%) were correctly classified as true positive by CT scan. The specificity of CT scan was 38.8% (95% CI = 30.1%–48.1%). Overall, CT scan correctly categorized 192 (65.9%) of total 291 participants. However, 74 (61.2%) of COVID-19-free patients as well as 25 (14.71%) patients with COVID-19 were mistakenly classified as false positive and false negative, respectively. The PPV as well as the NPV and their 95% CI are demonstrated in Table 3. Positive and negative likelihood ratios were 1.39 and 0.38, respectively [Table 3].

The area under the receiver operating characteristic (ROC) curve was 0.62 (95% CI: 0.57–0.67) [Figure 1].

Second analysis results

Based on the second approach, Table 4 demonstrates the comparison of PCR and CT-scan findings. CT scan accurately categorized 190 (65.2%) of total 291 participants and a total of 101 (34.7%) patients were misclassified as false positive or false negative. The probability of being free of COVID-19 in those with negative CT findings was 59.8% (NPV). Moreover, 68.3% of those with positive CT-scan findings were true COVID-19 patients (PPV) [Table 5]. The area under the ROC curve and 95%CI were 63.1% and 57.6%–68.7%, respectively [Figure 2].

DISCUSSION

COVID-19 is a global issue diagnosed by RT-PCR as the gold standard method with controversy still going on about the value of CT scan in its diagnosis.

Our study showed a relatively high sensitivity of CT scan in disease detection. PPV and specificity had low values but were higher when “typical” CT scan reports were considered as positive test results compared to the time both “typical” and “indeterminate” cases were assumed to be positive.

Up to 85.3% (79.1%–90.3%) sensitivity is detected for chest CT scan in our study. Another less affirmative result from diamond princess cruise ship passengers has shown that 61% of 112 RT-PCR-positive COVID-19 cases had lung opacities on CT and 20% of symptomatic patients had negative thoracic CT scans.^[10] Other studies have also shown that CT scan has a wide sensitivity from 44% to 98% compared to RT-PCR results.^[11-13]

On the other hand, it has been shown that the sensitivity of CT scan for COVID-19 infection diagnosis increases over time after symptom onset.^[14] We used first admission day

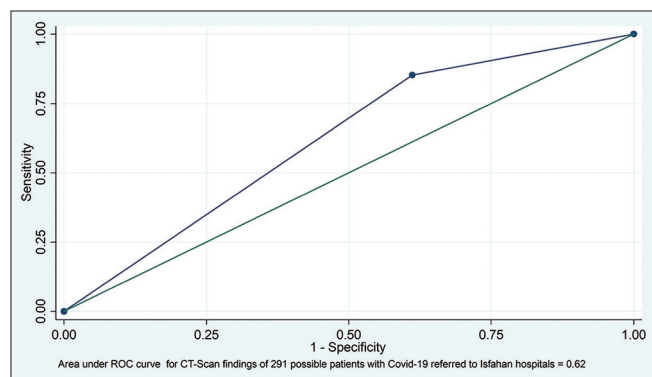


Figure 1: Area under the curve for computed tomography-scan findings of 291 possible patients with COVID-19 referred to Isfahan hospitals = 62%, the first approach

scans in our study so the true sensitivity may be even more than shown in our study.

Table 1: Classification of 291 patients with possible coronavirus disease-2019 admitted to Isfahan hospitals during February-March 2020 using computed tomography scan

COVID-19 CT classification	n (%)
Typical	189 (64.95)
Intermediate	30 (10.31)
Atypical	32 (11.00)
Negative	40 (13.75)

COVID-19=Coronavirus disease-2019; CT=Computed tomography

Table 2: Comparison of polymerase chain reaction results with computed tomography-scan findings of 291 patients with possible coronavirus disease-2019, Isfahan, 2020

CT classification	PCR	
	Positive (%)	Negative (%)
Positive ^a	145 (85.29)	74 (61.16)
Negative ^b	25 (14.71)	47 (38.84)

^aTypical or intermediate; ^bAtypical or negative. PCR=Polymerase chain reaction; CT=Computed tomography

Table 3: Diagnostic values of computed tomography-scan findings, i.e., sensitivity, specificity, positive predictive value, and negative predictive value

CT-scan indices	Diagnostic values, 95% CI
Sensitivity	85.3 (79.1-90.3)
Specificity	38.8 (30.1-48.1)
PPV	66.2 (59.5-72.4)
NPV	65.3 (53.1-76.1)
ROC area	62.1 (0.57-67.2)
Positive likelihood ratio	1.39 (1.19-1.63)
Negative likelihood ratio	0.379 (0.247-0.579)

CT=Computed tomography; PPV=Positive predictive value; NPV=Negative predictive value; ROC=Receiver operating characteristic, CI=Confidence interval

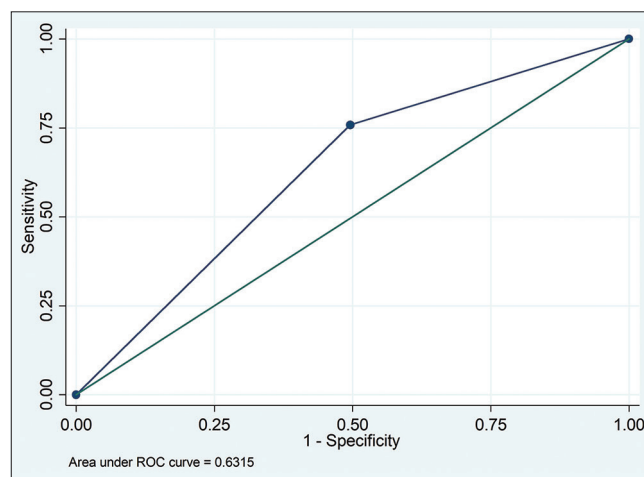


Figure 2: Area under the curve for computed tomography-scan findings of 291 possible patients with COVID-19 referred to Isfahan hospitals = 63.1%, the second approach

Table 4: Comparison of polymerase chain reaction results with computed tomography-scan findings of 291 possible patients with coronavirus disease-2019, Isfahan, 2020

CT classification	PCR	
	Patients with COVID-19 (%)	Free of COVID-19 (%)
Positive ^a	129 (75.88)	60 (49.59)
Negative ^b	41 (24.12)	61 (50.41)

^aTypical; ^bAtypical, intermediate, or negative. PCR=Polymerase chain reaction; CT=Computed tomography; COVID-19=Coronavirus disease-2019

Table 5: Diagnostic values of computed tomography-scan findings, i.e., sensitivity, specificity, positive predictive value, and negative predictive value

CT-scan indices	Diagnostic values, 95% CI
Sensitivity]	75.9 (68.7-82.1)
Specificity	50.4 (41.2-59.6)
PPV	68.3 (61.1-74.8)
NPV	59.8 (49.6-69.4)
ROC area	63.1 (57.6-68.7)

CT=Computed tomography; CI=Confidence interval; PPV=Positive predictive value; NPV=Negative predictive value; ROC=Receiver operating characteristic

We detected very low specificity (38.8% and 50.4%) and near 1 positive likelihood ratio for CT scan in our study which implies that although CT scan may be an acceptable screening tool for COVID-19 in epidemic areas, but its high false-positive results seem to make it inappropriate for true detection of healthy people.

There is no previous report of a high specificity of CT scan in differentiating COVID-19 pneumonia from other viral infections with similar features; however, Esposito *et al.* have shown that predictive values offer a more precise assessment of CT scan's reliability in the current pandemics and that the diagnostic accuracy of CT scan is influenced by disease prevalence. In other words, in the presence of high disease prevalence, the PPV of CT scan will increase even if it is not highly specific.^[15]

Another matter to take into account is that RT-PCR test as the gold standard for COVID-19 diagnosis may be unavailable and is shown to have false-negative results initially in the course of disease due to a lack of replicable nucleic acid or technical errors.^[11] CT-scan abnormalities including peripheral, bilateral areas of well-demarcated GGO affecting predominantly the lower lobes might exist before RT-PCR-positive test results in COVID-19 patients.^[13,16] However, comparable results have been reported in SARS and MERS and would possibly be found if CT was used during any viral pneumonia such as influenza epidemic.^[17,18] Hence, a limitation of our study that could have affected the assessment of specificity and PPV for worse is that we have used the admission-day RT-PCR as gold standard and considered those with

negative PCR tests and positive CT-scan reports as false positives. PCR has been reported to have false-negative results itself. Thus as these patients may have been diagnosed accurately by CT and the actual specificity and PPV may be higher than shown in our study.

CONCLUSION

Relying on CT scan for COVID-19 diagnosis seems wrong and the risk of wide use of the modality must be mentioned. CT-scan results do not create enough diagnostic benefit and could result in incorrect confidence for COVID-19 patients in case of negative results. In the matter of screening, since CT-scan resources are widely available, its integration in the clinical process may be helpful for COVID-19-suspected patients in epidemics, although COVID-19-suspected patients should be isolated and managed till confirmed by (multiple) RT-PCR tests.

Financial support and sponsorship

Nil.

Conflicts of interest

There are no conflicts of interest.

REFERENCES

- Huang C, Wang Y, Li X, Ren L, Zhao J, Hu Y, *et al.* Clinical features of patients infected with 2019 novel coronavirus in Wuhan, China. *Lancet* 2020;395:497-506.
- Wang D, Hu B, Hu C, Zhu F, Liu X, Zhang J, *et al.* Clinical characteristics of 138 hospitalized patients with 2019 novel coronavirus-infected pneumonia in Wuhan, China. *JAMA* 2020;323:1061-9.
- Yang W, Sirajuddin A, Zhang X, Liu G, Teng Z, Zhao S, *et al.* The role of imaging in 2019 novel coronavirus pneumonia (COVID-19). *Eur Radiol* 2020;30:4874-82.
- Vaseghi G, Mansourian M, Karimi R, Heshmat-Gahdarjani K, Baradaran Mahdavi S, Pezeshki A, *et al.* Clinical characterization and chest CT findings in laboratory-confirmed COVID-19: A systematic review and meta-analysis. *medRxiv* 2020; [doi: 10.1101/2020.03.05.20031518].
- Simpson S, Kay FU, Abbara S, Bhalla S, Chung JH, Chung M, *et al.* Radiological Society of North America Expert Consensus Document on Reporting Chest CT Findings Related to COVID-19: Endorsed by the Society of Thoracic Radiology, the American College of Radiology, and RSNA. *Radiol Cardiothorac Imaging* 2020;2:e200152.
- Wang H, Wei R, Rao G, Zhu J, Song B. Characteristic CT findings distinguishing 2019 novel coronavirus disease (COVID-19) from influenza pneumonia. *Eur Radiol* 2020;30:4910-7.
- Long C, Xu H, Shen Q, Zhang X, Fan B, Wang C, Zeng B, *et al.* Diagnosis of the Coronavirus disease (COVID-19): rRT-PCR or CT? *Eur J Radiol.* 2020 May;126:108961. doi: 10.1016/j.ejrad.2020.108961. Epub 2020 Mar 25. PMID: 32229322; PMCID: PMC7102545.
- Protocol: Real-time RT-PCR assays for detection of SARS-CoV-2 Institute Pasteur, Paris. Available from :https://www.who.int/docs/default-source/coronaviruse/real-time-rt-pcr-assays-for-the-detection-of-sars-cov-2-institut-pasteur-paris.pdf?sfvrsn=3662fcb6_2.
- Mahdavi A, Khalili N, Davarpanah A H, Faghihi T, Mahdavi A, *et al.*

- Radiologic Management of COVID-19: Preliminary Experience of the Iranian Society of Radiology COVID-19 Consultant Group (ISRCC), Iran J Radiol. Online ahead of Print ; 17(2):e102324. doi: 10.5812/iranjradiol.102324."
10. Inui S, Fujikawa A, Jitsu M, Kunishima N, Watanabe S, Suzuki Y, *et al.* Erratum: Chest CT Findings in Cases from the Cruise Ship "Diamond Princess" with Coronavirus Disease 2019 (COVID-19). Radiol Cardiothorac Imaging 2020;2:e204002.
 11. Fang Y, Zhang H, Xie J, Lin M, Ying L, Pang P, *et al.* Sensitivity of chest CT for COVID-19: Comparison to RT-PCR. Radiology 2020;296:E115-7.
 12. Ai T, Yang Z, Hou H, Zhan C, Chen C, Lv W, *et al.* Correlation of chest CT and RT-PCR testing for coronavirus disease 2019 (COVID-19) in China: A report of 1014 cases. Radiology 2020;296:E32-40.
 13. Bernheim A, Mei X, Huang M, Yang Y, Fayad ZA, Zhang N, *et al.* Chest CT Findings in Coronavirus Disease-19 (COVID-19): Relationship to duration of infection. Radiology 2020;295:200463.
 14. Wang Y, Dong C, Hu Y, Li C, Ren Q, Zhang X, *et al.* Temporal changes of CT findings in 90 patients with COVID-19 pneumonia: A longitudinal study. Radiology 2020;296:E55-64.
 15. Esposito A, Palmisano A, Scotti GM, Morelli MJ, Vignale D, De Cobelli F, *et al.* Why is chest CT important for early diagnosis of COVID-19? Prevalence matters. medRxiv 2020; [doi: 10.1101/2020.03.30.20047985].
 16. Antonio GE, Ooi CG, Wong KT, Tsui EL, Wong JS, Sy AN, *et al.* Radiographic-clinical correlation in severe acute respiratory syndrome: Study of 1373 patients in Hong Kong. Radiology 2005;237:1081-90.
 17. Das KM, Lee EY, Enani MA, AlJawder SE, Singh R, Bashir S, *et al.* CT correlation with outcomes in 15 patients with acute Middle East respiratory syndrome coronavirus. AJR Am J Roentgenol 2015;204:736-42.
 18. Hope MD, Raptis CA, Shah A, Hammer MM, Henry TS, six signatories. A role for CT in COVID-19? What data really tell us so far. Lancet 2020;395:1189-90.