

Postoperative outcomes of intrasphincteric botox injection during hemorrhoidectomy: A double-blind clinical trial

Mina Alvandipour¹, Mehdi Tavallaei², Fatemeh Rezaei³, Hamed Khodabakhsh⁴

¹Department of Surgery, Faculty of Medicine, Mazandaran University of Medical Sciences, Sari, Mazandaran Province, Iran, ²Department of Surgery, Faculty of Medicine, Isfahan University of Medical Sciences, Isfahan, Iran, ³Department of Medical Surgical Nursing, School of Nursing and Midwifery, Mazandaran University of Medical Sciences, Sari, Iran, ⁴Department of Emergency Medicine, Mazandaran University of Medical Sciences, Sari, Iran

Background: Pain is the most common postoperative complication of hemorrhoidectomy. We evaluated the effectiveness of intrasphincteric Botox injection on posthemorrhoidectomy complications including pain reduction and wound healing. **Materials and Methods:** In this randomized, double-blind clinical trial, patients with Grades 3 or 4 symptomatic hemorrhoids who underwent open (Milligan-Morgan) hemorrhoidectomy were enrolled. The experimental group received intrasphincteric Botox injection during hemorrhoidectomy, while the controls received normal saline injection. Hemorrhoid grades, constipation status, history of hemorrhoidectomy, duration of operation, pain at rest and after defecation in six follow-up periods (6, 12, 24, and 48 h and 7 and 14 days after operation), wound healing (during follow-up after discharge with a 2-week period), analgesic use, and Botox side effects were evaluated and compared in the two experimental and control groups. **Results:** In this trial, 34 and 33 patients were randomly allocated in the experimental and control groups, respectively. Operation time was significantly higher in Botox group ($P = 0.009$). Mean dose of analgesics use in Botox was significantly lower ($P < 0.001$). Rate of wound healing during follow-ups was significantly higher in Botox group in the fifth follow-up ($P = 0.009$). Frequency of urinary retention ($P = 0.02$) and moderate itching ($P = 0.01$) was significantly higher in placebo than Botox group. Mean of postoperative pain at rest in Botox group was significantly lower at 12th, 24th, and 48th h and 7th and 14th days after operation ($P < 0.01$). Mean of postoperative pain in Botox group was significantly lower at 3rd to 5th defecation ($P < 0.01$). **Conclusion:** Our findings indicated that a single-dose injection of Botox during Milligan-Morgan hemorrhoidectomy is associated with less postsurgical pain at rest and during defecation and improved wound healing. It is suggested that it is a safe and effective procedure during hemorrhoidectomy regarding the procedure-related complications.

Key words: Botox, Botulinum toxin, hemorrhoidectomy, pain

How to cite this article: Alvandipour M, Tavallaei M, Rezaei F, Khodabakhsh H. Postoperative outcomes of intrasphincteric botox injection during hemorrhoidectomy: A double-blind clinical trial. J Res Med Sci 2021;26:53.

INTRODUCTION

Hemorrhoids represent one of the most common disorders in the anorectal region. At least 37% of people aged over 37 years suffer from hemorrhoids. Although hemorrhoidectomy is considered a minor surgery, it is accompanied by postoperative complications such as pain, bleeding, feeling of heaviness, itching, mucus secretions, and anal stenosis. These complications can

have many causes including individual tolerance, type of anesthesia, use of postoperative analgesics, and surgical techniques.^[1]

Pain is the most common postoperative complication of hemorrhoidectomy, and thus one of the most important considerations of this surgery is pain control. If pain is controlled, it can allow for an earlier return to work and reduce urinary retention, unsuccessful fecal discharge, and hospitalization costs.^[2]

Access this article online	
Quick Response Code: 	Website: www.jmsjournal.net
	DOI: 10.4103/jrms.JRMS_612_18

This is an open access journal, and articles are distributed under the terms of the Creative Commons Attribution-NonCommercial-ShareAlike 4.0 License, which allows others to remix, tweak, and build upon the work non-commercially, as long as appropriate credit is given and the new creations are licensed under the identical terms.

For reprints contact: WKHLRPMedknow_reprints@wolterskluwer.com

Address for correspondence: Dr. Mehdi Tavallaei, Department of Surgery, Faculty of Medicine, Isfahan University of Medical Sciences, Isfahan, Iran.

E-mail: mehdi.tavallaei2@gmail.com

Submitted: 03-Aug-2018; **Revised:** 15-Aug-2018; **Accepted:** 30-Dec-2020; **Published:** 30-Aug-2021

Discomfort in the anoderm and spasms in the internal sphincter muscles are the two main underlying reasons for posthemorrhoidectomy pain.^[3]

Various surgical and nonsurgical methods have been investigated in order to control pain. Treatments using metronidazole, steroids, nonsteroidal anti-inflammatory drugs, topical anesthetics, and opium have been used and produce different effects; however, since the effects are short term and accompanied by complications; thus, they have limited value.^[4]

Some surgical procedures may reduce anal spasms after hemorrhoidectomy more effectively than others; conversely, some studies have reported that surgical procedure has little impact on pain relief. Moreover, some studies have reported that incontinency can result from surgery.^[5-7]

Evidences indicated that botulinum neurotoxin which is considered as a multipurpose therapeutic agent could be used in several clinical applications in modern medicine. One of the most usage of the neurotoxin is its usage in pain management.^[8]

The role of botulinum neurotoxin in the inhibition of pain receptors has been previously explained.^[9] In addition, the effects of Botox on pain relief in other conditions such as adductor muscle release in patients with cerebral palsy, and in patients with neck dystonia, chronic migraine, piriformis syndrome, chronic epicondylitis, mastectomy, and patients after hernia repair and cholecystectomy have also been evaluated.^[10-12] There were few studies regarding the effectiveness of Botox injection in pain reduction and improving wound healing after hemorrhoidectomy.^[13,14]

Although different clinical uses of Botox have been reported in previous studies^[15] there were limited studies regarding the usefulness of Botox in hemorrhoidectomy. It is suggested that Botox could be a proper analgesic agent for reducing hemorrhoidectomy-related pain and complications due to its some characteristics such as high efficacy, longevity of action, and satisfactory safety profile. So that, we aimed to assess the effects of intrasphincteric Botox injection on posthemorrhoidectomy complications, wound healing, and pain reduction.

MATERIALS AND METHODS

This was a prospective, double-blinded clinical trial conducted at Razi Hospital in Ghaem-Shar and Imam Khomeini Hospital in Sari from March 2015 to March 2016. This study was approved by regional ethics committee of Mazandaran University of Medical Sciences with a research project number of IR.MAZUMS.REC.95.1836.

Seventy patients aged more than 18 years, with 3rd or 4th grades of symptomatic hemorrhoids who indicated for hemorrhoidectomy were recruited to the trial. Patients with inflammatory bowel disease, fistula, fissure, and a history of previous surgery in the anal region, dermatitis, proctitis, pregnancy, and cardiovascular or severe respiratory diseases were excluded. Written informed consent was obtained from the selected patients. Selected patients were randomly allocated to either the Botox or placebo group using table of random numbers. The experimental group received intrasphincteric injections of Botox and the placebo group received normal saline using the same method.

All patients underwent routine clinical assessments including digital rectal examination and proctoscopy. Colonoscopy or sonography was performed according to the recommendation of colorectal surgeon. All routine laboratory tests were performed.

Both surgeon and patients were unaware of the group to which they were assigned.

Although the study was conducted in two centers, all surgeries were performed out by one surgeon (MA) using the same anesthesia protocol in order to reduce any interpersonal variation.

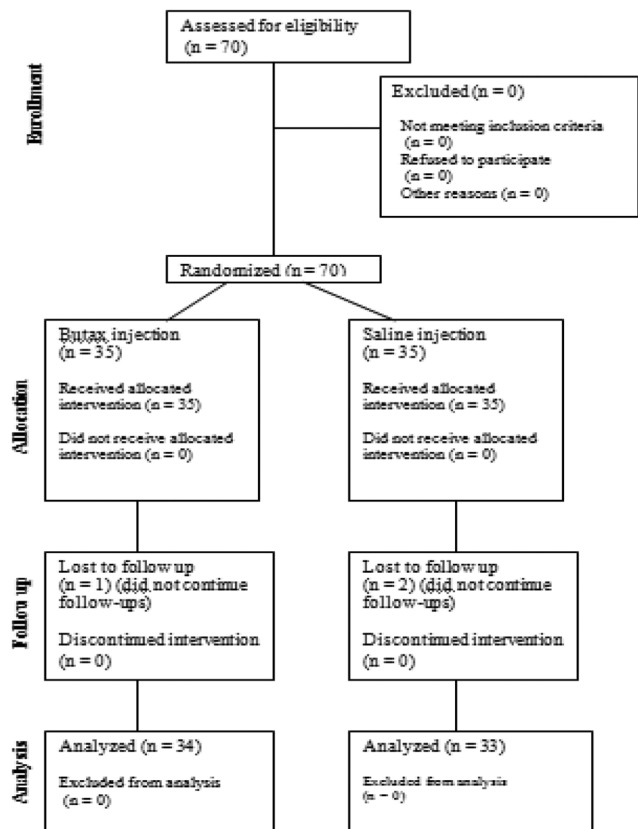


Figure 1: Consort diagram of the study

None of the patients received prophylactic antibiotics. They were sedated with intravenous fentanyl and propofol. Patients were placed in the lithotomy position and underwent electrocautery open hemorrhoidectomy using the Milligan-Morgan technique^[16] by a subspecialist colorectal surgeon.

Botulinum toxin A was diluted in saline (50 units/mL). The Botox solution (0.4 mL; 20 units) was divided into two 0.2 mL doses and injected with a 25G syringe into either side of the anterior midline of the internal sphincter. The placebo group received 0.4 mL of normal saline with a 25G syringe injected into the same regions as other groups. Perioperative management was similar for all patients. Patients received Apotel ampoules 1 g every 6 h IV infusion and patients who had a pain score equal to/above 6 (based on a visual analog scale [VAS]) received intramuscular injections of 0.5 mg/kg morphine sulfate.

A surgical resident, who was blinded to the results of randomization, evaluated the patients before, during, and after surgery. Before surgery, he recorded the baseline characteristics of patients including sex, constipation status before the operation, and history of hemorrhoidectomy. During surgery, the investigator recorded the duration of operation and dose of analgesics used in first 24 h. After operation, the resident evaluated and recorded postoperative complications including bleeding, incontinence, anal stenosis, urinary retention, anal fullness, itching, and amount of secretions.

The primary outcome measures were pain intensity at rest and during defecation which scored based on the VAS by the surgical resident,^[17] at 6 and 12 h after surgery and again on days 1, 2, 7, and 14. Pain from the first to fifth defecation was also evaluated.

The secondary outcome measure was wound healing which was evaluated during follow-ups. Wound healing was assessed in terms of incidence of wound secretions, type of wound discharge, and itching. Five follow-up examinations were performed from day 30 to 4 months after the surgery (follow-up interval was a 2-week period).

The investigator recorded Botox-related complications including perianal thrombosis, subcutaneous abscess, hematoma, perianal itching, and urinary stress incontinence.

Three patients (one from the Botox group and two from the placebo group) were excluded because they did not participate in postsurgical follow-ups.

Statistical analyses

Data were analyzed using Statistical Package for Social Sciences (SPSS Inc., version 21.0, Chicago, IL, USA). Continuous

variables were presented as mean (standard deviation). Categorical variables were presented as number (%). Continuous variables between groups were compared using Student's *t*-test and categorical data were compared using Chi-square and Fisher's exact tests. $P < 0.05$ was considered statistically significant between the two groups.

RESULTS

In this trial from initially allocated seventy patients, three discontinued the follow-ups and finally 67 patients completed the study [Figure 1].

Baseline characteristics of studied patients in the intervention and control groups are presented in Table 1. Two studied groups were similar regarding sex and baseline characteristics.

Operative data (mean duration of operation, mean doses of analgesics in the first 24 h) and postoperative outcomes including frequency of bleeding, gas incontinence, anal stenosis, urinary retention, itching severity, type of wound secretion, and rate of wound healing during follow-ups are presented in Table 2.

Mean duration of operation and mean dose of analgesics use in first 24 h in Botox was significantly higher ($P = 0.009$) and lower ($P < 0.001$) than placebo group, respectively.

From studied postoperative outcomes, frequency of urinary retention ($P = 0.02$) and moderate itching ($P = 0.01$) was significantly higher in placebo than Botox group.

Rate of wound healing (it presented with %) during follow-ups was significantly higher in Botox group than placebo group in the fifth follow-up ($P = 0.009$).

Mean of pain experienced at rest and during defecation at different posthemorrhoidectomy follow-ups based on VAS is presented in Figures 2 and 3.

Mean of postoperative pain at rest in Botox group was significantly lower at 12th, 24th, and 48th h and 7th and 14th days after operation ($P < 0.01$).

Table 1: Baseline characteristics of studied patients in Botox and placebo groups

Variables	Botox group (n=34), n (%)	Placebo group (n=33), n (%)	P
Sex			
Female	13 (38.2)	11 (33.3)	0.43
Male	23 (61.8)	22 (66.7)	
History of constipation	19 (55.9)	18 (52.9)	0.55
History of hemorrhoidectomy	2 (5.9)	2 (6.1)	0.55

Table 2: Operation related variables and postoperative outcomes of studied patients in Botox and placebo groups

Variables	Botox group (n=34), n (%)	Placebo group (n=33), n (%)	P
Operation related variables, mean (SD)			
Duration of operation (min)	14.8 (5.3)	11.6 (4.2)	0.009
Dose of analgesics use in first 24 h (g)	3.8 (1.8)	6.1 (2.6)	<0.001
Postoperative outcomes			
Bleeding	1 (2.9)	3 (9.1)	0.34
Gas incontinence	2 (5.8)	3 (9.1)	0.65
Anal stenosis	0 (0)	1 (3.0)	0.90
Urinary retention	0 (0)	5 (15.1)	0.02
Itching severity*			
Mild	4 (11.8)	2 (6.1)	0.67
Moderate	0 (0)	6 (18.2)	0.01
Severe	0 (0)	2 (6.1)	0.20
Type of wound secretion			
Serous	5 (14.7)	8 (24.2)	0.36
Bloody	2 (5.8)	5 (15.1)	0.25
Suppurative	0 (0)	0 (0)	-
Rate of wound healing during follow ups, mean (SD)			
First	19.0 (5.9)	18.2 (6.3)	0.52
Second	34.8 (8.5)	32.5 (9.1)	0.31
Third	48.8 (9.7)	46.0 (12.2)	0.31
Forth	65.6 (12.1)	61.5 (15.0)	0.22
Fifth	85.0 (12.1)	75.7 (15.6)	0.009

*In the placebo group, six patients were not able to explain their sense of itching. SD=Standard deviation

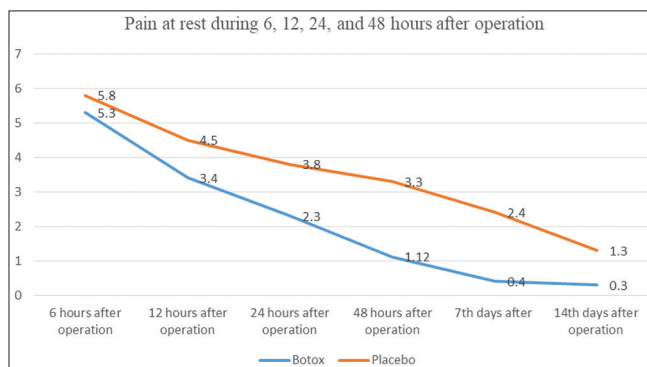


Figure 2: Mean of pain experienced at rest at different posthemorrhoidectomy follow-ups based on visual analog scale in Botox and placebo groups

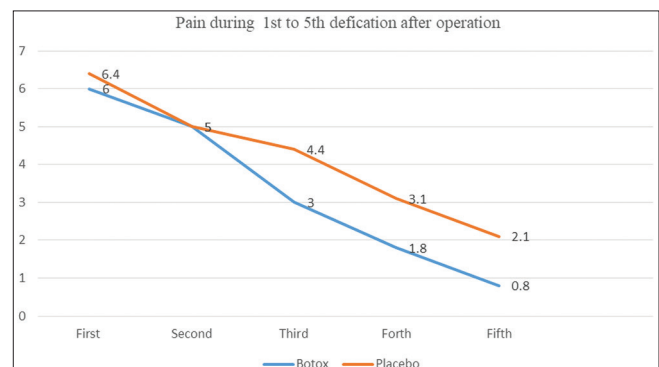


Figure 3: Mean of pain experienced during defecation at different posthemorrhoidectomy follow-ups based on visual analog scale in Botox and placebo groups

Mean of postoperative pain during defecation in Botox group was significantly lower during 3rd to 5th defecation than placebo group ($P < 0.01$).

None of the patients who received Botox complained of adverse effects from this treatment.

DISCUSSION

In this clinical trial, we evaluated the effectiveness of intrasphincteric Botox injections on outcomes of hemorrhoidectomy. Our findings indicated that though by using intrasphincteric Botox injections during hemorrhoidectomy, the operation time was longer, but the frequency of some postoperative complications including urinary retention and itching was lower in Botox group. The

most important and favorable outcome of intrasphincteric Botox injection was reduction of postoperative pain at rest and during defecation and better wound healing at fifth follow-up.

Internal sphincterotomy is one of the procedures used to reduce maximum resting anal pressure (MRP), and it can reduce the number of posthemorrhoidectomy complications. The use of drugs to reduce MRP has increased following the recent introduction of chemical sphincterotomy methods. Studies on the effects of these methods on postsurgical pain – especially after defecation – are rare and controversial.^[13] The use of drugs such as glycerin nitrate to reduce MRP is associated with lower pain at rest but can cause headaches and vertigo, which are not well tolerated by

patients.^[18,19] One nonrandomized prospective study showed that nitroglycerin caused a reduction in pain score, reduced the need for analgesics, and enabled an earlier return to normal physiological state in patients with high MRP but did not affect those with normal MRP before surgery.^[20]

Although botulinum neurotoxin or Botox is considered as a powerful therapeutic agent which is recently used in different medical conditions, there are few studies related to its effectiveness in reducing postoperative pain and wound healing after hemorrhoidectomy.^[8]

Botox inhibits acetylcholine release in presynaptic nerve terminals and subsequent noradrenaline release from sympathetic neural terminals, which causes transient paralysis of the internal sphincter.^[13] However, this drug does not entirely eliminate voluntary sphincter control. Weakness occurs within hours but impulse transmission will recommence following re-growth of new neuromuscular junctions within 3–4 months.^[21]

Botulinum toxin has numerous potential advantages over other methods for the reduction of internal sphincter pressure including single-dose treatment, lack of complications, lower costs and, in time, greater perineal sensitivity of the internal sphincter.^[8]

In this study, we used the Milligan-Morgan hemorrhoidectomy technique. Numerous prospective trials have compared this method with stapled hemorrhoidectomy and found that the stapled hemorrhoidectomy group experienced less pain.^[22-24] However, there are some concerns about the prognosis of the stapled technique including painful defecation and incontinence,^[25] tearing of the internal sphincter,^[26] and costs.^[22] Although the Milligan-Morgan method is still considered as the gold standard method for hemorrhoidectomy, currently, postoperative pain remains the major problem of the method.^[27] So that, the necessity of studying the effectiveness of different agents is considered a priority in this field for surgeons. In current trial, we evaluated the role of Botox in this field.

In literature review, there were three randomized controlled trials which investigated the postoperative outcomes of Botox after Milligan-Morgan hemorrhoidectomy.^[14,28,29]

The first study was conducted by Davies *et al.* in the UK. They studied 49 patients in Botox and normal saline groups. Pain was scored using VAS. They indicated that using Botox resulted in less pain on day 6 and 7 after surgery. They suggested that pain reduction may be due to the decreased spasm within the internal sphincter. They did not report significant difference in analgesic use between two studied groups.^[14]

Patti *et al.* in Italy, in two studies investigated the effectiveness of Botox in posthemorrhoidectomy pain and wound healing. They indicated less pain both at rest and during defecation a week after surgery and less analgesic use as well as proper wound healing without any complication or adverse effects.^[13,28]

Singh *et al.* in the UK, in a prospective randomized controlled trial among 32 patients with Grade 3 and 4 hemorrhoid, demonstrated that Botox did not reduce postoperative pain but it could reduce anal spasm.^[29]

Siddiqui *et al.* in a review study evaluated the effectiveness of different agents used for chemical sphincterotomy after Milligan-Morgan hemorrhoidectomy. They concluded that Botox is one of the agents which could provide proper postoperative pain relief after Milligan-Morgan hemorrhoidectomy.^[30]

In the current study, operation time was significantly higher in Botox group, but the outcomes were more favorable.

In the current study, mean dose of analgesic use in the first 24 h was lower in the Botox group. Davies *et al.* reported no difference between the groups.^[14] Our finding in this regard was similar to Patti *et al.*^[28]

In this study, some complications such as urinary retention and itching were less frequent in Botox group. Previous studies reported that these complications in Botox groups appear comparable to placebo.^[30]

In our study, wound healing was evaluated for 4 months after hemorrhoidectomy. The results showed that the process of wound healing was more advanced in the Botox group than in the placebo group at the end of 4th month (75% in comparison to 85%). Patti *et al.* showed earlier wound healing in Botox group.^[13] In another study, Patti *et al.* compared Botox and glycerin nitrate and found no difference in wound healing between the two groups.^[28] It seems that quicker wound healing is considered an important outcome because consequently it is associated with earlier return to work or normal activity.

The primary outcome of our study was evaluation of pain at rest and during defecation. Our results were similar to that reported by Patti *et al.* and Davies *et al.*^[14,28] Singh *et al.* did not find any significant difference between groups.^[29] It could be explained by that they used local anesthetic at the end of the operation. However, differences in mentioned studies with our may be due to heterogeneity of the trials such as type of botulinum toxin (BOTOX or DYSPORT), using antibiotics, laxative, or other agents during surgery.

The main limitation of the current study was that we did not use anal manometry on patients before or after surgery.

The strength of our study was its design as double-blind prospective clinical trial, larger sample size in comparison with previous studies. Moreover, we compared the outcomes in longer duration.

CONCLUSION

A single-dose injection of botulinum toxin into the internal anal sphincter during Milligan-Morgan hemorrhoidectomy was associated with less postsurgical pain at rest and during defecation and improved wound healing. Botox injection was also more efficient and had fewer complications. Therefore, it is suggested that it is a safe and effective procedure during hemorrhoidectomy regarding the procedure-related complications.

Financial support and sponsorship

Nil.

Conflicts of interest

There are no conflicts of interest.

REFERENCES

- Johanson JF, Sonnenberg A. The prevalence of hemorrhoids and chronic constipation. An epidemiologic study. *Gastroenterology* 1990;98:380-6.
- Pattana-Arun J, Sooriprasoet N, Sahakijrungruang C, Tantiphlachiva K, Rojanasakul A. Closed vs ligasure hemorrhoidectomy: A prospective, randomized clinical trial. *J Med Assoc Thai* 2006;89:453-8.
- Roe AM, Bartolo DC, Vellacott KD, Locke-Edmunds J, Mortensen NJ. Submucosal versus ligation excision haemorrhoidectomy: A comparison of anal sensation, anal sphincter manometry and postoperative pain and function. *Br J Surg* 1987;74:948-51.
- Cheetham M, Phillips R. Evidence-based practice in haemorrhoidectomy. *Colorectal Dis* 2001;3:126-34.
- Alper D, Ram E, Stein GY, Dreznik Z. Resting anal pressure following hemorrhoidectomy and lateral sphincterotomy. *Dis Colon Rectum* 2005;48:2080-4.
- Khubchandani IT. Internal sphincterotomy with hemorrhoidectomy does not relieve pain. *Dis Colon Rectum* 2002;45:1452-7.
- Nelson RL, Chattopadhyay A, Brooks W, Platt I, Paavana T, Earl S. Operative procedures for fissure in ano. *Cochrane Database Syst Rev*. 2011;2011:CD002199.
- Jankovic J. Botulinum toxin: State of the art. *Mov Disord* 2017;32:1131-8.
- Wheeler A, Smith HS. Botulinum toxins: Mechanisms of action, antinociception and clinical applications. *Toxicology* 2013;306:124-46.
- Adler CH. Perioperative use of botulinum toxins. *Toxicol* 2009;54:654-7.
- Jabbari B. Botulinum Toxin Therapy for Prevention of Postsurgical Pain. In *Botulinum Toxin Treatment of Pain Disorders*. Springer, New York, NY. 2015: (pp. 181-192).
- Patti R, Arcara M, Bonventre S, Sammartano S, Sparacello M, Vitello G, *et al.* Randomized clinical trial of botulinum toxin injection for pain relief in patients with thrombosed external haemorrhoids. *Br J Surg* 2008;95:1339-43.
- Patti R, Almasio PL, Muggeo VM, Buscemi S, Arcara M, Matranga S, *et al.* Improvement of wound healing after hemorrhoidectomy: A double-blind, randomized study of botulinum toxin injection. *Dis Colon Rectum* 2005;48:2173-9.
- Davies J, Duffy D, Boyt N, Aghahoseini A, Alexander D, Leveson S. Botulinum toxin (botox) reduces pain after hemorrhoidectomy: Results of a double-blind, randomized study. *Dis Colon Rectum* 2003;46:1097-102.
- Chen S. Clinical uses of botulinum neurotoxins: Current indications, limitations and future developments. *Toxins (Basel)* 2012;4:913-39.
- Milligan E, Morgan CN, Jones L, Officer R. Surgical anatomy of the anal canal, and the operative treatment of haemorrhoids. *Lancet* 1937;230:1119-24.
- Crichton N. Visual analogue scale (VAS). *J Clin Nurs* 2001;10:706-6.
- Liu JW, Lin CC, Kiu KT, Wang CY, Tam KW. Effect of glyceryl trinitrate ointment on pain control after hemorrhoidectomy: A meta-analysis of randomized controlled trials. *World J Surg* 2016;40:215-24.
- Altomare DF, Rinaldi M, Milito G, Arcana F, Spinelli F, Nardelli N, *et al.* Glyceryltrinitrate for chronic anal fissure – Healing or headache? *Dis Colon Rectum* 2000;43:174-9.
- Coskun A, Duzgun S, Uzunkoy A, Bozer M, Aslan O, Canbeyli B. Nitroderm TTS® band application for pain after hemorrhoidectomy. *Dis Colon Rectum* 2001;44:680-5.
- Dressler D. Clinical applications of botulinum toxin. *Curr Opin Microbiol* 2012;15:325-36.
- Ganio E, Altomare DF, Gabrielli F, Milito G, Canuti S. Prospective randomized multicentre trial comparing stapled with open haemorrhoidectomy. *Br J Surg* 2001;88:669-74.
- Mehigan BJ, Monson JR, Hartley JE. Stapling procedure for haemorrhoids versus Milligan-Morgan haemorrhoidectomy: Randomised controlled trial. *Lancet* 2000;355:782-5.
- Rowell M, Bello M, Hemingway DM. Circumferential mucosectomy (stapled haemorrhoidectomy) versus conventional haemorrhoidectomy: Randomised controlled trial. *Lancet* 2000;355:779-81.
- Cheetham MJ, Mortensen NJ, Nystrom PO, Kamm MA, Phillips RK. Persistent pain and faecal urgency after stapled haemorrhoidectomy. *Lancet* 2000;356:730-3.
- Ho YH, Seow-Choen F, Tsang C, Eu KW. Randomized trial assessing anal sphincter injuries after stapled haemorrhoidectomy. *Br J Surg* 2001;88:1449-55.
- Medina-Gallardo A, Curbelo-Peña Y, De Castro X, Roura-Poch P, Roca-Closa J, De Caralt-Mestres E. Is the severe pain after Milligan-Morgan hemorrhoidectomy still currently remaining a major postoperative problem despite being one of the oldest surgical techniques described? A case series of 117 consecutive patients. *Int J Surg Case Rep* 2017;30:73-5.
- Patti R, Almasio PL, Arcara M, Sammartano S, Romano P, Fede C, *et al.* Botulinum toxin vs. topical glyceryl trinitrate ointment for pain control in patients undergoing hemorrhoidectomy: A randomized trial. *Dis Colon Rectum* 2006;49:1741-8.
- Singh B, Box B, Lindsey I, George B, Mortensen N, Cunningham C. Botulinum toxin reduces anal spasm but has no effect on pain after haemorrhoidectomy. *Colorectal Dis* 2009;11:203-7.
- Siddiqui MR, Abraham-Igwe C, Shangumanandan A, Grassi V, Swift I, Abulafi AM. A literature review on the role of chemical sphincterotomy after Milligan-Morgan hemorrhoidectomy. *Int J Colorectal Dis* 2011;26:685-92.