

# Sensitivity and specificity of ultrasound in the diagnosis of traumatic ankle injury

Mehrdad Esmailian<sup>1</sup>, Mahdi Ataie<sup>2</sup>, Omid Ahmadi<sup>2</sup>, Shirvan Rastegar<sup>3</sup>, Atoosa Adibi<sup>4</sup>

<sup>1</sup>Department of Emergency Medicine, Emergency Medicine Research Center, Al-Zahra Research Institute, Isfahan University of Medical Sciences, Isfahan, Iran, <sup>2</sup>Department of Emergency Medicine, School of Medicine, Isfahan University of Medical Sciences, Isfahan, Iran,

<sup>3</sup>Department of Orthopedics, School of Medicine, Isfahan University of Medical Sciences, Isfahan, Iran, <sup>4</sup>Department of Radiology, School of

Medicine, Isfahan University of Medical Sciences, Isfahan, Iran

**Background and Objective:** This study was performed to determine the sensitivity and specificity of ultrasound in the diagnosis of traumatic ankle injury in comparison with magnetic resonance imaging (MRI). **Materials and Methods:** This cross-sectional study was performed on 31 patients with soft-tissue injury or fracture, referring to the MRI imaging center of Alzahra and Kashani Hospitals in Isfahan from October 2018 to March 2019. After an MRI, an ultrasound of the affected ankle was performed for all patients. Sonography and MRI were performed by two radiologists who were blinded to the results of each other's reports. The sensitivity, specificity, positive predictive value, and negative predictive value of sonography were determined. **Results:** In this study, 31 patients with ankle trauma were studied. The mean age of the patients was  $30.73 \pm 10.15$  years; 32.3% were male and 67.7% were female. The sensitivity of ultrasound relative to MRI to detect damage to the anterior talofibular ligament (ATFL), posterior talofibular ligament (PTFL), and calcaneofibular ligament (CFL) was 66.67%, 50%, and 100%, respectively, and the corresponding specificity was 92.86%, 93.10%, and 93.10%, respectively. According to Kappa test, the agreement between ultrasound and MRI methods for detecting injury to ATFL ( $\kappa = 0.51$ ), PTFL ( $\kappa = 0.35$ ), and CFL ( $\kappa = 0.63$ ) was statistically significant ( $P < 0.05$ ). **Conclusion:** Ultrasound is an appropriate modality for the diagnosis of injuries to CFL and ATFL and has shown acceptable results for PTFL. It could be used as an alternative in cases where access to MRI is not available.

**Key words:** Ankle, diagnosis accuracy, magnetic resonance imaging, trauma, ultrasound

**How to cite this article:** Esmailian M, Ataie M, Ahmadi O, Rastegar S, Adibi A. Sensitivity and specificity of ultrasound in the diagnosis of traumatic ankle injury. *J Res Med Sci* 2021;26:14.

## INTRODUCTION

Ankle injuries are one of the common causes of orthopedic emergencies for patients, while only a minority of patients (about 15%) suffer from significant clinical fractures. Ankle sprain is one of the common injuries among people, including athletes, particularly in those engaging in sports such as running, cut-back passes, jumping and lateral jumps, as well as contact sports.<sup>[1,2]</sup> Ankle sprains constitute 12%–20% of all trauma-related injuries in various parts of the body,<sup>[3]</sup> which as a consequence of damage to the sensory-motor receptors and a reduction in stability and balance, the risk

of further injury for active people is more than 80%.<sup>[4,5]</sup> While tomography is conducted in almost all of these patients, in 85% of these cases, it does not provide a positive diagnostic outcome.<sup>[6,7]</sup> In contrast to magnetic resonance imaging (MRI), ultrasonography (US) is a relatively inexpensive, widely available, time-efficient, noninvasive diagnostic procedure. It can be well received as an alternative to MRI procedure if its precision in the diagnosis of the injuries resulting from trauma in the ankle joint is proved.<sup>[8,9]</sup>

Meanwhile, in Iran, MRI is typically used to diagnose trauma-related injuries in various body parts, such as

Access this article online	
Quick Response Code: 	Website: <a href="http://www.jmsjournal.net">www.jmsjournal.net</a>
	DOI: <a href="https://doi.org/10.4103/jrms.JRMS_264_20">10.4103/jrms.JRMS_264_20</a>

This is an open access journal, and articles are distributed under the terms of the Creative Commons Attribution-NonCommercial-ShareAlike 4.0 License, which allows others to remix, tweak, and build upon the work non-commercially, as long as appropriate credit is given and the new creations are licensed under the identical terms.

**For reprints contact:** WKHLRPMedknow\_reprints@wolterskluwer.com

**Address for correspondence:** Dr. Mahdi Ataie, School of Medicine, Isfahan University of Medical Sciences, Isfahan, Iran.

E-mail: mehdi.ataie67@gmail.com

**Submitted:** 12-Mar-2020 **Revised:** 26-Apr-2020 **Accepted:** 05-Oct-2020 **Published:** 27-Feb-2021

the ankle, and US, despite its high diagnostic value, cost efficiency, availability, and lack of evidence proving it ineffective plays a minimal role in the diagnosis of such injuries. However, it is not yet known whether MRI is superior to US in all of the cases, or whether its contrary is correct, or whether these two methods complement each other and can cover each other's deficiencies in various areas. At the same time, in the majority of earlier studies in the field of radiology where MRI had been used to interpret trauma-related injuries in various body parts, US had also contributed to the final diagnosis, which itself can falsely improve the diagnostic value of MRI procedure. Henari and Bank showed that the correlation between ultrasonography and arthrogram findings was 100%, and US diagnosed medial deltoid rupture with a sensitivity of 100% and a specificity of 100%, but plain film radiographs of the ankle were less accurate (sensitivity: 57.1% and specificity: 60%). Therefore, US can be used easily without the need for radiation, especially in trauma services.<sup>[10]</sup> Khoury *et al.* showed that US is an excellent diagnostic modality for ankle trauma because it is not invasive and expensive. They revealed that US could be considered a first-line modality for diagnosis.<sup>[11]</sup> In addition, Ekinci *et al.* indicated that US is a highly sensitive technique to be considered in traumatic wards.<sup>[12]</sup> Taggart *et al.* reported the precise diagnosis of ankle fracture by US in pediatrics. To avoid radiation exposure in pediatrics, US can be employed which is safe and tolerable.<sup>[13]</sup> Although the effectiveness of US to diagnose ankle fractures is reported as 100%, Trinh *et al.* demonstrated the sensitivity of US to be 90.9%.<sup>[14,15]</sup> In a study by Lee and Yun entitled "The feasibility of point-of-care ankle ultrasound examination in patients with a recurrent ankle sprain and chronic ankle instability: Comparison with magnetic resonance imaging," it was found that US was as precise as MRI for diagnosing ankle fracture. Lee and Yun showed noninferiority between the two US and MRI methods, but demonstrated that US is useful for immediate diagnosis and is inexpensive.<sup>[16]</sup> Langner *et al.* did another study focused on MRI and found it useful in detecting bone bruising and fractures.<sup>[17]</sup>

Given the fact that ankle injury is the most common injury,<sup>[18]</sup> the controversial findings, and based on the above points, the purpose of this study is to examine the sensitivity and specificity of sonography in detecting the damage caused by trauma in the ankle compared to MRI to determine whether or not an MRI can provide more information than sonography in the diagnosis of trauma-related injuries in the ankle.

## MATERIALS AND METHODS

### Study design and participants

In this cross-sectional study, 31 patients with ankle trauma referred to the MRI imaging center of Alzahra and Kashani

Hospitals of Isfahan from October 2018 to March 2019 were studied according to the inclusion criteria. A census method of sampling was used, and all the patients satisfying the inclusion criteria entered into the study.

The inclusion criteria included all patients with traumatic ankles, with age range over 18 years, with written informed consent for participation in the study, and with no addiction. It was a census study, and all patients, according to the Ottawa criteria, needed the necessary imaging to determine the type of injury they were enrolled in the study.

On the other hand, individuals were excluded from the study if the necessary imaging was not obtained within the 1<sup>st</sup> week after the injury, or there were short reports in their ultrasonography or MRI, or there was only one of the imaging modalities available. Due to the tenderness in the ankle or midfoot area, radiography was requested for the same area.

### Procedures

At the time of the referral of these patients for MRI, ankle ultrasonography was performed by a radiologist. After taking MRI imaging, it was reviewed by an experienced musculoskeletal radiologist who was not aware of the result of ultrasonography and wrote the final report of patients' MRI. A common code was considered for orthopedic, ultrasonography, and MRI responses. Regarding blinding, it should be noted that our study was not a clinical trial and was not mandatory to use blinding in this study but it was followed to avoid bias in the results of the study. It was possible that the results of MRI be affected by MRI radiologists after revealing the results of the US. Hence, we tried to blind the sonographers and MRI radiologists from the results of MRI and US, respectively.

To obtain an ultrasound evaluation, three ligaments were investigated: the anterior talofibular ligament (ATFL), posterior talofibular ligament (PTFL), and calcaneofibular ligament (CFL). PTFL patients should be supine with a flexed knee with placing the plantar surface of their foot flat. ATFL is checked while the ankle is gently inverted and, for CFL, the ankle should be medially rotated.

To control the quality of the results, 10% of the ultrasonography cases were controlled by another radiologist who was unaware of the results of the initial ultrasonography. Furthermore, 10% of the MRI cases were separately examined by a different radiologist in addition to the original radiologist. Ligaments that are damaged in any way (tearing or partially torn) were determined by each of these modalities, and the results of all cases were matched.

An MRI device was used (GE 1.5 Tesla, General Electric Company, New York, United States of America). The ankle

ultrasonography was performed by GE- $\alpha$ 200 (General Electric Company) using a linear probe with a frequency of 7.5 MHz.

The collected variables included age, sex, tenderness area, weight intolerance, and abnormal findings in radiology, ultrasonography, and MRI. In addition, the damage to the ATFL, PTFL, and CFL in ligament was checked.

MRI and ultrasonography were studied, and the sensitivity and specificity of the damage to each ligament were checked.

### Ethical considerations

This study has been approved by the ethics committee of Isfahan University of Medical Sciences, and the approval code is IR.MUI.REC.1396.3.831.

### Statistical analysis

Data from this study were entered into SPSS version 24 software (SPSS, Inc., Chicago, IL, USA); descriptive data were presented as mean and standard deviation or frequency or percentage. Receiver operating characteristic curve was used to measure the sensitivity and specificity. To check the accordance between ultrasonography and MRI, the Kappa test was used. In all of the calculations, *P* value was considered  $<0.05$ .

## RESULTS

Thirty-one patients with ankle trauma were enrolled in the study with a mean age of  $30.73 \pm 10.15$  years, of whom 32% were male and 67.7% were female, with 83.9% having pain and tenderness in the ankle. Moreover, 35.5% of the patients had weight intolerance with no abnormal results reported in the radiographic film, such as rupture or damage to the soft tissue. In the case of ultrasound, 12.9% of the patients had damage in ATFL, 9.7% in PTFL, and 12.9% in CFLs. Moreover, in the case of MRI, injuries to ATFL were 9.7%, PTFL were 6.5%, and CFLs were 6.5% [Table 1].

The sensitivity and specificity of ultrasound relative to MRI for detecting injury to ATFL were 66.67% and 92.86%, respectively, with the positive and negative predictive values as 50% and 96.30%, respectively.

The sensitivity and specificity of ultrasound relative to MRI for detecting injury to PTFL were 50% and 93.10%, respectively, with the positive and negative predictive values as 33.33% and 96.43%, respectively.

The sensitivity and specificity of ultrasound relative to MRI for detecting injury to CFL were 100% and 93.10%, respectively, with positive and negative predictive values as 50% and 100%, respectively.

**Table 1: Description of variables studied in this research**

Variables	Abundance	Percentage
Gender		
Male	10	32.3
Female	21	67.7
Place of pain and tenderness		
Ankle	26	83.9
Midfoot	5	16.1
Weight intolerance	11	35.5
Radical findings (abnormal)	0	0
Having an injury in ultrasound		
ATFL	4	12.9
PTFL	3	9.7
CFL	4	12.9
Having an injury in MRI		
ATFL	3	9.7
PTFL	2	6.5
CFL	2	6.5

MRI=Magnetic resonance imaging; ATFL=Anterior talofibular ligament; PTFL=Posterior talofibular ligament; CFL=Calcaneofibular ligament

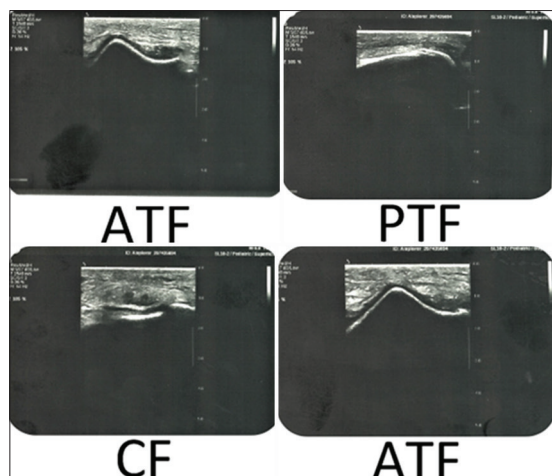
According to Kappa test, the agreement between ultrasound and MRI methods for detecting injury to ATFL ( $\kappa = 0.51$ ), PTFL ( $\kappa = 0.35$ ), and CFL ( $\kappa = 0.63$ ) was statistically significant ( $P < 0.05$ ).

Figure 1 demonstrates MRI of the right ankle without contrast media, coronal and sagittal Short-TI Inversion Recovery, sagittal and axial T2-weighted image (WI), and coronal T1-W1. Joint effusion was seen at the tibiotalar and subtalar joints. Fluid was seen around the ankle tendons, mainly posteromedial tendon in favor of tendinopathy and tenosynovitis; bone bruise and bony contusion were seen at the calcaneal bone; bone bruise and trabecular injury were seen at the medial malleoli; the sign of sprain injury was seen at the superficial part of the deltoid ligament; and the interosseous ligament between the radius and calcaneus was intact.

## DISCUSSION

This study aimed to check the sensitivity and specificity of ultrasound in the diagnosis of ankle injuries in comparison with MRI. The results of this study show that the sensitivity and specificity of sonography were 66.67% and 92.86%, respectively, in comparison with MRI in the diagnosis of injuries in the ATFL. The positive and negative predictive values of sonography were 50% and 96.3%, respectively. The sensitivity, specificity, positive predictive value, and negative predictive value of ultrasound for PTFL were 50%, 93.1%, 33.33%, and 96.43% and the corresponding values for CFL were 100%, 93.1%, 50%, and 100%, respectively.

In recent years, various studies have investigated the efficacy of ultrasound in the diagnosis of injuries to different



**Figure 1:** Magnetic resonance imaging of the right ankle without contrast media; coronal and sagittal Short-T1 inversion recovery; sagittal and axial T2-weighted images; and coronal T1-weighted images

ligaments. In a study by Barzin *et al.*, the sensitivity, specificity, positive predictive value, and negative predictive value of sonography in comparison with MRI in the diagnosis of injuries of posterior collateral ligament were 100%, 94.28%, 42.86%, and 100%, respectively. Furthermore, in the diagnosis of the anterior cruciate ligament, the corresponding values were determined as 65%, 100%, 100%, and 70.21%, respectively. Moreover, the corresponding values were determined at 61.90%, 94.23%, 81.25%, 25.81%, and 85.96% in the diagnosis of injuries in the medial meniscus, and 100%, 97.14%, 60%, and 100%, respectively, in the case of lateral meniscus injuries.<sup>[19]</sup> In addition, in a study by Salehi *et al.*, out of 100 cases of surgery conducted on the shoulder rotator cuffs, 27 rupture cases were reported consisting of 20 full ruptures and 7 partial ruptures. The sensitivity, specificity, positive predictive value, and negative predictive value in sonography were determined as 92.6%, 95.9%, 89.3%, and 97.2%, respectively, and, for the MRI, the corresponding values were determined as 96.3%, 97.3%, 95.9%, and 98.6% respectively.<sup>[20]</sup>

In a study by Court-Payen, the sensitivity and specificity of the sonography were determined as 75%–95% and 78%–100%, respectively.<sup>[21]</sup> These results confirm that ultrasound could be a proper modality for ligament injury, especially for superficial ligaments. As the ATFL is located in the superficial layers, sonography can be almost as practical as MRI in the diagnosis of its rupture. Our study demonstrated that ultrasound at 96.3% of the cases would be able to determine the health of ATFL. This result was repeated in a study by Oae *et al.* in 2010 that showed that ultrasound has a satisfactory diagnostic accuracy for ATFL injuries. Therefore, sonography can be suggested as a suitable noninvasive procedure for the diagnosis of injuries in the ATFL.<sup>[22]</sup>

In the present study, the sensitivity of sonography in comparison with MRI in the diagnosis of rupture in CFL was 100%, and its specificity was 93.10% that is a high diagnostic value. In a recent review by Seok *et al.* in 2019, the average sensitivity and specificity of ankle ultrasound were 95% and 99%, respectively.<sup>[23]</sup> It means that, in case of an injury or lack thereof in the CFL, sonography is capable of providing a reliable diagnosis. Considering the positive and negative predictive values of 50% and 100% for sonography, it can be said that a sonography scan can be as useful as an MRI in detecting or rejecting the rupture cases in the CFL. There is controversy in the diagnostic accuracy of ultrasound for PTFL injuries. As this ligament is placed deeper, several studies declare evaluation of the PTFL in ultrasound to be difficult. Our study showed an acceptable high specificity rate of ultrasound in comparison with MRI.<sup>[24-26]</sup> However, this difficulty could be the reason for the 50% sensitivity in our study.

There are limitations to this study, including small sample size and not checking the other useful variables for the diagnosis of an ankle injury. The small amount of research in this field was the other restricting factor of our study.

## CONCLUSION

It can be concluded that ultrasound is a useful diagnostic method to detect injuries to specific ankle ligaments. The diagnostic value of ultrasound for injuries of CFL is nearly 100% and, for ATFL, it showed satisfactory results; it was lower for PTFL than the other two ligaments. This modality can be helpful in cases where methods such as MRI are unavailable.

## Financial support and sponsorship

Nil.

## Conflicts of interest

There are no conflicts of interest.

## REFERENCES

1. Woods C, Hawkins R, Hulse M, Hodson A. The Football Association Medical Research programme: An audit of injuries in professional football: An analysis of ankle sprains. *Br J Sports Med* 2003;37:233-8.
2. Simpson KJ, Cravens S, Higbie E, Theodorou C, DelRey P. A comparison of the Sport Stirrup, Malleoloc, and Swede-O ankle orthoses for the foot-ankle kinematics of a rapid lateral movement. *Int J Sports Med* 1999;20:396-402.
3. Orchard JW, Powell JW. Risk of knee and ankle sprains under various weather conditions in American football. *Med Sci Sports Exerc* 2003;35:1118-23.
4. Gribble P, Hertel J. Consideration for the normalizing measure of the star excursion balance test. *Meas Phys Educ Exerc Sci* 2003;7:89-100.
5. Hubbard TJ, Hicks-Little CA. Ankle ligament healing after an



- acute ankle sprain: An evidence-based approach. *J Athl Train* 2008;43:523-9.
6. Brandser EA, Berbaum KS, Dorfman DD, Braksiek RJ, El-Khoury GY, Saltzman CL, *et al.* Contribution of individual projections alone and in combination for radiographic detection of ankle fractures. *AJR Am J Roentgenol* 2000;174:1691-7.
  7. Stiell IG, McKnight RD, Greenberg GH, McDowell I, Nair RC, Wells GA, *et al.* Implementation of the Ottawa ankle rules. *JAMA* 1994;271:827-32.
  8. Khan Z, Faruqi Z, Ogyunbiyi O, Rosset G, Iqbal J. Ultrasound assessment of internal derangement of the knee. *Acta Orthop Belg* 2006;72:72-6.
  9. Park GY, Kim JM, Lee SM, Lee MY. The value of ultrasonography in the detection of meniscal tears diagnosed by magnetic resonance imaging. *Am J Phys Med Rehabil* 2008;87:14-20.
  10. Henari S, Banks LN, Radovanovic I, Queally J, Morris S. Ultrasonography as a diagnostic tool in assessing deltoid ligament injury in supination external rotation fractures of the ankle. *Orthopedics* 2011;34:e639-43.
  11. Khoury V, Guillin R, Dhanju J, Cardinal É. Ultrasound of ankle and foot: Overuse and sports injuries. *Semin Musculoskelet Radiol* 2007;11:149-61.
  12. Ekinci S, Polat O, Günalp M, Demirkan A, Koca A. The accuracy of ultrasound evaluation in foot and ankle trauma. *Am J Emerg Med* 2013;31:1551-5.
  13. Taggart I, Voskoboynik N, Shah S, Liebmann O. ED point-of-care ultrasound in the diagnosis of ankle fractures in children. *Am J Emerg Med* 2012;30:1328.
  14. Canagasabay MD, Callaghan MJ, Carley S. The sonographic Ottawa foot and ankle rules study (the SOFAR study). *Emerg Med J* 2011;28:838-40.
  15. Trinh E, McMillan D, Gough JE, Brewer KL. Emergency department use of ultrasonography to detect lateral ankle fractures. *Ann Emerg Med* 2004;44:S61-2.
  16. Lee SH, Yun SJ. The feasibility of point-of-care ankle ultrasound examination in patients with recurrent ankle sprain and chronic ankle instability: Comparison with magnetic resonance imaging. *Injury* 2017;48:2323-8.
  17. Langner I, Frank M, Kuehn JP, Hinz P, Ekkernkamp A, Hosten N, *et al.* Acute inversion injury of the ankle without radiological abnormalities: Assessment with high-field MR imaging and correlation of findings with clinical outcome. *Skeletal Radiol* 2011;40:423-30.
  18. Pijnenburg AC, Glas AS, De Roos MA, Bogaard K, Lijmer JG, Bossuyt PM, *et al.* Radiography in acute ankle injuries: The Ottawa ankle rules versus local diagnostic decision rules. *Ann Emerg Med* 2002;39:599-604.
  19. Barzin M, Abdi R, Golmohammadi H. Diagnostic accuracy of ultrasonography in comparison with magnetic resonance imaging in patients with knee trauma. *J Gorgan Univ Med Sci* 2012;14:92-7.
  20. Salehi MG, Mardanpour K, Rezaei M, Moradi N. Comparison of diagnostic value of ultrasonography versus magnetic resonance imaging in the diagnosis of shoulder rotator cuff muscles tears. *SJKU* 2014;19:108-13.
  21. Court-Payen M. Sonography of the knee: Intra-articular pathology. *J Clin Ultrasound* 2004;32:481-90.
  22. Oae K, Takao M, Uchio Y, Ochi M. Evaluation of anterior talofibular ligament injury with stress radiography, ultrasonography and MR imaging. *Skeletal Radiol* 2010;39:41-7.
  23. Seok H, Lee SH, Yun SJ. Diagnostic performance of ankle ultrasound for diagnosing anterior talofibular and calcaneofibular ligament injuries: A meta-analysis. *Acta Radiol* 2020;61:651-61.
  24. Park JW, Lee SJ, Choo HJ, Kim SK, Gwak HC, Lee SM. Ultrasonography of the ankle joint. *Ultrasonography* 2017;36:321-35.
  25. Singh K, Thukral CL, Gupta K, Singh A. Comparison of high resolution ultrasonography with clinical findings in patients with ankle pain. *J Ultrason* 2018;18:316-24.
  26. Chardoli MM, Bahramnejad A, Kakvan P. The diagnostic value of ultrasonography in the diagnosis of scaphoid bone fractures. *J Prev Epidemiol* 2018;3:e09.