

Premature pubarche as a first presentation of pituitary macroprolactinoma

Fatemeh Tabatabaei¹, Mohammad Reza Sharif², Hossein Nasr Esfahani³, Raziieh Yazdi Zahrani⁴, Abolfazl Taheri⁵, Rokhsareh Mearmar⁴

¹Clinical Research Development Research Centre, Najafabad Branch, Islamic Azad University, Najafabad, Iran, ²Infectious Diseases Research Center, Kashan University of Medical Sciences, Kashan, Iran, ³Department of Ophthalmology, School of Medicine, Najafabad University, Shariati Hospital, Isfahan, Iran, ⁴Isfahan Clinical Toxicology Research Center, Isfahan University of Medical Sciences, Isfahan, Iran, ⁵Health Information Technology Research Center, Clinical Information's Research Group, Isfahan University of Medical Sciences, Isfahan, Iran

Prolactinoma is a rare tumor of childhood. Clinical presentations of prolactinoma include amenorrhea, delayed puberty, and galactorrhea. For the first time, in this case, elevated prolactin levels were associated with unexpected premature pubarche. We describe an 8-year, 7-month-old boy with acne and gradual appearance of pubic hair, corresponding to tanner stage 2. Hormonal tests showed severe hyperprolactinemia (prolactin = 246.8 µg/L and pooled prolactin = 175 µg/L and macroprolactin = 5 µg/L) and mildly elevated level of dehydroepiandrosterone sulfate (DHEAS) and testosterone. Magnetic resonance imaging (MRI) findings confirmed the presence of a pituitary macroprolactinoma, measuring 14 mm × 12 mm × 8 mm on the right side of the pituitary gland. Cabergoline therapy was commenced (0.5 mg/week) and after 3 months, no evidence of pubarche progression was observed. Prolactin level and tumor size markedly reduced. At the 9-month follow-up visit, a normal MRI was reported. This case highlights that even when facing premature pubarche, careful examination is mandatory, and if no obvious etiology is found for premature pubarche, clinicians should consider prolactinoma.

Key words: Adrenarche, child, child/growth and development, dehydroepiandrosterone sulfate (DHEAS), precocious puberty, prolactinoma, puberty

How to cite this article: Tabatabaei F, Sharif MR, Nasr Esfahani H, Yazdi Zahrani R, Taheri A, Mearmar R. Premature pubarche as a first presentation of pituitary macroprolactinoma. *J Res Med Sci* 2020;25:108.

INTRODUCTION

Pediatric prolactinoma, a benign pituitary adenoma secreting prolactin, typically occurs at the age when puberty begins.^[1,2] There are no distinctive clinical symptoms, headache is the most prevalent complaint at diagnosis, and a large tumor mass can also present with visual disturbance. Galactorrhea and delayed pubertal development are other symptoms. Incidence rate shows that it is infrequent (<0.1/1000,000 persons),^[1] yet it accounts for 50% of all pituitary adenomas and 2% of intracranial tumors.^[3,4]

The term macroprolactinoma is used when the size of these tumors are 1 cm or more.^[5,6]

Most symptoms of these tumors are due to the extreme production of prolactin and problems caused by the compressive effects of the tumor on adjacent neural structures. Macroprolactinoma is diagnosed and managed according to the serum prolactin levels and the appearances of the pituitary gland on magnetic resonance imaging (MRI).^[6] The best recommended medical treatment is dopamine agonists.^[5]

The majority of tumors are brought to attention clinically during puberty, with females incidence rate 5 times more than males.^[6,7] The most common presentation in girls is primary and secondary amenorrhea. Growth arrest, delayed puberty, and galactorrhea are more encountered in boys.^[7,8] Tütüncüler *et al.* presented six

Access this article online	
Quick Response Code: 	Website: www.jmsjournal.net
	DOI: 10.4103/jrms.JRMS_118_20

This is an open access journal, and articles are distributed under the terms of the Creative Commons Attribution-NonCommercial-ShareAlike 4.0 License, which allows others to remix, tweak, and build upon the work non-commercially, as long as appropriate credit is given and the new creations are licensed under the identical terms.

For reprints contact: WKHLRPMedknow_reprints@wolterskluwer.com

Address for correspondence: Dr. Rokhsareh Mearmar, Isfahan Clinical Toxicology Research Center, Isfahan University of Medical Sciences, Isfahan, Iran. E-mail: mearmar@pharm.mui.ac.ir

Submitted: 02-Feb-2020; **Revised:** 15-Mar-2020; **Accepted:** 27-Jul-2020; **Published:** 26-Nov-2020

patients with macroprolactinemia with elevated levels of PRL. One of whom was asymptomatic and the other five either had headache, menstrual disturbance, short stature, increased hair growth, or premature puberty.^[8]

The presence and development of the genital/axillary hair before the age of 8 years in girls and 9 years in boys is the most imperative symptom of premature pubarche. However, other symptoms of puberty or virilization did not progress.^[9] Early pubertal changes do not necessarily mean precocious puberty. In our case for the first time, elevated PRL levels were accompanied with unexpected premature pubarche.

CASE REPORT

An 8-year, 7-month-old boy with nonconsanguineous parents was seen in the endocrinology clinic for acne and gradual appearance of the pubic hair during the past 2 months. He had no history of headache, vomiting, convulsion, galactorrhea, or any other past medical or drug history.

On physical examination, his height was 128 cm (on 25% percentile of height) and his weight was 31 kg (on 75% percentile of weight), body mass index was 18.92 kg/m², axillary hair growth was at tanner stage 1, pubic hair was at tanner stage 2, testes were stage 1 tanner, and volume of both right and left testes was <4 mL.

In laboratory examinations, serum electrolytes (Na, K, Ca, and P) were all normal. Mildly elevated levels of dehydroepiandrosterone sulfate (DHEAS) and testosterone were detected in accordance with second stage of tanner (DHEAS = 15–97 µg/dl, testosterone = 0.2–0.8 ng/mL). In addition, hyperprolactinemia (prolactin = 246.8 µg/L and pooled prolactin = 175 µg/L and macroprolactin = 5 µg/L) was detected [Table 1].

Pituitary MRI showed a pituitary macroadenoma, measuring 14 mm × 12 mm × 8 mm on the right side of the pituitary gland with thin ring enhancement on postcontrast images, with features consistent with macroprolactinoma [Figure 1].

Extrasellar extension was not present. The visual field examination and examinations of other systems were normal. Wrist X-ray revealed bone age of 9 years.

The patient’s parents were informed about his disease and cabergoline therapy (0.5 mg/week) was started for prolactinoma. After 3 months, no evidence of pubarche progression was observed and prolactin and tumor size markedly reduced. Level of serum prolactin reached 30 and 14.8 µg/L, on follow-up of 3 and 9 months later, respectively. In the second MRI report, a 10 mm × 5 mm simple cyst was seen on the right side. However, at the 9th month control visit, normal MRI was reported. The patient is still being followed at our clinic and continues cabergoline therapy.

DISCUSSION

In this study, we presented an 8-year, 7-month-old boy with premature pubarche with prolactinoma and a little elevated level of DHEA and testosterone in accordance with stage 2 tanner.^[10] We excluded any other etiology for pubarche.

The appearance of pubic hair (pubarche) occurs due to stimulation of androgen-sensitive hair follicles. Adrenarche is presented with rising in the adrenal production of the 17-ketosteroids DHEAS and DHEA-sulfate.^[11] This can

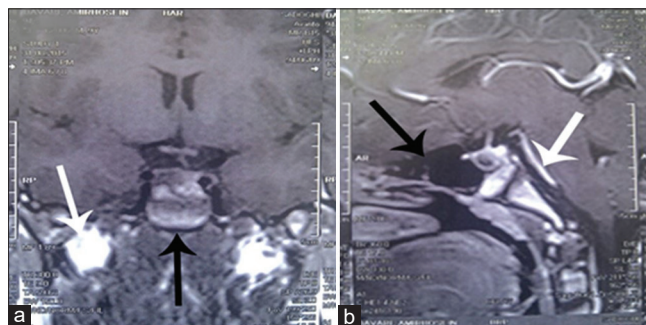


Figure 1: Brain magnetic resonance imaging, demonstrating a pituitary macroadenoma measuring 14 mm × 12 mm × 8 mm; (a) Coronal; white arrow refers to optic nerve without any pressure effect, black arrow shows adenoma and (b) sagittal planes; white arrow refers to basilar artery and black arrow shows empty sella tursica induced by pressure effects of adenoma

Table 1: The results of the endocrine tests at baseline and follow-up

Parameters	Baseline	3 th month later	9 th month later	Normal reference range
TSH	2.8 mu/l	3.4 mu/l	3.1 mu/l	0.5-5 mu/l
T4	8.3 µg/dl	6.3 µg/dl	7.4 µg/dl	6.4-15 µg/dl
DHEAS	16 µg/dl			<15 µg/dl
Testosterone	0.4 ng/ml			<0.4 ng/ml
Prolactin	246.8 µg/L	30 µg/L	14.8 µg/L	1.8-20.3 µg/L
Pooled prolactin	175 µg/L			
Macroprolactin	5 µg/L			
17OH Progesterone (RIA)	0.8 ng/dL			0.2-0.8 µg/dl
Cortisol (8 AM)	8.5 µg/dl			6.2-19.4 µg/dl

TSH=Thyroid stimulating hormone; T4=Thyroxine; DHEAS=dehydroepiandrosterone sulfate

explain premature pubarche for most cases in girls, but in male development, the role of adrenal androgens is less clear.^[12]

In the most of the cases in boys, clinical presentation of premature pubarche is not a major clinical issue. Previous reports claim that pubarche should not necessarily present true puberty in a considerable number of boys older than 10 years of age with normal development.^[12] Indeed, it seems that in most cases, the presentation of isolated pubarche is to be the consequence of isolated adrenarche.^[13] On the other hand, premature adrenarche is associated with adrenal hyperandrogenism^[10] and elevation level of DHEAS, which is compatible with our case.

In addition, it has been reported that the prevalence of premature adrenarche is increased in central nervous system abnormalities.^[10] Fideleff *et al.*'s study reported a more frequent occurrence of neuro-ophthalmologic signs and higher incidence of macroadenoma in boys when compared with girls. Some causes could be recognized such as delayed onset of symptoms in males and difference in tumoral biology behavior between two sexes.^[14] Most clinical manifestations in males include delayed puberty, gynecomastia, and galactorrhea.^[10] On the contrary, the appearance of precocious puberty has been reported.^[15,16] Tütüncüler *et al.*^[8] introduced two cases of macroprolactinemia with increased hair growth or premature puberty. Whereas, we have a patient with premature pubarche. To our knowledge and based on an exhaustive literature search, we claim that this child is the first case of prolactinoma associated with premature pubarche. The atypical finding of premature pubarche development in our patient may be explained by the fact that low levels of prolactin could act as having a stimulatory effect and high levels having an inhibitory effect on male gonads.^[17] In addition, there is evidence that prolactin may have a stimulatory effect on Leydig-cell function and secretion of adrenal androgens, especially DHEA and DHEAS.^[18] Prolactin and insulin growth factor 1 have also been suggested to be stimulants in the secretion of cortisol.^[10] Specific prolactin receptors presence has been confirmed in the adrenal gland.^[19] In addition, the direct effect of prolactin on stimulation of adrenal androgen secretion was confirmed by a primary monolayer culture of bovine adrenal cells.^[20] The synergistic mechanism of prolactin-ACTH may be a limited inhibition of adrenal 3-beta-hydroxysteroid dehydrogenase, resulting in a noteworthy surge of DHEA-S and DHEA, but not of androstenedione.^[20]

With these considerations in mind, early pubertal changes do not necessarily mean precocious puberty. Based on our findings in this case, our suggestion is to include

prolactinoma in the differential diagnosis of premature pubarche.

Declaration of patient consent

The authors certify that they have obtained all appropriate patient consent forms. In the form the patient(s) has/have given his/her/their consent for his/her/their images and other clinical information to be reported in the journal. The patients understand that their names and initials will not be published and due efforts will be made to conceal their identity, but anonymity cannot be guaranteed.

Financial support and sponsorship

Nil.

Conflicts of interest

There are no conflicts of interest.

REFERENCES

- Hoffmann A, Adelman S, Lohle K, Claviez A, Müller HL. Pediatric prolactinoma: Initial presentation, treatment, and long-term prognosis. *Eur J Pediatr* 2018;177:125-32.
- Acharya SV, Gopal RA, Bandgar TR, Joshi SR, Menon PS, Shah NS. Clinical profile and long term follow up of children and adolescents with prolactinomas. *Pituitary* 2009;12:186-9.
- Müller HL. Childhood craniopharyngioma. *Pituitary* 2013;16:56-67.
- Fideleff HL, Boquete HR, Suárez MG, Azaretzky M. Prolactinoma in children and adolescents. *Horm Res* 2009;72:197-205.
- Guaraldi F, Storr HL, Ghizzoni L, Ghigo E, Savage MO. Paediatric pituitary adenomas: A decade of change. *Horm Res Paediatr* 2014;81:145-55.
- Iglesias P, Díez JJ. Macroprolactinoma: A diagnostic and therapeutic update. *QJM* 2013;106:495-504.
- Perry A, Graffeo CS, Marcellino C, Pollock BE, Wetjen NM, Meyer FB. Pediatric pituitary adenoma: Case series, review of the literature, and a skull base treatment paradigm. *J Neurol Surg B Skull Base* 2018;79:91-114.
- Tütüncüler F, Darendeliler F, Aygün M, Hekim N. Macroprolactinemia in childhood and adolescence: A cause of hyperprolactinemia. *Turk J Pediatr* 2006;48:143-7.
- Utriainen P, Laakso S, Liimatta J, Jääskeläinen J, Voutilainen R. Premature adrenarche—a common condition with variable presentation. *Horm Res Paediatr* 2015;83:221-31.
- Melmed S, Macp M, Koenig R, Rosen C, Auchus R, Goldfine A. *Williams Textbook of Endocrinology E-Book*. Elsevier Health Sciences: Elsevier; 2020.
- Rege J, Rainey WE. The steroid metabolome of adrenarche. *J Endocrinol* 2012;214:133-43.
- Rosenfield RL, Rich BH, Lucky AW. Adrenarche as a cause of benign pseudopuberty in boys. *J Pediatr* 1982;101:1005-9.
- Ibáñez L, Dimartino-Nardi J, Potau N, Saenger P. Premature adrenarche-normal variant or forerunner of adult disease? *Endocr Rev* 2000;21:671-96.
- Fideleff HL, Boquete HR, Sequera A, Suárez M, Sobrado P, Giaccio A. Peripubertal prolactinomas: Clinical presentation and long-term outcome with different therapeutic approaches. *J Pediatr Endocrinol Metab* 2000;13:261-7.
- Slonim AE, Glick AD, Island DP, Kasselberg AG. Hyperprolactinemia associated with advanced puberty in a male. *J Pediatr* 1982;101:236-9.

16. Ambrosi B, Bassetti M, Ferrario R, Medri G, Giannattasio G, Faglia G. Precocious puberty in a boy with a PRL-, LH- and FSH-secreting pituitary tumour: Hormonal and immunocytochemical studies. *Acta Endocrinol (Copenh)* 1990;122:569-76.
17. Ambrosi B, Travaglini P, Beck-Peccoz P, Bara R, Elli R, Paracchi A, *et al.* Effect of sulpiride-induced hyperprolactinemia on serum testosterone response to HCG in normal men. *J Clin Endocrinol Metab* 1976;43:700-3.
18. Lobo RA, Kletzky OA, Kaptein EM, Goebelsmann U. Prolactin modulation of dehydroepiandrosterone sulfate secretion. *Am J Obstet Gynecol* 1980;138:632-6.
19. Posner BI, Kelly PA, Shiu RP, Friesen HG. Studies of insulin, growth hormone and prolactin binding: Tissue distribution, species variation and characterization. *Endocrinology* 1974;95:521-31.
20. Higuchi K, Nawata H, Kato K, Ibayashi H. Ovine prolactin potentiates the action of adrenocorticotrophic hormone on the secretion of dehydroepiandrosterone sulfate and dehydroepiandrosterone from cultured bovine adrenal cells. *Horm Metab Res* 1985;17:451-3.