

Case Diagnosis**Dermatology case diagnosis**

*Amir Hossein Siadat\*, Neda Adibi\*, Mohhamad Ali NilfroushZadeh\*, Parvin Rajabi\*,  
Afshin Darougheh\*, Azadeh Zolfaghari Baghbaderani\*, Fariba Irajji\**

**Abstract**

A patient with multiple subcutaneous mobile lesions limited to forearms is presented. Pathologic review of the biopsy confirmed the diagnosis.

**KEY WORDS:** Subcutaneous lesion, sebaceous gland, cyst.

JRMS 2007; 12(4): 222-225

**A** twenty-six-year-old man was presented to the Skin Diseases and Leishmaniasis Research Center because of the multiple 2-3 mm subcutaneous lesions that were mobile and had yellowish distinct. The patient had these lesions for the past three years and his lesions had no symptoms. His family history was negative for any similar lesions. His only positive finding was hypertriglyceridemia. These lesions were limited to the forearms of the patient (figure 1), as there were no similar lesions on the other parts of the body. To confirm the diagnosis, a biopsy was performed.

**Diagnosis**

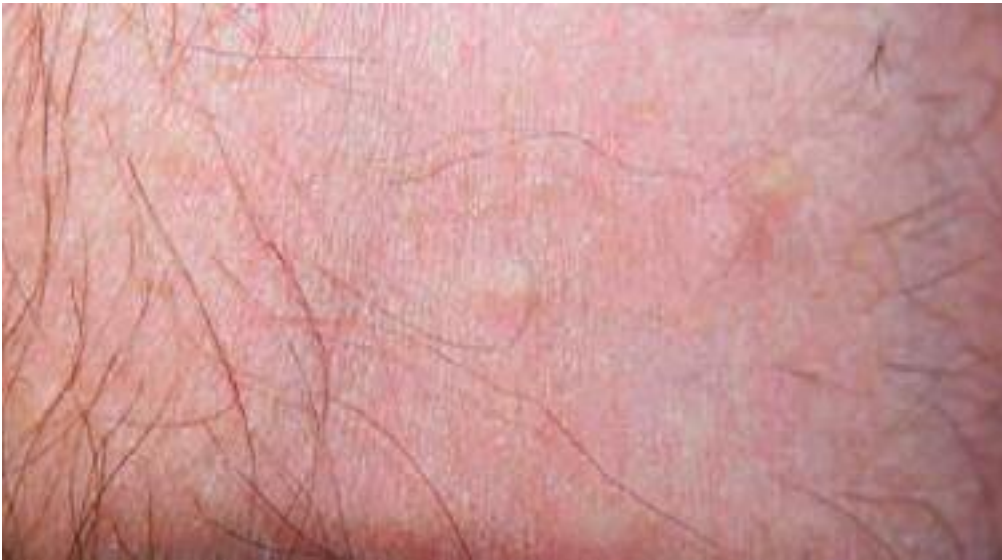In the pathology, a cystic cavity located in the mid-dermis was observed. The inner lining of this dermal cyst was undulating and composed of stratified squamous epithelium. A single sebaceous gland was present adjacent to the wall. This pathology confirmed the diagnosis of steatocystoma multiplex (figures 2 and 3).

**Discussion**

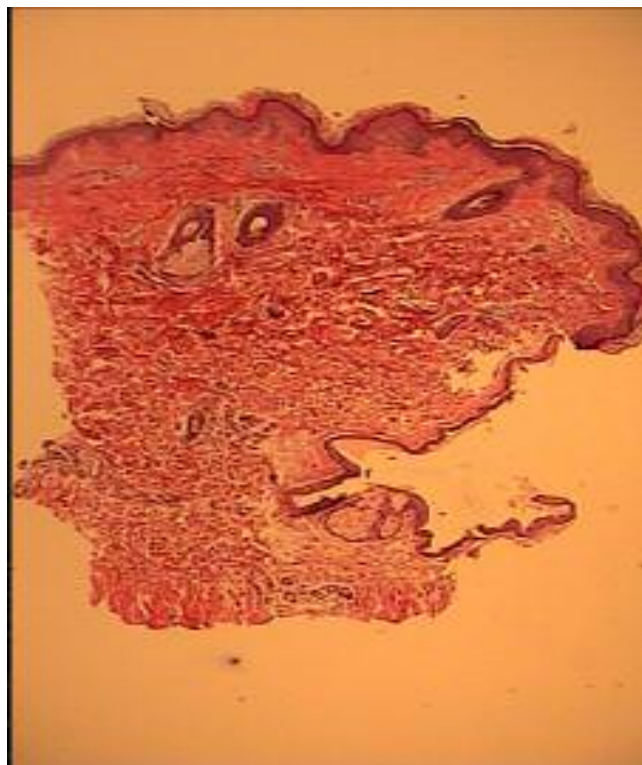
Steatocystoma multiplex is a disorder characterized by multiple, asymptomatic, dermal cysts that usually occur on the trunk and proximal extremities and less commonly on the neck, axillae, inguinal region, and scalp. Acral steatocystoma multiplex, in which involvement of the extremities is more prominent than that on the trunk, is uncommon and has been only recently described<sup>1</sup>. Onset of the disease tends to occur during adolescence or early adult life. This disorder has a predominantly autosomal dominant mode of inheritance, although many sporadic cases have been reported<sup>2</sup>. Regarding negative family history of these lesions, our patient represented a sporadic case of steatocystoma multiplex. In the pathology of the lesion, the cyst lining has a crenulated, or wavy, homogeneous, eosinophilic horny layer collapsed around thin cystic spaces. The spaces hold varying amounts of keratin, vellus hairs, and sebum esters, the latter of which are often removed by tissue

---

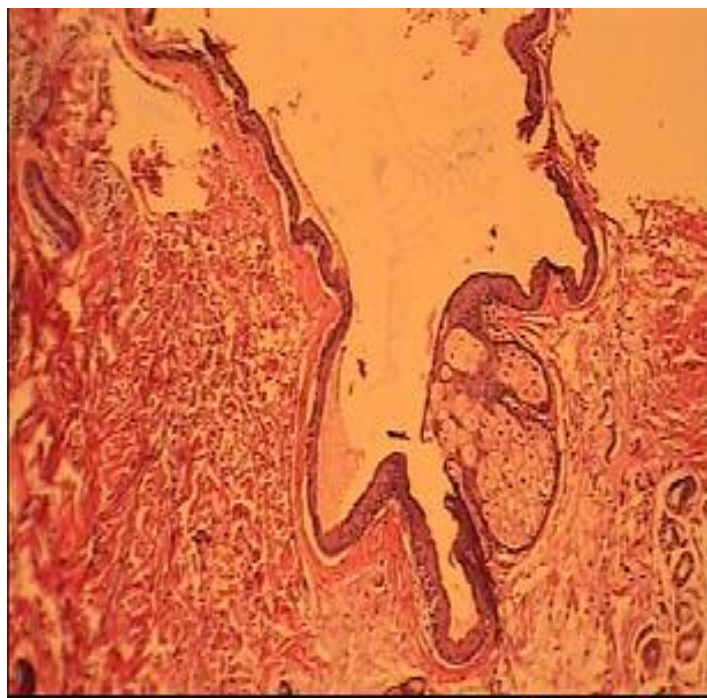
\*Skin Diseases and Leishmaniasis Research Center, Department of Dermatology, Isfahan University of Medical Sciences, Isfahan, Iran; and Center for Research and Training in Skin Diseases and Leprosy, Tehran University of Medical Sciences, Tehran, Iran. Correspondence to: Dr Amir Hossein Siadat, Skin Diseases and Leishmaniasis Research Center, Department of Dermatology, Isfahan University of Medical Sciences, Isfahan, Iran. e-mail: amirhossein1@yahoo.com



**Figure 1.** Multiple 2-3 mm subcutaneous lesions that were mobile and had yellowish distinct were observed on the forearm of the patient.



**Figure 2.** Steatocystoma multiplex (H & E, X 40). The inner lining of the dermal cyst is undulating and composed of stratified squamous epithelium. A single sebaceous gland is present adjacent to the wall.



**Figure 3.** Steatocystoma multiplex (H & E, X 100)

**Color versions of figures are available for download at the journal homepage**

processing. Walls are formed from several layers of epithelial cells with embedded, flattened lobules of sebaceous glands among the epithelial cells. Invaginations resembling hair follicles can also be found emptying into the cyst. Each cyst unit is attached to the overlying normal epidermis by a thin strand of undifferentiated epithelial cells. The differential diagnosis of these lesions is usually acne vulgaris, eruptive vellus hair cysts, follicular infundibulum tumor, Gardner's syndrome, milia, or syringoma<sup>3</sup>. Treatment usually is not required for this benign condition; however, treatment has been attempted with variable results. The patient may desire intervention for cosmetic reasons. Unfortunately, isotretinoin (despite known effects of decreasing sebaceous gland activity) has shown inconsistent results, according to the literature. In at least one patient, isotretinoin appeared to worsen the condition, which necessitated cessation of the drug. Individual cyst contents can be aspirated through an 18-gauge needle, but the effect is only tem-

porary. This technique is thought to be the treatment of choice for facial lesions because the scarring associated with excisional approaches will be avoided. Excision of all cysts on any one patient is not feasible because of the large numbers of cysts usually present; however, excision of some of the larger lesions can be performed using a small surgical punch or a sharp-tipped cautery point to puncture the cyst wall. The cyst's contents then can be expressed prior to everting the cyst lining with forceps to destroy it by either clip removal or electrodesiccation. The small punch site is allowed to heal by secondary intention. At least one published report exists of the successful treatment of steatocystoma multiplex using a carbon dioxide laser<sup>3</sup>. Association with elevated triglyceride may be coincidental or a real finding that must be further evaluated. Our patient rejected any surgical intervention for treatment of his lesions, and therefore was left untreated.

## References

1. Rollins T, Levin RM, Heymann WR. **Acral steatocystoma multiplex**. *J Am Acad Dermatol* 2000; 43(2 Pt 2):396-399.
2. Kaur T, Kanwar AJ. **Steatocystoma multiplex in four successive generations**. *J Dermatol* 2003; 30(7):559-561.
3. Bane M. **Steatocystoma multiplex**. *E-medicine of Dermatology*. [cited 2007, June]. Available from URL: <http://www.emedicine.com/derm/topic404.htm>.