

Diagnostic accuracy of gynecology imaging reporting and data system in evaluation of adnexal lesions

Fariba Behnamfar¹, Atoosa Adibi², Hiba Khadra², Maryam Moradi²

¹Department of Obstetrics and Gynecology, Medical School, Isfahan University of Medical Sciences, Isfahan, Iran, ²Department of Radiology, Medical School, Isfahan University of Medical Sciences, Isfahan, Iran

Background: Considering the increasing incidence rate of ovarian cancer in worldwide and the utility of Gynecologic Imaging Reporting and Data System (GI-RADS) in diagnosing malignant adnexal lesions such as ovarian cancer, we aimed to evaluate the diagnostic performance of this reporting system in differentiating between malignant and benign adnexal lesions. **Materials and Methods:** In this cross-sectional study, women with suspected adnexal lesions were enrolled. For differentiating of malignant adnexal lesions, Grade II and III of GI-RADS system were classified as low risk for malignancy and Grades IV and V as high risk. Results of histopathologic diagnosis were compared with the results of the mentioned GI-RADS system classification, and the diagnosed accuracy of the system was determined. Patients who did not have histopathologic diagnosis were followed up. **Results:** In this study, 197 women with suspected adnexal lesions were evaluated. Frequency of GI-RADS II, III, IV, and V were 34.5% (69 cases), 38.0% (76 cases), 19.5% (39 cases), and 6.5% (13 cases), respectively. According to the low- and high-risk classification of GI-RADS, 72.5% were classified as GI-RADS II and III and 26% as GI-RADS IV and V, respectively. Definitive histopathologic diagnosis was reported for 158 cases. Histopathologic evaluation indicated that 12 (7.6%) of the masses were malignant and 146 (92.6%) were benign. Comparing with the histopathologic diagnosis, the GI-RADS system sensitivity, specificity, positive predictive value, negative predictive value, positive likelihood ratio (LR), and negative LR were 91.6%, 80.82%, 28.2%, 99.1%, 4.77, and 0.10, respectively. The accuracy of the scoring system was 81.64%. **Conclusion:** Our findings indicated that using GI-RADS, we could quantify the risk of malignancy by such a structured as well as simple reporting system so that the system could be useful for clinicians for performing an appropriate clinical management.

Key words: Adnexal diseases, ovarian neoplasms, ultrasonography

How to cite this article: Behnamfar F, Adibi A, Khadra H, Moradi M. Diagnostic accuracy of gynecology imaging reporting and data system in evaluation of adnexal lesions. *J Res Med Sci* 2019;24:57.

INTRODUCTION

Adnexal lesions are one of the common gynecologic problems in females of all ages. The etiology of the lesions could be benign such as normal luteal cysts, tubo-ovarian abscess, polycystic ovaries, or malignant including ovarian carcinoma, metastasis, cyst adenocarcinoma and sarcoma.^[1] It is estimated that the lifetime risk of surgical evaluation of adnexal lesions for a woman is 5%–10%.^[2]

Considering that there is no noninvasive diagnostic tool for diagnosis of ovarian cancer, the most important

approach in the evaluation of adnexal lesions is excluding malignancy.^[3] Though the prevalence of ovarian cancer is not high and it consists 3% of all cancers in women, it is associated with higher rate of mortality.^[4]

Transvaginal and transabdominal ultrasonography are the primary radiologic tools for evaluation of the adnexal lesions. It is a safe and low-cost imaging method for differentiation of benign and malignant lesions with appropriate sensitivity and specificity rate (90%–93%).^[5,6]

Evidences indicated that the presence of some ultrasonographic features such as thick septations,

This is an open access journal, and articles are distributed under the terms of the Creative Commons Attribution-NonCommercial-ShareAlike 4.0 License, which allows others to remix, tweak, and build upon the work non-commercially, as long as appropriate credit is given and the new creations are licensed under the identical terms.

For reprints contact: reprints@medknow.com

Access this article online	
Quick Response Code: 	Website: www.jmsjournal.net
	DOI: 10.4103/jrms.JRMS_608_18

Address for correspondence: Dr. Maryam Moradi, Department of Radiology, Medical School, Isfahan University of Medical Sciences, Isfahan, Iran. E-mail: moradi@med.mui.ac.ir

Received: 04-10-2018; **Revised:** 03-01-2019; **Accepted:** 16-01-2019

solid component, nodularity, large lesions size (>6 cm), the presence of ascites, and bilateral lesions increase the susceptibility of malignancy.^[7-9] In addition, based on ultrasonographic findings of patients with adnexal lesions, different scoring systems or pattern recognition approaches such as simple descriptive scoring systems, logistic regression models, examiner's subjective impression, mathematically developed scoring systems, and Gynecologic Imaging Reporting and Data System (GI-RADS) have been proposed in several studies.^[10-14]

Although all of the mentioned systems have been used for characterizing adnexal lesions, there is still great variation in their utility, and the superiority of one of the above-mentioned approaches has not been determined yet.^[15] It is suggested that a structured ultrasonography reporting system would be more useful if it has appropriate clinical usefulness in a way that improves the radiologist and clinician communication.

GI-RADS is one of the reporting systems which has been developed recently, and its indication in clinical practice has also been reported in few studies.^[14,16,17]

Results of a recent epidemiologic study in Iran indicated an increasing trend of ovarian cancer incidence in this country, especially in northwestern and central parts of it, including Isfahan.^[18]

Thus, considering the increasing incidence rate of ovarian cancer in Iran and the advantage of GI-RADS in diagnosing malignant adnexal lesions including ovarian cancer, we aimed to evaluate the diagnostic performance of this reporting system differentiating malignant from benign adnexal lesions. Given that there were few studies, our results would be useful for providing more concise results in this field and better management of high-risk cases.

MATERIALS AND METHODS

In this cross-sectional study, women with suspected adnexal lesions referred for ultrasonographic evaluation, were enrolled. This study was conducted from March 2016 to February 2017 in Isfahan, Iran.

Protocol of the study was first reviewed by radiology review board members, and it was approved by regional ethics committee of Isfahan University of Medical sciences with a research project number of 395,138.

In this study, women with suspected adnexal lesions diagnosed by gynecologists from different private offices of Isfahan city and also from gynecologist clinics affiliated to

Isfahan University of Medical Sciences for ultrasonographic evaluation were included. Those who had not proper cooperation were excluded. Written informed consent was obtained from all participants.

Most of patients were evaluated with transvaginal ultrasound; others who were virgin or who did not give permission to perform transvaginal ultrasound were evaluated by transabdominal ultrasound (44 patients). Ultrasound was performed using a Voluson 730 Expert (GE Medical Systems, Zipf, Austria) and (DC-7 Mindray Medical Ltd., China) by multi-frequency probe. Ultrasonographic evaluation was performed by an expert radiologist who was expert in gynecological ultrasound (AA). The lesions were categorized based on the GI-RADS classification. Details of GI-RADS classification is described previously.^[14] In brief, the system has five categories for risk estimation of the probability of malignancy as follows;

GI-RADS I: Definitely benign (normal ovaries, no adnexal lesions) [Figure 1].

GI-RADS II: Very probably benign (adnexal lesions suggested to have functional origin). (No any septa, no wall thickness, no nodule, no vascularity, or any suspicious ultrasonographic feature should be detected.) [Figure 2].

GI-RADS III: probably benign (neoplastic adnexal lesions suggested to be benign); in this category, only one suspicious ultrasonographic feature is detected, as septa or wall thickness [Figure 3].

GI-RADS IV: Probably malignant (neoplastic adnexal lesions suggested to be malignant due to the presence of papillary projections, septations, solid areas, central vascularization, and ascites).

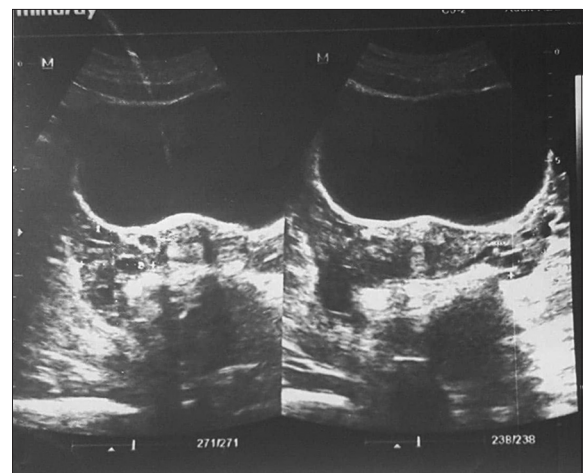


Figure 1: Gynecologic Imaging Reporting and Data System I. Normal ovaries with no lesion

In this category, two suspicious ultrasonographic features were noted [Figure 4].

GI-RADS 5: Very probably malignant (having 3 or more neoplastic adnexal lesions suggested to be malignant) (mentioned in GI-RADS III); more than two suspicious ultrasonographic features [Figure 5].

The patients were referred to us by gynecologist for ultrasonographic evaluation. From referred cases, those who had normal ovaries (GI-RADS I) were not included in our study. Those who did not accept for attending in our study and refused to be followed up or did not have histopathologic evaluation were excluded. Patients with GI-RADS II were recommended for periodic ultrasonographic evaluation. Those with GI-RADS III, IV, and V were referred to gynecologist for surgical management and further evaluations.

Patients who underwent surgical management and removal of the lesions, their histopathologic diagnosis was reviewed by their gynecologist and recorded by radiologist. The diagnostic performance of GI-RADS was investigated by comparing its classification with their definitive histopathologic diagnosis.

Those patients who did not have histopathologic evaluation were followed up by ultrasonography with a 6-week period interval till the lesion had resolved or its diameter was diminished. Those whose lesion had

no significant change in diameter were followed up for 18 weeks.

Statistical analysis

Obtained data were recorded and analyzed by SPSS software version 21 (SPSS Corp, Chicago, IL, USA). To determine the sensitivity, specificity, positive likelihood ratio (LR+), negative LR-, positive predictive value (PPV), and negative predictive value (NPV), of the GI-RADS system and for differentiating of malignant adnexal lesions, we classified Grade 2 and 3 of GI-RADS system as probably low risk for malignancy and Grades 4 and 5 as probably high risk. Results of histopathologic diagnosis (gold standard) as benign and malignant were compared with the results of the mentioned GI-RADS system classification, and the diagnosed accuracy of the system was determined using above-mentioned parameters. Chi-square test was used for comparing categorical variables. $P < 0.05$ was considered as statistically significant.

RESULTS

In this study, from initially enrolled 258 patients, 61 cases had refused to cooperate with us or follow up their adnexal lesions or had GI-RADS I grade in their. Finally, 197 cases with suspected adnexal lesions and GI-RADS II-V were enrolled. The mean (standard deviation) age of studied population was 37.51 (45.67) years.

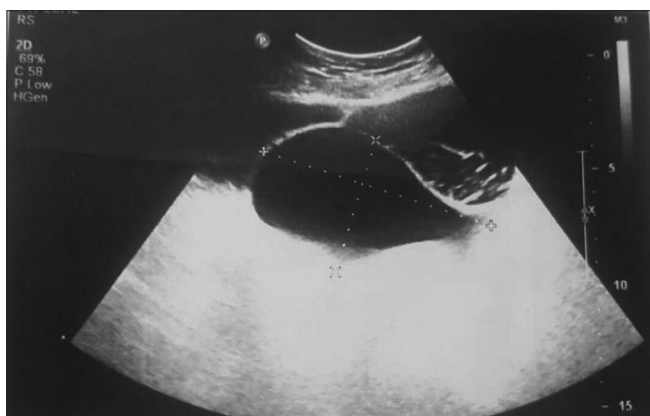

Figure 2: Gynecologic Imaging Reporting and Data System II. A simple cyst with thin wall and no septa or mural nodule

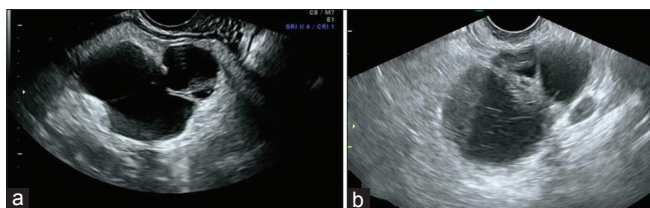


Figure 4: Gynecologic Imaging Reporting and Data System IV. (a) A cyst with thick septa and nodule. (b) A cyst with internal echo and very thick septa

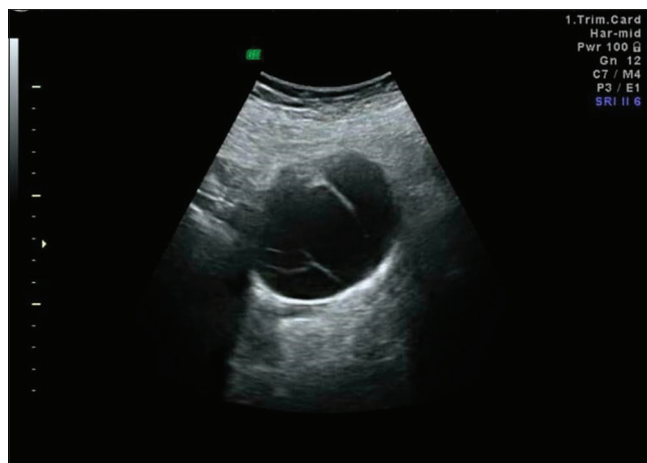


Figure 3: Gynecologic Imaging Reporting and Data System III. A cyst with some thin septa, without any nodule or vascularity. No vascularity was detected in Doppler study

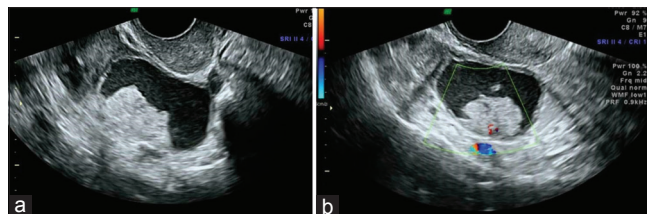


Figure 5: Gynecologic Imaging Reporting and Data System V. (a) A cyst with thick wall and a large irregular model inside it. (b) In Doppler study, clear vascularity was seen

Premenopausal women consist 81.4% of our population. Frequency of GI-RADS II, III, IV, and V were 34.5% (69 cases), 38.0% (76 cases), 19.5% (39 cases), and 6.5% (13 cases), respectively.

According to the low- and high-risk classification of GI-RADS, 72.5% (145 cases) and 26% (52 cases) classified as GI-RADS II and III and GI-RADS IV and V, respectively. Though GI-RADS II cases do not need any surgical operation and only needs to be followed up every 6 weeks due to their benign nature, some of our GI-RADS II patients (59 cases) were operated due to the decision of their gynecologist or surgeon because of their clinical situation. Their GI-RADS II cyst was surgically removed and evaluated by pathologist, and the benign nature was approved.

Of our 69 GI-RADS II cases, 59 cases were pathologically evaluated. Other 10 cases were followed up by ultrasound study every 6 weeks, till disappearing of the lesion or getting smaller.

A few cases of them had no variation in their size or nature of cyst (no mural nodule, no wall thickness, no vascularity, and no septa) even after follow-up at 6, 12 and 18 weeks; so, these cases were considered as benign lesions.^[1]

We have had 76 GI-RADS III cases, in which the gynecologist has to decide to follow them or to perform a surgical evaluation. Sixty of 76 cases were surgically operated; the other 16 cases were followed up and proved to be benign by periodic ultrasound examination.

Of surgically operated GI-RADS III lesions, only one lesion was malignant and proved to be carcinoma. It was a cyst containing internal echo and fine septa with peripheral vascularity, without any mural module.

We have given GI-RADS III for this lesion, but because of clinics of the patient, her gynecologist decided to operate her. This patient was high risk because he had a history of endometrioid carcinoma and had performed hysterectomy before. Hence, as a result, we have to take every lesion suspicious with low-risk GI-RADS in a patient with positive malignant history.

Patients with GI-RADS IV and V were advised to be evaluated by laparoscopy or open surgery by their gynecologist. Some of them were not operated due to their cardiac disease, diabetes, or other clinical conditions.

These patients were excluded from our statistical evaluation. One of our GI-RADS IV patients, who had a history of lymphoma, had died before surgery. She was excluded too. To have exact results, only patients with proved

pathological examination (158 patients) were included for evaluation of the system diagnostic accuracy.

We did not have exact pathology of all patients because some of pathological reports were reported as only positive or negative for malignancy. Furthermore, many of patients were not able to tell us the definite diagnosis except for malignant or benign. So, only pathologies with definite diagnosis (78 cases) were included in Table 1.

Definitive histopathologic diagnosis was reported for 158 cases. Histopathologic evaluation indicated that 12 (7.6%) of the lesions were malignant and 146 (92.6%) were benign. Distribution of malignant and benign lesions diagnosed by histopathologic examination in the four categorized GI-RADS groups is presented in Figure 6. One (1.7%), 6 (20%), and 5 (55.6%) of cases with GI-RADS III, IV, and V were malignant, respectively.

Final detailed histological diagnoses according to the low- and high-risk GI-RADS groups are presented in Table 1.

Distribution of true-positive, true-negative, false-positive, and false-negative cases based on histopathologic diagnoses in low- and high-risk GI-RADS groups are presented in

Table 1: Details of histological diagnosis according to the probably low- and high-risk Gynecologic Imaging Reporting and Data System groups

Pathology	GI-RADS groups		Total
	GI-RADS II and III (low risk)	GI-RADS IV and V (high risk)	
Benign			
Ectopic pregnancy	13	0	13
Hemorrhagic cyst	10	3	13
Endometrioma	10	2	12
Dermoid	8	0	8
Mucinous cystadenofibroma	1	1	2
Inclusion cyst	0	1	1
Serous cystadenoma	0	1	1
Other benign lesions	8	4	12
Borderline			
Borderline mucinous cystadenoma	0	1	1
Malignant			
Carcinoma	1	5	6
Mucinous cystadenocarcinoma	0	3	3
Granulosa cell tumor	0	2	2
Metastases	0	2	2
Sarcoma	0	1	1
Other malignant lesions	0	1	1
Total	51	27	78

GI-RADS=Gynecologic Imaging Reporting and Data System

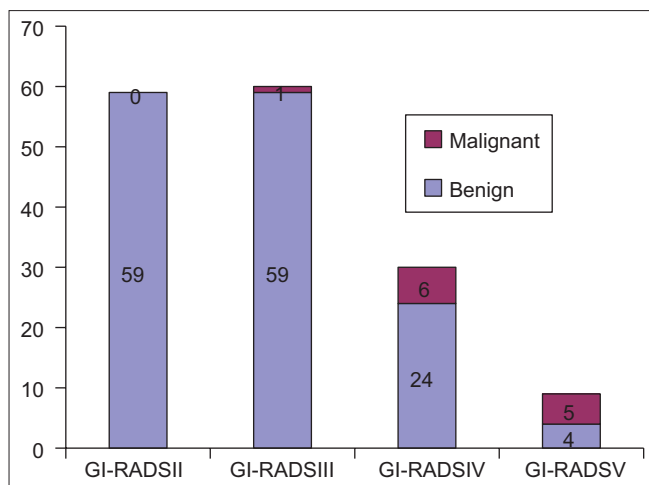


Figure 6: Distribution of malignant and benign lesions diagnosed by histopathologic examination in the four categorized Gynecologic Imaging Reporting and Data System groups

Table 2: Distribution of true-positive, true-negative, false-positive, and false-negative cases based on histopathologic diagnosis in low- and high-risk Gynecologic Imaging Reporting and Data System groups

Histopathologic diagnosis	GI-RADS classification		Total
	GI-RADS II and III Probably (low risk)	GI-RADS IV and V Probably (high risk)	
Benign	118	28	146
Malignant	1 (carcinoma)*	11	12
Total	119	39	158

*The patient had a history of endometrial cancer. GI-RADS=Gynecologic Imaging Reporting and Data System

Table 2. The results indicated that the number of true-positive, true-negative, false-positive, and false-negative cases were 11, 118, 28, and 1 cases, respectively.

The GI-RADS system sensitivity, specificity, PPV, NPV, (+) LR, and (-) LR were 91.6%, 80.82%, 28.2%, 99.1%, 4.77, and 0.10, respectively. The accuracy of the scoring system was 81.64%. Receiver operating characteristic (ROC) curve of the GI-RADS system for distinguishing malignant adnexal lesions in comparison with histopathology is presented in Figure 7. AUC of the ROC curve for malignant cases was 0.856.

DISCUSSION

In this study, we evaluated the diagnostic performance of GI-RADS, for diagnosing of malignant adnexal lesions. It is obvious that reading a radiology report is not as simple as we think even for doctors because it may have some definitions, that not all other physicians can analyze it true like mural module of a cyst, RI, central as peripheral vascularity,... etc.

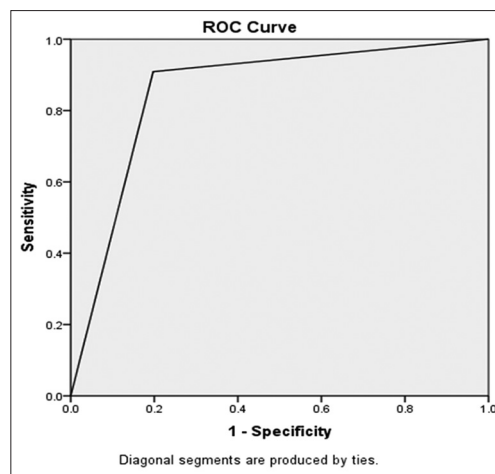


Figure 7: Receiver operating characteristic curve of the Gynecologic Imaging Reporting and Data System for distinguishing malignant adnexal lesions in comparison with histopathology

The GI-RADS system, of course, had facilitated report understanding for other physicians and so it helps in better decision-making for the patients. Our results indicated that this system has appropriate sensitivity and acceptable specificity for distinguishing malignant cases. Overall, it is suggested that GI-RADS could be used as a diagnostic tool in this regard.

Previous studies had emphasized on using a synoptic reporting tool for proper management of adnexal lesions. However, a nonstructured reporting system may result in unwarranted concern for both clinicians and patients.^[19,20] So, using of such reporting systems seems to be necessary. Though there are some appropriate reporting systems such as IOTA criteria which usefulness have been evaluated in some studies,^[21-23] such reporting systems in each center or region should be selected based on their facilities and priorities. In this study, we have evaluated the utility of recently developed so-called GI-RADS system in this field.

GI-RADS was first described by Amor *et al.* in 2009. They evaluated 187 cases with their proposed GI-RADS and compared with the final histopathologic diagnosis. The frequency of GI-RADS II, III, IV, and V were 27.8%, 48.1%, 7%, and 15%, respectively. Their reported sensitivity, specificity, PPV, NPV, and accuracy for GI-RADS were 92%, 97%, 85%, 99%, and 96%, respectively. They concluded that the system could be a good diagnostic tool which could improve the communication between clinicians and radiologists and consequently facilitate the process of decision-making. They recommended to plan prospective studies to obtain more conclusive results in this field.^[14]

Amor *et al.* conducted their second multicenter prospective study in 2008 for a 3-year period and evaluated the clinical utility of GI-RADS for evaluation of adnexal lesions. They

evaluated 432 adnexal lesions. They included lesions with GI-RADS II-V scores. The frequency of GI-RADS II, III, IV, and V were 21%, 43%, 9%, and 27%, respectively. Their reported sensitivity, specificity, PPV, NPV, and accuracy for GI-RADS were 99.1%, 85.9%, 71.1%, and 99.6%, respectively. LR+ and LR- were 7.05 and 0.01, respectively. Their findings confirmed the results of their previous studies.^[16]

In another recent study, Zhang *et al.* have evaluated the diagnostic performance of the GI-RADS in 242 cases with adnexal lesions, in a retrospective study. According to their results, sensitivity, specificity, and accuracy of the system were 96.4%, 84.3%, and 89.3%, respectively. Likewise, others, they also confirmed the usefulness of the system for the diagnosis of malignant lesions.^[17]

The findings of this study were in accordance with the mentioned studies with a sensitivity, specificity, and accuracy of 91.6%, 80.8%, and 81.64%, respectively. AUC of the ROC curve for malignant cases was 0.856. So, it seems that this scoring system which provides a comprehensive standardized report based on the ultrasonographic characteristics of the lesions could be used as an appropriate unified reporting system by sonographers for clinicians. This system would be more applicable for private settings or small health care centers where the sonographer and clinician were not in close communication, and the clinician should be made clinical decision based on radiologic report.

A recent meta-analysis indicated that the sensitivity and specificity of pelvic ultrasound for diagnosis of malignant adnexal lesions mainly ovarian cancer were 86%–91% and 68%–83%, respectively.^[24] Our findings using GI-RADS were in the upper limit of the mentioned values.

The limitations of our study were small sample size, the cross-sectional design of the study, and inclusion of cases which have pathologic evaluation. In addition, although the GI-RADS have appropriate sensitivity and specificity for diagnosis of malignant adnexal lesions, application of the system is more favorable when the ultrasonography is performed by an expert radiologist.

CONCLUSION

Our findings indicated that using GI-RADS, we could quantify the risk of malignancy by such a structured as well as simple reporting system so that the system could be useful for clinicians for performing an appropriate clinical management. However, given that the sensitivity of the system is higher than its specificity, it is recommended to design further studies with larger sample size for improving the system and adding biochemical

measurements such as CA125 and RI for reducing the rate of false-positive cases.

Financial support and sponsorship

Nil.

Conflicts of interest

There are no conflicts of interest.

REFERENCES

- Biggs WS, Marks ST. Diagnosis and management of adnexal masses. *Am Fam Physician* 2016;93:676-81.
- National institutes of health consensus development conference statement. Ovarian cancer: Screening, treatment, and follow-up. *Gynecol Oncol* 1994;55:54-14.
- Glanc P, Benacerraf B, Bourne T, Brown D, Coleman BG, Crum C, *et al.* First international consensus report on adnexal masses: Management recommendations. *J Ultrasound Med* 2017;36:849-63.
- U.S. Cancer Statistics Working Group. United States Cancer Statistics: 1999–2013 Incidence and Mortality Web-based Report. Atlanta: U.S. Department of Health and Human Services, Centers for Disease Control and Prevention and National Cancer Institute; 2016. Available from: <http://www.cdc.gov/uscs>. [Last accessed on 2017 Apr 25].
- Perera DS, Prabhakar HB. Imaging of the adnexal mass. *Clin Obstet Gynecol* 2015;58:28-46.
- Dodge JE, Covens AL, Lacchetti C, Elit LM, Le T, Devries-About M, *et al.* Preoperative identification of a suspicious adnexal mass: A systematic review and meta-analysis. *Gynecol Oncol* 2012;126:157-66.
- Smorgick N, Maymon R. Assessment of adnexal masses using ultrasound: A practical review. *Int J Womens Health* 2014;6:857-63.
- Brown DL. A practical approach to the ultrasound characterization of adnexal masses. *Ultrasound Q* 2007;23:87-105.
- Patel MD, Ascher SM, Paspulati RM, Shanbhogue AK, Siegelman ES, Stein MW, *et al.* Managing incidental findings on abdominal and pelvic CT and MRI, part I: White paper of the ACR incidental findings committee II on adnexal findings. *J Am Coll Radiol* 2013;10:675-81.
- Alcázar JL, Errasti T, Laparte C, Jurado M, López-García G. Assessment of a new logistic model in the preoperative evaluation of adnexal masses. *J Ultrasound Med* 2001;20:841-8.
- Timmerman D, Verrelst H, Bourne TH, De Moor B, Collins WP, Vergote I, *et al.* Artificial neural network models for the preoperative discrimination between malignant and benign adnexal masses. *Ultrasound Obstet Gynecol* 1999;13:17-25.
- Alcázar JL, Mercé LT, Laparte C, Jurado M, López-García G. A new scoring system to differentiate benign from malignant adnexal masses. *Am J Obstet Gynecol* 2003;188:685-92.
- Valentin L. Pattern recognition of pelvic masses by gray-scale ultrasound imaging: The contribution of Doppler ultrasound. *Ultrasound Obstet Gynecol* 1999;14:338-47.
- Amor F, Vaccaro H, Alcázar JL, León M, Craig JM, Martínez J. Gynecologic imaging reporting and data system: A new proposal for classifying adnexal masses on the basis of sonographic findings. *J Ultrasound Med* 2009;28:285-91.
- Levine D, Brown DL, Andreotti RF, Benacerraf B, Benson CB, Brewster WR, *et al.* Management of asymptomatic ovarian and other adnexal cysts imaged at US: Society of radiologists in ultrasound consensus conference statement. *Radiology* 2010;256:943-54.

16. Amor F, Alcázar JL, Vaccaro H, León M, Iturra A. GI-RADS reporting system for ultrasound evaluation of adnexal masses in clinical practice: A prospective multicenter study. *Ultrasound Obstet Gynecol* 2011;38:450-5.
17. Zhang T, Li F, Liu J, Zhang S. Diagnostic performance of the gynecology imaging reporting and data system for malignant adnexal masses. *Int J Gynaecol Obstet* 2017;137:325-31.
18. Moradi Y, Jafari M, Chaichian S, Khateri S, Akbarian A, Moazzami B, *et al.* Trends in ovarian cancer incidence in Iran. *Iran J Cancer Prev* 2016;9:e5452.
19. Brown DL, Dudiak KM, Laing FC. Adnexal masses: US characterization and reporting. *Radiology* 2010;254:342-54.
20. Le T, Fayadh RA, Menard C, Hicks-Boucher W, Faught W, Hopkins L, *et al.* Variations in ultrasound reporting on patients referred for investigation of ovarian masses. *J Obstet Gynaecol Can* 2008;30:902-6.
21. Timmerman D, Valentin L, Bourne TH, Collins WP, Verrelst H, Vergote I, *et al.* Terms, definitions and measurements to describe the sonographic features of adnexal tumors: A consensus opinion from the international ovarian tumor analysis (IOTA) group. *Ultrasound Obstet Gynecol* 2000;16:500-5.
22. Valentin L, Ameye L, Jurkovic D, Metzger U, Lécuru F, Van Huffel S, *et al.* Which extrauterine pelvic masses are difficult to correctly classify as benign or malignant on the basis of ultrasound findings and is there a way of making a correct diagnosis? *Ultrasound Obstet Gynecol* 2006;27:438-44.
23. Sokalska A, Timmerman D, Testa AC, Van Holsbeke C, Lissoni AA, Leone FP, *et al.* Diagnostic accuracy of transvaginal ultrasound examination for assigning a specific diagnosis to adnexal masses. *Ultrasound Obstet Gynecol* 2009;34:462-70.
24. Myers ER, Bastian LA, Havrilesky LJ, Kulasingam SL, Terplan MS, Cline KE, *et al.* Management of adnexal mass. *Evid Rep Technol Assess (Full Rep)* 2006;(130):1-145.