

# Prevalence of herpes simplex virus-1 in hospitalized adult patients with clinical diagnosis of meningoencephalitis using real-time polymerase chain reaction: A single-center, cross-sectional study

Kiana Shirani, Farzin Khorvash<sup>1</sup>, Alireza Emami Naeini<sup>2</sup>, Majid Valiyan Boroujeni<sup>1</sup>, Mohammadreza Yazdani<sup>1</sup>

Acquired Immunodeficiency Research Center, Isfahan University of Medical Sciences, Isfahan, Iran, <sup>1</sup>Nosocomial Infections Research Center, Isfahan University of Medical Sciences, Isfahan, Iran, <sup>2</sup>Infectious Diseases and Tropical Medicine Research Center, Isfahan University of Medical Sciences, Isfahan, Iran

**Background:** Early diagnosis of herpes simplex virus-1 (HSV-1) meningoencephalitis is very important because antiviral therapy significantly decreases mortality and morbidity. Polymerase chain reaction (PCR) is a reliable method with high sensitivity and specificity in detection of HSV-1. The aim of this study is to determine the prevalence of HSV-1 in patients with diagnosis of meningoencephalitis using real-time PCR. **Materials and Methods:** The cerebrospinal fluid samples were collected from 126 patients with clinical diagnosis of HSV-1 meningoencephalitis in Alzahra Referral Hospital in Isfahan, Iran. After deoxyribonucleic acid (DNA) extraction, real-time PCR was performed by fluorescence resonance energy transfer assay and participants underwent brain magnetic resonance imaging, as well. **Results:** Among 126 patients, 68.3% were male and 31.7% were female. The mean age of the participants was  $41.96 \pm 22.36$  years. Most of the participants were in the age group of 20–29 years. Three patients (2.4%) had positive and 123 patients (97.6%) had negative HSV-1 DNA test. Among three positive cases, two were in the age group of 20–29 years and one in the age group of  $\geq 80$  years. No HSV-2 DNA was detected. **Conclusion:** According to the estimated prevalence of HSV-1 meningoencephalitis in the current study, it seems that the prevalence of HSV-1 meningoencephalitis is not too high in our community; therefore, initial empiric acyclovir therapy is frequently overused.

**Key words:** Cerebrospinal fluid, herpes simplex virus, meningoencephalitis, polymerase chain reaction

**How to cite this article:** Shirani K, Khorvash F, Naeini AE, Valiyan Boroujeni M, Yazdani M. Prevalence of herpes simplex virus-1 in hospitalized adult patients with clinical diagnosis of meningoencephalitis using real-time polymerase chain reaction: A single-center, cross-sectional study. *J Res Med Sci* 2019;24:7.

## INTRODUCTION

There are two categories of central nervous system (CNS) infections, caused by herpes simplex virus-1 (HSV-1): acute meningoencephalitis in adults due to HSV-1 and meningitis and myelitis due to HSV-2.<sup>[1,2]</sup>

HSV-1 encephalitis is one of the most common forms of viral encephalitis.<sup>[3]</sup>

Clinical manifestations of CNS infections caused by HSV-1 virus range from aseptic meningitis to rapidly

progressive meningoencephalitis with alternation in consciousness.<sup>[1]</sup>

HSV-1 meningoencephalitis has a significant risk of mortality and morbidity in spite of advances in antiviral therapy. HSV-1 meningoencephalitis without treatment with antiviral medications leads to serious morbidities.<sup>[1,4]</sup>

In patients with classic symptoms of HSV-1 meningoencephalitis such as fever, headache, focal neurological signs, seizure, and/or deterioration of

### Access this article online

Quick Response Code:



Website:  
[www.jmsjournal.net](http://www.jmsjournal.net)

DOI:  
10.4103/jrms.JRMS\_370\_17

This is an open access journal, and articles are distributed under the terms of the Creative Commons Attribution-NonCommercial-ShareAlike 4.0 License, which allows others to remix, tweak, and build upon the work non-commercially, as long as appropriate credit is given and the new creations are licensed under the identical terms.

**For reprints contact:** [reprints@medknow.com](mailto:reprints@medknow.com)

**Address for correspondence:** Dr. Mohammadreza Yazdani, Nosocomial Infections Research Center, Isfahan University of Medical Sciences, Isfahan, Iran. E-mail: [yazdani@med.mui.ac.ir](mailto:yazdani@med.mui.ac.ir)

**Received:** 27-08-2017; **Revised:** 07-03-2018; **Accepted:** 22-10-2018

consciousness, early and rapid diagnosis is easier; however, clinical diagnosis is not reliable as several neurologic syndromes may mimic HSV-1 meningoencephalitis.<sup>[5,6]</sup>

Early diagnosis of HSV-1 meningoencephalitis is very important because antiviral therapy with acyclovir significantly decreases mortality and neurologic sequels.<sup>[3]</sup>

Cerebrospinal fluid (CSF) cultures and Gram stain of CSF smear are negative in viral meningoencephalitis and cannot be used as a reliable diagnostic method.<sup>[2,7]</sup>

Polymerase chain reaction (PCR) techniques for amplifying the genome of HSV-1 from CSF are the diagnostic procedure of choice for HSV-1 meningoencephalitis which can detect any viral deoxyribonucleic acid (DNA) in CSF even in the 1<sup>st</sup> day of infection.<sup>[3,8,9]</sup> PCR is a reliable method with high sensitivity and specificity in the detection of HSV-1 DNA.<sup>[9]</sup>

According to our experience, most of the patients referred to our center with signs of meningoencephalitis and do not truly have HSV-1 meningoencephalitis, and in many circumstances, intravenous acyclovir, which is the recommended treatment for HSV-1 meningoencephalitis, is overused. The aim of the current study is to determine the prevalence of HSV-1 in hospitalized patients with the diagnosis of meningoencephalitis using real-time PCR method in Isfahan.

## MATERIALS AND METHODS

A descriptive cross-sectional study was performed during 2013–2014 on 126 CSF specimens from 126 patients (86 males and 40 females) with the clinical diagnosis of HSV-1 meningoencephalitis and lymphocytic pleocytosis. We conducted this study using convenience sampling based on inclusion and exclusion criteria (see later). All included patients were from Alzahra Referral Hospital affiliated to Isfahan University of Medical Sciences, Isfahan, Iran.

The Ethical Committee of Isfahan University of Medical Sciences approved this study and informed written consent form was obtained from the participants or their guardians.

Clinical evidences of meningoencephalitis included fever and one or more of the followings: disorientation, personality change, focal or generalized seizure, memory disturbance, and focal neurologic signs.

All the patients underwent brain magnetic resonance imaging (MRI). Patients with brain abscess, brain mass, subdural or epidural empyema, noninfectious neurologic diseases, human immunodeficiency virus infection, head trauma, sepsis due to infection of the other organs, as well as children, patients with a definite clinical diagnosis of bacterial

meningitis without evidence of encephalitis, and patients who underwent neurosurgery were excluded from the study.

Patients were symptomatic from several days to 1 week before admission. CSF samples were obtained within 6 h of admission. Patients received no or maximum one dose of acyclovir therapy before lumbar puncture.

About 2–3 ml of CSF was analyzed for cell count with differentiation, protein, and glucose, 2–3 ml of CSF was assessed for Gram stain smear and culture, and about 5 ml of CSF was restored for more evaluation if needed. Concomitantly, blood sugar was also checked. In the circumstances with negative Gram stain smear and CSF analysis compatible with viral meningoencephalitis (raised CSF white blood cells with lymphocyte predominance, normal protein, normal or near-normal CSF glucose-to-serum glucose ratio, with or without red blood cells in the CSF) or when CSF analysis was not suggestive of bacterial meningitis, the restored CSF specimen was sent to laboratory for HSV-1 DNA PCR testing.

DNA was extracted from 200  $\mu$ L of CSF using High Pure Viral Nucleic Acid Kit (Roche, Germany) according to extraction protocol indicated by the manufacturer. Then, real-time PCR was performed using Rotor-Gene 6000 instrument, Germany. Sequence differences between HSV-1 and HSV-2 were detected by melting curve analysis and determined by fluorescence resonance energy transfer assay. Melting curve analysis was performed following PCR amplification. The temperature in the thermal chamber was started at 54°C and slowly raised to 95°C, and the fluorescence was measured at frequent intervals. Sequence differences between the PCR product and hybridization probes resulted in shifts in the melting temperatures (66.7°C for HSV-1 and 74.7°C for HSV-2) which were detected. Analysis of the PCR amplification and probe melting curves was performed through the instrument software. References for primers and probes were executive instruction shown as a patent by manufacturer of the instrument. Positive and negative kit controls were offered by the manufacturer.

Quantitative and qualitative data were presented as mean  $\pm$  standard deviation and frequency (percentage). Comparisons between groups were done using independent *t*-test and Chi-square test for quantitative and categorical data, respectively. For statistical analyses, the statistical software SPSS version 15.0 for Windows (SPSS Inc., Chicago, IL, USA) was used.

## RESULTS

A total of 126 eligible patients with meningoencephalitis were enrolled in this study. Eighty-six patients (68.3%)

were male and 40 patients (31.7%) were female. The mean age of the participants was  $41.96 \pm 22.36$  years. Most of the participants were in the age group of 20–29 years.

Frequency distribution of age groups is shown in Figure 1.

Three patients (2.4%), 95% confidence interval: 0–0.051, had positive and 123 participants (97.6%) had negative HSV-1 DNA test. All the three patients with positive HSV-1 DNA test were male, but no significant difference was reported between gender and positive PCR results ( $P = 0.55$ ).

The mean age of the patients with positive HSV-1 DNA test was  $42.67 \pm 34$  years and those with negative tests was  $41.94 \pm 22$  years without any significant difference ( $P = 0.96$ ). Among three patients with positive HSV-1 DNA test, two were in the age group of 20–29 years and one in the age group of  $\geq 80$  years [Figure 2]. All three positive cases were male.

All the patients had normal brain MRI. No HSV-2 DNA was detected.

## DISCUSSION

Previous studies have reported that clinical manifestations and imaging findings are not always sufficient for definite diagnosis of HSV-1 meningoencephalitis<sup>[9-11]</sup> which our study suggested the same.

Unlike Behzad-Behbahani *et al.* study which showed a significant association between positive HSV-1 PCR results and brain MRI findings ( $P = 0.02$ ),<sup>[11]</sup> we did not find any correlation between HSV-1 positive tests and brain MRI with typical frontotemporal lesions.

A few studies reported a correlation between initial HSV-1 DNA load and the patients' outcome in HSV-1

meningoencephalitis.<sup>[9]</sup> Ziyaeyan *et al.* study showed some association between initial viral load of HSV-1 in patients with meningoencephalitis, number of subsequent positive HSV-1 PCR results, and duration of treatment with acyclovir.<sup>[9]</sup> They reported that lower initial viral load significantly decreases the duration of acyclovir therapy ( $P = 0.014$ ).<sup>[9]</sup> We did not evaluate such relationship in our study.

Similar to the current study, Ziyaeyan *et al.* did not find any correlation between age and positive PCR tests too ( $P > 0.05$ ).<sup>[9]</sup> Both Ziyaeyan *et al.* and Behzad-Behbahani *et al.*<sup>[1,9]</sup> found no significant correlation between gender and positive PCR tests which are the same as ours.

It is mentioned that HSV-1 encephalitis has no gender predilection but occurs mostly in patients older than 50 and younger than 20 years rather than other ages.<sup>[12]</sup> In our study, one case had been older than 80, but two cases were 20–29 years old; however, we did not assess children and most of the cases had been between 20 and 29 years old.

Frequency of HSV-1 meningoencephalitis in our study was estimated to be 2.4% compared with 9.3% in the study of Ziyaeyan *et al.*<sup>[9]</sup> This prominent difference between these two studies may be due to the difference in sample size (126 vs. 236), environmental and genetic differences, and total prevalence of HSV-1 in different communities, although both the studies used the same method of PCR (real time).

## CONCLUSION

According to the estimated prevalence of HSV-1 meningoencephalitis in the current study (using real-time PCR), it seems that the prevalence of HSV-1 meningoencephalitis is not too high in our community, and therefore, initial empiric acyclovir therapy is frequently overused.

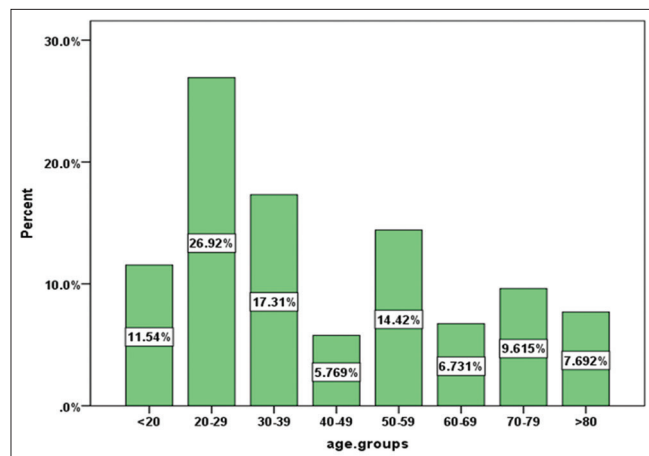


Figure 1: Frequency of age groups in studied participants

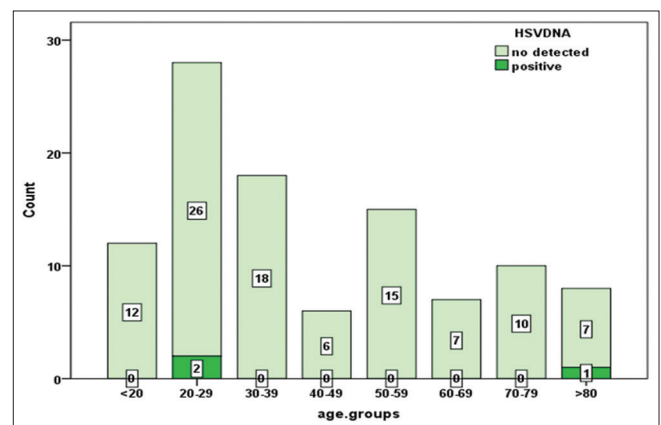


Figure 2: Frequency of herpes simplex virus deoxyribonucleic acid in age groups

About limitations, because our study was conducted on samples collected from a referral hospital, the generalizability of obtained results should be interpreted with caution. Accordingly, for more precise results, further studies with larger sample size from different medical centers along with random sampling are suggested using not only CSF analysis, CSF HSV-1 DNA testing, and brain MRI but also electroencephalogram and even another 3–7 days later CSF HSV-1 DNA PCR testing if negative at first.

#### Acknowledgments

We gratefully acknowledge Isfahan University of Medical Sciences because of funding support.

#### Financial support and sponsorship

Nil.

#### Conflicts of interest

There are no conflicts of interest.

#### REFERENCES

- Behzad-Behbahani A, Abdolvahab A, Gholamali YP, Roshanak B, Mahmood R. Clinical signs as a guide for performing HSV-PCR in correct diagnosis of herpes simplex virus encephalitis. *Neurol India* 2003;51:341-4.
- Shoji H, Koga M, Kusuhara T, Kaji M, Ayabe M, Hino H, *et al.* Differentiation of herpes simplex virus 1 and 2 in cerebrospinal fluid of patients with HSV encephalitis and meningitis by stringent hybridization of PCR-amplified DNAs. *J Neurol* 1994;241:526-30.
- Tyler KL. Update on herpes simplex encephalitis. *Rev Neurol Dis* 2004;1:169-78.
- Tafreshi NK, Sadeghizadeh M, Amini-Bavil-Olyae S, Ahadi AM, Jahanzad I, Roostaei MH, *et al.* Development of a multiplex nested consensus PCR for detection and identification of major human herpesviruses in CNS infections. *J Clin Virol* 2005;32:318-24.
- Jeffery KJ, Read SJ, Peto TE, Mayon-White RT, Bangham CR. Diagnosis of viral infections of the central nervous system: Clinical interpretation of PCR results. *Lancet* 1997;349:313-7.
- Whitley RJ, Kimberlin DW. Viral encephalitis. *Pediatr Rev* 1999;20:192-8.
- Alarcón F, Moreira J, Rivera J, Salinas R, Dueñas G, Van den Ende J, *et al.* Tuberculous meningitis: Do modern diagnostic tools offer better prognosis prediction? *Indian J Tuberc* 2013;60:5-14.
- Sauerbrei A, Eichhorn U, Hottenrott G, Wutzler P. Virological diagnosis of herpes simplex encephalitis. *J Clin Virol* 2000;17:31-6.
- Ziyaeyan M, Alborzi A, Borhani Haghighi A, Jamalidoust M, Moeini M, Pourabbas B, *et al.* Diagnosis and quantitative detection of HSV DNA in samples from patients with suspected herpes simplex encephalitis. *Braz J Infect Dis* 2011;15:211-4.
- Domingues RB, Fink MC, Tsanaclis AM, de Castro CC, Cerri GG, Mayo MS, *et al.* Diagnosis of herpes simplex encephalitis by magnetic resonance imaging and polymerase chain reaction assay of cerebrospinal fluid. *J Neurol Sci* 1998;157:148-53.
- Domingues RB, Lakeman FD, Mayo MS, Whitley RJ. Application of competitive PCR to cerebrospinal fluid samples from patients with herpes simplex encephalitis. *J Clin Microbiol* 1998;36:2229-34.
- Heitman J. Mandell, Douglas, and Bennett's principles and practice of infectious diseases. *Mycopathologia* 2000;149:47-8.

