

Serum procollagen type 1 N propeptide: A novel diagnostic test for diabetic foot osteomyelitis – A case–control study

Oliver G Hayes, Venkat N Vangaveti, Usman H Malabu

Translational Research in Endocrinology and Diabetes (TREAD), College of Medicine and Dentistry, James Cook University, Douglas QLD 4814, Australia

Background: The objective of the study was to determine whether serum levels of procollagen type 1 N propeptide (P1NP), a bone formation turnover marker, differs between diabetic foot ulcer with osteomyelitis (DFO) and diabetic foot ulcers without osteomyelitis serving as controls. It was also aimed to assess the usefulness of P1NP in diagnosing DFO compared to other common inflammatory markers. **Materials and Methods:** A case–control study was designed comparing the aforementioned groups. Patients were classified as osteomyelitis and controls based on the International Working Group diagnostic criteria. Serum P1NP and three other inflammatory markers, namely, C-reactive protein (CRP), white blood cells (WBC), and platelets were analyzed on patients with DFO and controls. **Results:** The mean serum P1NP levels were significantly higher in the DFO group ($n: 16$), 10.5 ± 5.2 (ng/ml), than the control group ($n: 11$) 3.1 ± 2.8 (ng/ml), $P = 0.001$. P1NP showed the highest sensitivity/specificity 86.7%/80% compared to 70.6%/80%, 56.2%/45.4%, and 50%/37% for CRP, WBC and platelets, respectively. Receiver operator characteristic curves showed the best value of area under the curve of 0.9 for P1NP compared to 0.85, 0.54, and 0.46 for CRP, WBC, and platelets. **Conclusion:** We found marked elevation of serum P1NP in diabetic foot ulcer with bone infection with potential value in using it to diagnose DFO.

Key words: Bone turnover markers, diabetic foot ulcer, diagnosis, osteomyelitis

How to cite this article: Hayes OG, Vangaveti VN, Malabu UH. Serum procollagen type 1 N propeptide: A novel diagnostic test for diabetic foot osteomyelitis – A case–control study. *J Res Med Sci* 2018;23:39.

INTRODUCTION

Diabetic foot bone infection (osteomyelitis) is a leading cause of hospitalization and lower limb amputation worldwide costing >\$40,000 per event.^[1,2] Early diagnosis of osteomyelitis may improve the success of medical therapy and thus reduce the need for lower limb amputation; however, confirmatory tests such as biopsy are invasive, accurate diagnostic tests (e.g., magnetic resonance imaging – [MRI]) are costly and not readily available in most centers outside major cities. Use of plain radiographs in detecting osteomyelitis is inexpensive but has low sensitivity.^[3,4] On the other hand, radioisotope scans are more sensitive than X-rays but are expensive and can be time-consuming.^[5,6] We have previously reported the use of an inflammatory

marker-erythrocyte sedimentation rate (ESR) in diagnosing diabetic foot osteomyelitis (DFO),^[7] but its elevation in other inflammatory and neoplastic conditions limits its widespread use. Bone-specific inflammatory markers have been reported in animal studies and recently in humans to be a possible diagnostic marker for DFO.^[8-13] Thus, use of bone turnover markers (BTMs) appears appealing in diagnosing bone infection as the diabetic foot ulcer acts as a portal of entry for microbial invasion into bone. Importantly, osteomyelitis is recognized as a state of both enhanced bone resorption and formation.^[14] During bone resorption and formation, specific BTMs are released. Procollagen type 1 N propeptide (P1NP) is formed during the processing of pro-collagen into collagen, through the cleavage of the pro-collagen

Access this article online

Quick Response Code:



Website:
www.jmsjournal.net

DOI:
10.4103/jrms.JRMS_810_16

This is an open access journal, and articles are distributed under the terms of the Creative Commons Attribution-NonCommercial-ShareAlike 4.0 License, which allows others to remix, tweak, and build upon the work non-commercially, as long as appropriate credit is given and the new creations are licensed under the identical terms.

For reprints contact: reprints@medknow.com

Address for correspondence: Assoc.Prof. Usman H Malabu, College of Medicine and Dentistry, James Cook University and Townsville Hospital, 100 Angus Smith Drive, Douglas QLD 4814, Australia. E-mail: usman.malabu@jcu.edu.au

Received: 09-11-2016; **Revised:** 25-11-2017; **Accepted:** 10-02-2018

protein N-terminal. Principally, P1NP is formed in the bone and is likely to be elevated in response to bone pathologies including bone infections.^[14] A significant benefit of P1NP compared to other particular BTMs is that it exhibits only a small circadian rhythm variation.^[15] Furthermore, P1NP assays are commercially available and are frequently used in monitoring bone diseases in clinical practice, yet its usefulness in assessing DFO is not known. In spite of these, no study has been conducted to assess the usefulness of P1NP in differentiating DFO from soft-tissue inflammations. The aims of this study were to determine the utility of serum P1NP in diagnosing DFO and to compare its diagnostic value with other common inflammatory markers.

MATERIALS AND METHODS

Study design and participants

The study project number HREC/13/QTHS/65 was approved by the local hospital's Human Research Ethics Committee and informed consent was obtained from all participants. Data were collected from July 1, 2014 to April 1, 2015 at the Townsville Hospital, Queensland, Australia. A power set to 80% yielded a calculated minimum sample size of 24 with a two-sided confidence interval of 95%. Overall, a total of 27 patients with DFO and controls were studied. Patients with a diabetic foot ulcer with and without osteomyelitis, and aged >18 were included in the study. Participants were excluded if they had osteoporosis based on bone mineral density scores or any recent bone fracture, active Charcot's joint, bone metastases, and/or primary bone cancer or a known metabolic bone disease. Other exclusion criteria included Stage 4 and 5 chronic kidney disease, osteomyelitis unrelated to a diabetic foot ulcer, and use of local or systemic corticosteroid, thiazolidinedione, or bone antiresorptive medications.

Procedures and assessment study variables

Foot wound or ulcer was defined as a full-thickness lesion involving any portion of the foot or ankle.^[16,17] Wounds characterized as blisters, minor lacerations, or abrasions were excluded from the study. Wound infection was defined clinically, by criteria consistent with the International Working Group guidelines,^[18] that is, the presence of wound purulence or at least two signs or symptoms of local inflammation or systemic symptoms of infection with no other apparent cause. All wounds were evaluated to determine the extent of soft-tissue infection and for any evidence of osteomyelitis.^[19] For this study, osteomyelitis cases were defined by intraoperative bone sample showing histologic findings of osteomyelitis and/or presence of probe-able bone underlying an ulcer supported by imaging evidence (plain radiograph, MRI, or radionuclide scanning) of osteomyelitis in line with standard guidelines.^[18,20] Patients were allocated to the case group if they had findings consistent with osteomyelitis and

control group was defined as patients who met inclusion criteria however did not meet the diagnostic criteria for osteomyelitis (i.e., having soft-tissue infection alone). On entry, detailed history and clinical examination were conducted and a protocol was completed. These included age, sex, diabetes control, site and depth of ulcer, and presence of associated diabetic complications including peripheral vascular disease, ischemic heart disease, peripheral neuropathy (i.e., paresthesia and numbness) and autonomic neuropathy (i.e., postural dizziness, impotence, episodic watery diarrhea and abnormal sweating). Morning fasting venous blood samples were taken, which were centrifuged at 3000 g for 5 min, followed by -80°C storage. Serum P1NP concentration was determined with the My BioSource (San Diego, California, USA) enzyme-linked immunosorbent assay kit. The P1NP kit has a sensitivity of 1.0 ng/ml, recovery average of 99%, intra-assay reproducibility of <15% and inter-assay reproducibility of <15%. Absorption spectroscopy at a wavelength of 450 nm, in correlation with a line of best fit from standard solutions, was used to determine the concentration of P1NP. The assay was blinded to the investigators.

Statistical analysis

Statistical analysis was performed using Statistical Package for the Social Sciences version 23 (IBM, Armonk, NY, USA: IBM Corp). Categorical variables were presented as percentages and continuous variables as mean \pm standard deviation. Student's *t*-test was used to compare the means between the two groups. Association between categorical variable was determined using the Chi-squared test/Fisher's exact test. Receiver operating characteristic (ROC) curve and area under the curve (AUC) with cutoff point with highest prognostic value presented based on Youden's index were used to determine the diagnostic levels. A $P < 0.05$ was predetermined as the cutoff value for statistical significance.

RESULTS

A total of 27 participants were studied 16 DFO and 11 controls. The demographic and clinical characteristics of the study population were shown in Table 1. The mean age was 66 ± 6.9 and 67 ± 7.2 years for DFO and controls, respectively, $P = 0.83$. There were no significant differences between the 2 groups in all other baseline clinical parameters including diabetes, its complications, cardiovascular disease and nondiabetic comorbidities. The past history of nontraumatic lower-limb amputations were similar in both groups 58.8% vs. 36.4%; $P = 0.25$.

The mean serum P1NP levels were significantly higher in the DFO group ($n: 16$), 10.5 ± 5.2 (ng/ml), compared to lower values in the control group ($n: 11$) 3.1 ± 2.8 (ng/ml), $P = 0.001$ as shown in Figure 1. Of all the parameters tested, P1NP showed

the highest combination of sensitivity/specificity 86.7%/80% compared to 70.6%/80%, 56.2%/45.4%, and 50%/37% for C-reactive protein (CRP), white blood cells (WBCs), and platelets, respectively. Furthermore, the positive and negative predictive values of P1NP for the diagnosis of DFO were similarly higher 86.7% and 80.0%, respectively, with the positive diagnostic test cutoff of ≥ 4.42 (ng/ml) as shown in Table 2. Receiver operator characteristic curves showed the best value of AUC of 0.9 for P1NP compared to 0.85, 0.54, and 0.46 for CRP, WBC, and platelets. Conversely, based on the ROC's AUC, the diagnostic performances of CRP, WBC, and platelet counts were lower than that of P1NP, ranging from 0.5 to 0.8 as shown in Figure 2.

DISCUSSION

We have demonstrated markedly elevated serum levels of P1NP in patients with DFO. Indeed P1NP, a bone formation

marker offers an excellent discrimination in the diagnosis of DFO from soft-tissue infection. Of the 4 diagnostic markers tested, it showed the best overall diagnostic efficiency. In addition, it showed highest combination of results for the predictive value of a positive test (the proportion of patients with positive tests who had osteomyelitis) and better predictive value of a negative test (the proportion of patients with negative tests who did not have osteomyelitis). Furthermore, the sensitivity and specificity of the P1NP in differentiating osteomyelitis from soft-tissue infection were superior to the other diagnostic parameters. It is interesting to note that until recently,^[8] the only previous study of any BTM in DFO showed a nonsignificant elevation of serum bone-specific alkaline phosphatase and n-terminal telopeptide levels in DFO.^[9] The differing outcomes between earlier reports and the current study are potentially due to different BTMs being examined and the recent improvement in preanalytical and analytical BTM assays.^[21,22] Conversely, bone formation turnover makers – bone-specific alkaline phosphatase and osteocalcin – have been investigated in two small animal trials showing elevated levels in osteomyelitis.^[10,13] To the best of our knowledge, no studies concerning diagnostic value of P1NP in other forms of osteomyelitis, both human and animal have been reported.

The current diagnostic methods for DFO have significant limitations, with the majority only being available in tertiary health-care centers. The evidence regarding diagnostic modalities in DFO has recently been reviewed with combined diagnostic sensitivities and specificities calculated.^[20,21] Plain radiography has a diagnostic sensitivity of 54% and a specificity of 68%. Thus, it has poor diagnostic utility, especially at ruling out a diagnosis of osteomyelitis. A technetium-99m bone scan has a sensitivity of 81% and a specificity of 28%; thus are clinically useful to exclude DFO; however, less so for a positive diagnosis. An indium-111 leukocyte scan has a sensitivity of 74% and

Table 1: Characteristics of the study population

Parameter	Osteomyelitis (n=16) (%)	Control (n=11) (%)	P
Age (years)	66±6.9	67±7.2	0.83
Male	88.2	66.7	0.14
Current nonsmokers	94.1	100.0	0.44
Current alcohol use	23.5	20.0	0.83
Type 1 diabetes mellitus	22.2	0.0	0.08
Type 2 diabetes mellitus	77.8	100	0.08
Insulin use	83.2	63.6	0.24
Hemoglobin A1c	8.8	7.9	0.9
Retinopathy	77.8	54.5	0.20
Peripheral neuropathy	100	100	1
Hypertension	88.2	100	0.31
Coronary artery disease	54.5	29.4	0.19
Cerebrovascular accident	0.0	18.2	0.07
Amputation (nontraumatic)	58.8	36.4	0.25
Peripheral vascular disease	56.3	27.3	0.15

Table 2: Comparison of bone turnover markers and biochemical/hematological indices showing higher value for bone turnover marker procollagen type 1 N propeptide in diagnosing diabetic foot osteomyelitis

Diagnostic value	P1NP (%)	CRP (%)	WBC (%)	Platelet count (%)
Sensitivity	86.7	70.6	56.2	50.0
Specificity	80.0	80.0	45.4	37
PPV	86.7	90.1	69.2	53.3
NPV	80.0	44.4	50.0	33.3
Best cutoff point	≥ 4.42 ng/ml	≥ 68.5 mg/L	$\geq 7.25 \times 10^9$ /L	$\geq 245 \times 10^9$ /L
AUC	0.90	0.85	0.54	0.46
P	<0.001	<0.05	0.70	0.70
95% CI	0.78-1.0	0.6-1.0	0.31-0.76	0.23-0.68

BTM=Bone turnover marker; P1NP=Procollagen type 1 N propeptide; CRP=C-reactive protein; WBC=White blood cells; CI=Confidence interval; AUC=Area under the curve; PPV=Positive predictive value; NPV=Negative predictive value

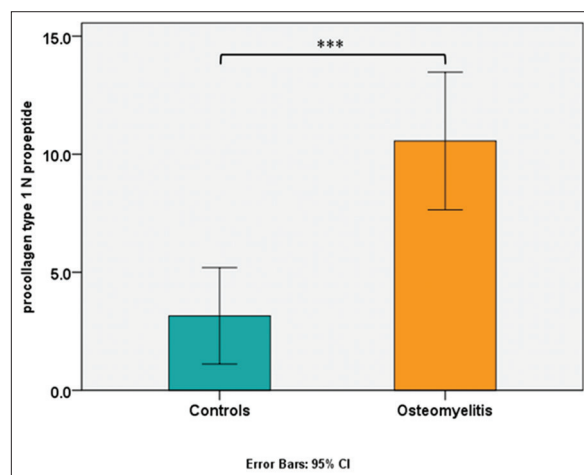


Figure 1: Higher serum procollagen type 1 N propeptide concentration in patients with diabetic foot osteomyelitis compared to control group. ***P < 0.0001

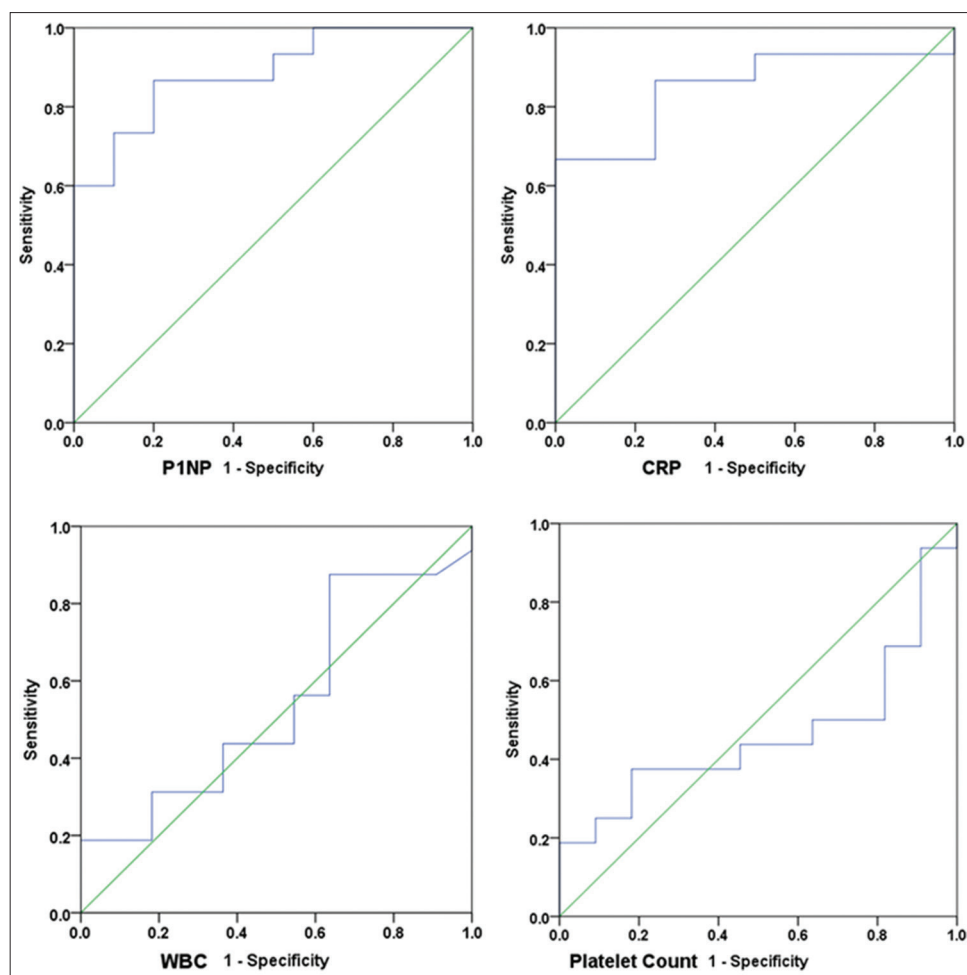


Figure 2: Receiver operator characteristic curves showing best value for procollagen type 1 N propeptide in diagnosing diabetic foot osteomyelitis compared to other three tests – white blood counts, C-reactive protein, and platelets

a specificity of 68%; thus have equivalent specificity as plain radiography, with increased sensitivity.^[5,23] MRI has the highest sensitivity and specificity of the diagnostic imaging modalities with 90% and 79%, respectively, hence it is considered the gold standard of the noninvasive diagnostic modalities.^[19,23] However, bone biopsy with histology and microbiological culture is considered the absolute gold standard.^[18] Overall, the current diagnostic methods for osteomyelitis each has significant drawbacks including invasiveness (biopsy), extended lag time to positivity (radiograph), poor sensitivity (plain radiograph), and poor specificity (bone scan). Leukocyte scans, bone scans, MRIs, and biopsies, all require specialized skills, are costly and have limited availability in resource-poor regions.^[24] Thus, at present, there is no low-cost option that has high diagnostic sensitivity and specificity that is available regardless of the level of the health service.

The potential value of using P1NP is of particular interest, as this method has not been previously used particularly in resource-deprived communities where modern diagnostic facilities are scarce and when available often beyond the

reach of an average patient. We believe the increased P1NP in patients with DFO could be due to acute release of the bone formation turnover marker from infected bone as noted by Nair *et al.*^[14] Our study further revealed a diagnostic accuracy of P1NP superior to values for CRP, WBC, and platelets. Indeed apart from CRP, other tested hematological markers did not show significantly elevated levels for diagnosing DFO. Our findings suggest P1NP being specific to the bone can be more reliable than other nonspecific inflammatory markers in diagnosing DFO. It is interesting to note that using P1NP in the diagnosis of DFO has the potential to save cost, particularly in developing countries where sophisticated diagnostic imaging is either not available or unaffordable to patients requiring urgent care. There is a significant cost differential between the P1NP which costs <USD 30 per test compared to several hundreds of dollars per test using advanced diagnostic imaging (MRI and nuclear bone scan).^[25,26] Furthermore, with the high sensitivity and negative predictive value of P1NP means, it could be used in deciding who requires undergoing further testing with expensive medical imaging techniques. Similarly, with the high specificity and positive

predictive values of P1NP indicates a strong ability to rule in the diagnosis of DFO for patients who may require further testing to confirm the diagnosis.

Our results faced potential limitations. First, our sample size though small, it fitted with the outlined objectives for a pilot study with adequate statistical power to detect differences between the 2 study groups. Second, we did not conduct bone biopsy on all patients involved in the study. Although bone biopsy is usually considered the gold standard for the diagnosis of osteomyelitis, such procedure may not be routinely performed in clinical practice due to ethical issues, particularly in patients with low index of suspicion for DFO.^[27,28] Instead, combination of clinical, laboratory, and imaging techniques are often used to diagnose DFO in routine clinical care with high diagnostic efficiency comparable to results obtained from bone biopsy.^[20] We used the recommendation of the International Working Group on the Diabetic Foot in defining DFO in this study; basically, histologic results from bone biopsy where indicated and/or a combination of clinical and radiological findings consistent with diagnosis of DFO.^[18] Third, we did not assess the inflammatory and BTMs on healthy nondiabetic foot ulcer patients neither did we repeat the markers after completing course of antibiotics in patients diagnosed with DFO. The biomarkers were assayed before the commencement of antibiotics and at the time of diagnosing the DFO and controls. Finally, we did not compare the diagnostic efficiency of P1NP with ESR; instead, CRP was used as recent evidence has shown it to be at par or even a better marker for DFO than the former.^[29,30] In spite of these, our results are consistent with others findings of diagnostic usefulness of BTM in bone infection.^[11,12]

CONCLUSION

This trial has provided the first evidence of P1NP elevation in DFO compared to diabetic foot ulcers not complicated by osteomyelitis. Furthermore, P1NP showed significant diagnostic utility in ruling in and ruling out DFO better than other tested nonspecific inflammatory markers, and thus requires more investigations. With further research, BTMs may provide a viable low cost and widely available diagnostic methodology for diagnosing DFO.

Acknowledgments

We would like to acknowledge James Cook University Faculty of Medicine for providing financial support under Honors Project Grant. We would also like to thank Amy Langley, Amelia Turner, Julie Goodall and Karen Hird for identifying appropriate patients for enrolment and Emily Beric for deciphering the manuscript.

Financial support and sponsorship

Nil.

Conflicts of interest

There are no conflicts of interest.

REFERENCES

1. Ray JA, Valentine WJ, Secnik K, Oglesby AK, Cordony A, Gordois A, *et al.* Review of the cost of diabetes complications in Australia, Canada, France, Germany, Italy and Spain. *Curr Med Res Opin* 2005;21:1617-29.
2. Campbell LV, Graham AR, Kidd RM, Molloy HF, O'Rourke SR, Colagiuri S, *et al.* The lower limb in people with diabetes. Position statement of the Australian diabetes society. *Med J Aust* 2000;173:369-72.
3. Wheat J. Diagnostic strategies in osteomyelitis. *Am J Med* 1985;78:218-24.
4. Newman LG. Imaging techniques in the diabetic foot. *Clin Podiatr Med Surg* 1995;12:75-86.
5. Maugendre D, Poirier JY. Nuclear medicine in the diagnosis of diabetic foot osteomyelitis. *Diabetes Metab* 2001;27:396-400.
6. Rosenthal L. Radionuclide investigation of osteomyelitis. *Curr Opin Radiol* 1992;4:62-9.
7. Malabu UH, Al-Rubeaan KA, Al-Derewish M. Diabetic foot osteomyelitis: Usefulness of erythrocyte sedimentation rate in its diagnosis. *West Afr J Med* 2007;26:113-6.
8. Hayes GH, Vangaveti NV, Malabu UH. Diagnostic performance of serum bone turnover marker lysylpyridinoline in diabetic foot osteomyelitis: A preliminary study. *Clin Med Diagn* 2016;6:49-53.
9. Nyazee HA, Finney KM, Sarikonda M, Towler DA, Johnson JE, Babcock HM, *et al.* Diabetic foot osteomyelitis: Bone markers and treatment outcomes. *Diabetes Res Clin Pract* 2012;97:411-7.
10. Southwood LL, Frisbie DD, Kawcak CE, McIlwraith CW. Evaluation of serum biochemical markers of bone metabolism for early diagnosis of nonunion and infected nonunion fractures in rabbits. *Am J Vet Res* 2003;64:727-35.
11. Shi J, Wang Z, Li H, Yuan H. Diagnostic performance of the urinary deoxypyridinoline in spinal tuberculosis. *Orthopedics* 2012;35:e922-6.
12. Springer IN, Wiltfang J, Dunsche A, Lier GC, Bartsch M, Warnke PH, *et al.* A new method of monitoring osteomyelitis. *Int J Oral Maxillofac Surg* 2007;36:527-32.
13. Philipov JP, Pascalev MD, Aminkov BY, Grosev CD. Changes in serum carboxyterminal telopeptide of type I collagen in an experimental model of canine osteomyelitis. *Calcif Tissue Int* 1995;57:152-4.
14. Nair SP, Meghji S, Wilson M, Reddi K, White P, Henderson B, *et al.* Bacterially induced bone destruction: Mechanisms and misconceptions. *Infect Immun* 1996;64:2371-80.
15. Hlaing TT, Compston JE. Biochemical markers of bone turnover-uses and limitations. *Ann Clin Biochem* 2014;51:189-202.
16. Armstrong DG, Harkless LB. Outcomes of preventative care in a diabetic foot specialty clinic. *J Foot Ankle Surg* 1998;37:460-6.
17. Oyibo SO, Jude EB, Tarawneh I, Nguyen HC, Harkless LB, Boulton AJ, *et al.* A comparison of two diabetic foot ulcer classification systems: The Wagner and the University of Texas wound classification systems. *Diabetes Care* 2001;24:84-8.
18. Lipsky BA, Aragón-Sánchez J, Diggle M, Embil J, Kono S, Lavery L, *et al.* IWGDF guidance on the diagnosis and management of foot infections in persons with diabetes. *Diabetes Metab Res Rev* 2016;32 Suppl 1:45-74.
19. Mills JL Sr., Conte MS, Armstrong DG, Pomposelli FB, Schanzer A, Sidawy AN, *et al.* The society for vascular surgery lower extremity threatened limb classification system: Risk stratification based

- on wound, ischemia, and foot infection (WIFI). *J Vasc Surg* 2014;59:220-340.
20. Lipsky BA, Peters EJ, Senneville E, Berendt AR, Embil JM, Lavery LA, *et al.* Expert opinion on the management of infections in the diabetic foot. *Diabetes Metab Res Rev* 2012;28 Suppl 1:163-78.
 21. Biver E. Use of bone turnover markers in clinical practice. *Curr Opin Endocrinol Diabetes Obes* 2012;19:468-73.
 22. Morris HA, Eastell R, Jorgensen NR, Cavalier E, Vasikaran S, Chubb SA, *et al.* Clinical usefulness of bone turnover marker concentrations in osteoporosis. *Clin Chim Acta* 2017;467:34-41.
 23. Nawaz A, Torigian DA, Siegelman ES, Basu S, Chryssikos T, Alavi A, *et al.* Diagnostic performance of FDG-PET, MRI, and plain film radiography (PFR) for the diagnosis of osteomyelitis in the diabetic foot. *Mol Imaging Biol* 2010;12:335-42.
 24. Dinh MT, Abad CL, Safdar N. Diagnostic accuracy of the physical examination and imaging tests for osteomyelitis underlying diabetic foot ulcers: Meta-analysis. *Clin Infect Dis* 2008;47:519-27.
 25. Schousboe JT, Bauer DC, Nyman JA, Kane RL, Melton LJ, Ensrud KE, *et al.* Potential for bone turnover markers to cost-effectively identify and select post-menopausal osteopenic women at high risk of fracture for bisphosphonate therapy. *Osteoporos Int* 2007;18:201-10.
 26. Chow I, Lemos EV, Einarson TR. Management and prevention of diabetic foot ulcers and infections: A health economic review. *Pharmacoeconomics* 2008;26:1019-35.
 27. Senneville E, Melliez H, Beltrand E, Legout L, Valette M, Cazaubiel M, *et al.* Culture of percutaneous bone biopsy specimens for diagnosis of diabetic foot osteomyelitis: Concordance with ulcer swab cultures. *Clin Infect Dis* 2006;42:57-62.
 28. Kessler L, Piemont Y, Ortega F, Lesens O, Boeri C, Averous C, *et al.* Comparison of microbiological results of needle puncture vs. Superficial swab in infected diabetic foot ulcer with osteomyelitis. *Diabet Med* 2006;23:99-102.
 29. Michail M, Jude E, Liaskos C, Karamagiolis S, Makrilakis K, Dimitroulis D, *et al.* The performance of serum inflammatory markers for the diagnosis and follow-up of patients with osteomyelitis. *Int J Low Extrem Wounds* 2013;12:94-9.
 30. Pääkkönen M, Kallio MJ, Kallio PE, Peltola H. C-reactive protein versus erythrocyte sedimentation rate, white blood cell count and alkaline phosphatase in diagnosing bacteraemia in bone and joint infections. *J Paediatr Child Health* 2013;49:E189-92.

