

Sonographic diagnosis of proximal median nerve entrapment due to an arteriovenous graft in a hemodialysis patient

Sir,

A 64-year-old woman with a 2-year history of chronic renal failure had undergone hemodialysis through the arteriovenous fistula on her left forearm. Owing to occlusion of the fistula, she received an arteriovenous graft anastomosis of the brachial artery and basilic vein. Thereafter, she started to feel numbness over her palm, thumb, and first three fingers. Under the impression of carpal tunnel syndrome (CTS), she was treated with ultrasound diathermy over the wrist, but her discomfort persisted even after 6 treatment sessions. Eventually, she was referred for an ultrasonography (US) examination (on the 3rd week of the operation).

The scan was initiated from the wrist, where the median nerve (MN) had a normal cross-sectional area [8.5 mm²; Figure 1a].^[1] We kept tracking the nerve back to the forearm, and again, no focal enlargement was observed. When moving the transducer cranially toward the elbow, the US images showed that the MN was entrapped in the area bordered by the arteriovenous graft, brachial artery, and recurrent ulnar artery [Figure 1b-d; Video 1]. The sono-Tinel sign was also positive when the transducer was used to compress the intersection region. After a revision surgery for the arteriovenous graft, the numbness was relieved.

While CTS is the most common entrapment peripheral neuropathy, the MN can be compressed more cranially by the bicipital aponeurosis, both heads of the pronator teres muscle, and the sublimis bridge of the flexor superficialis muscle.^[2] Proximal MN entrapment is less likely to cause dysesthesia in the forearm, where the cutaneous sensation is supplied by the lateral and medial antebrachial cutaneous nerves. Furthermore, the palmar branch of the MN diverts from the main trunk proximal to the carpal tunnel inlet.^[3] Therefore, palmar numbness, a key symptom differentiating our case from typical CTS, led us to scrutinize proximal MN entrapment.

US imaging is useful for the diagnosis of CTS,^[1,4] especially in patients with a forearm vascular access

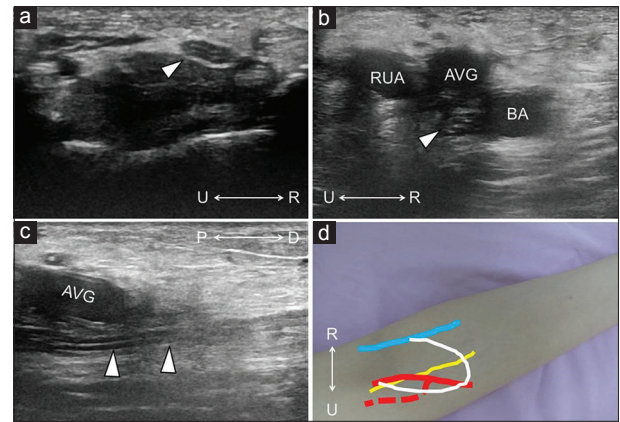


Figure 1: Axial ultrasonographic imaging of the median nerve (arrowhead) at the wrist (a) and elbow. (b) Longitudinal image of the elbow. (c) Schematic drawings of the median nerve (yellow line), brachial artery (red line), recurrent ulnar artery (dashed red line), arteriovenous graft (white line), and basilic vein (blue line) at the entrapment site (d). RUA: Recurrent ulnar artery; AVG: Arteriovenous graft; BA: Brachial artery; U: Ulnar side; R: Radial side; P: Proximal side; D: Distal side

for hemodialysis (such as our patient). Concomitant uremic neuropathy makes nerve conduction studies challenging, and the vascular access precludes detailed electromyography on the forearm muscles. In our case, the MN was not swollen and did not change in echotexture near the entrapment site (probably because of its acute course). Herewith, the positive sono-Tinel sign was important for confirming the diagnosis.

The orifice of the arteriovenous graft is usually opened at the lateral aspect of the artery because the MN courses medially to the brachial artery at the elbow.^[4] In our patient, the superior medial location of the orifice rendered the MN to entrapment, where the scenario was further worsened by an engorged recurrent ulnar artery due to increased blood flow. In short, we underscore the usefulness of US imaging while investigating the etiology of MN entrapment in a hemodialysis patient. For sure, precise diagnosis would prompt the surgeon to revise the vascular graft early to relieve nerve compression.

Declaration of patient consent

The authors certify that they have obtained all appropriate patient consent forms. In the form the patient(s) has/have given his/her/their consent for his/her/their images and other clinical information to be reported in the journal. The patients understand that their names and initials will not be published and due efforts will be made to conceal their identity, but anonymity cannot be guaranteed.

Financial support and sponsorship

This work was supported by grants from MOST 106-2314-B-002-180, National Taiwan University Hospital

(Bei-Hu branch) and Taiwan Society of Ultrasound in Medicine.

Conflicts of interest

There are no conflicts of interest.

Ke-Vin Chang, Wei-Ting Wu, Levent Özçakar¹

Department of Physical Medicine and Rehabilitation, Community and Geriatric Research Center, College of Medicine, National Taiwan University Hospital, Bei-Hu Branch and National Taiwan University, Taipei, Taiwan, ¹Department of Physical and Rehabilitation Medicine, Hacettepe University Medical School, Ankara, Turkey

Address for correspondence: Dr. Ke-Vin Chang,

Department of Physical Medicine and Rehabilitation, National Taiwan University Hospital, Bei-Hu Branch, No. 87 Neijiang St., Wanhua District, Taipei City 108, Taiwan.

E-mail: kvchang011@gmail.com, pattap@pchome.com.tw

REFERENCES

1. Tai TW, Wu CY, Su FC, Chern TC, Jou IM. Ultrasonography for diagnosing carpal tunnel syndrome: A meta-analysis of diagnostic test accuracy. *Ultrasound Med Biol* 2012;38:1121-8.
2. Rodner CM, Tinsley BA, O'Malley MP. Pronator syndrome and anterior interosseous nerve syndrome. *J Am Acad Orthop Surg* 2013;21:268-75.

3. Hobbs RA, Magnussen PA, Tonkin MA. Palmar cutaneous branch of the median nerve. *J Hand Surg Am* 1990;15:38-43.
4. Wu CH, Chang KV, Özçakar L, Hsiao MY, Hung CY, Shyu SG, *et al.* Sonographic tracking of the upper limb peripheral nerves: A pictorial essay and video demonstration. *Am J Phys Med Rehabil* 2015;94:740-7.

This is an open access article distributed under the terms of the Creative Commons Attribution-NonCommercial-ShareAlike 3.0 License, which allows others to remix, tweak, and build upon the work non-commercially, as long as the author is credited and the new creations are licensed under the identical terms.

Video Available on: www.jmsjournal.net

Access this article online

Quick Response Code:



Website:

www.jmsjournal.net

DOI:

10.4103/jrms.JRMS_844_17

How to cite this article: Chang KV, Wu WT, Özçakar L. Sonographic diagnosis of proximal median nerve entrapment due to an arteriovenous graft in a hemodialysis patient. *J Res Med Sci* 2017;22:136.

