

Noting a black ring at bending: A postcataract surgery symptom!

Sir,

A 59-year-old female presented to us complaining of noting a dark ring with her left eye (OS) when bending her head forward. She had undergone uncomplicated cataract surgery of the OS 2 days before. In the surgery description report, phacoemulsification cataract surgery of a mature crystalline lens was mentioned with successful implantation of posterior chamber (PC) intraocular lens without vitreous loss (VL).

On examination, best-corrected visual acuity was 20/20 right eye (OD) and 16/20 OS. Pupillary reflex was normal with no relative afferent defect. Red reflex was 10/10 OD and 9/10 OS. Extraocular movements were normal each eye (OU). On slit-lamp examination, both eyes were pseudophakic. In the OS, mild corneal edema, trace reaction, and a residual 25% air bubble on upper side of anterior chamber (AC) were seen [Figure 1a]. Very mild iridodonesis could be detected on movements of the OS. Anterior and posterior vitreous examination as well as posterior pole fundoscopy were unremarkable OU. On peripheral indirect fundoscopy, a bubble could hardly be seen on uppermost far periphery of the left retina [Figure 1b]. The bubble crept finely over the peripheral retina with gaze movements.

In the second visit on day 4, she had no bothering visual symptoms anymore. On examination, AC air bubble as well as that in the posterior segment was absorbed completely.

We describe a symptom which has not been previously described following cataract surgery.^[1-3] Noting the dark ring was annoying and intimidating to the patient and was completely postural, occurring only when bowing forward and disappearing when holding head up high. Existence of a bubble in posterior segment of a patient with AC formed with air and no history of VL could be simply explained by immigration of the air from AC to posterior segment through a possible zonular defect. Complaining of such postural visual symptoms after cataract surgery is considered as a benign symptom if retained AC air bubble exists.

Financial support and sponsorship

Nil.

Conflicts of interest

There are no conflicts of interest.

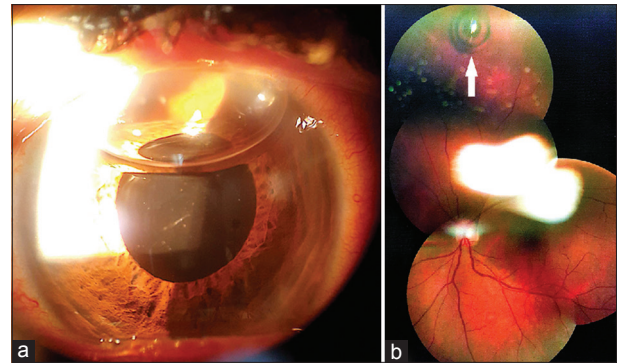


Figure 1: (a) Air bubble in anterior chamber of the left eye on postoperative day 2. (b) Fundus photograph of the left eye on postoperative day 2; the arrow denotes an air bubble on the uppermost far periphery of the retina

**Seyed-Hossein Abtahi^{1,2},
Mohammad-Ali Abtahi^{1,2}, Seyed Ali Akbar Mortazavi^{1,2},
Hamidreza Jahanbani-Ardakani^{2,3,4}, Mehdi Mazloumi⁵**

¹Department of Ophthalmology, School of Medicine, Isfahan University of Medical Sciences, ²Isfahan Eye Research Center, Isfahan University of Medical Sciences, ³Medical School, Isfahan University of Medical Sciences, ⁴Isfahan Medical Students Research Center, Isfahan University of Medical Sciences, Isfahan, ⁵Eye Research Center, Farabi Eye Hospital, Tehran University of Medical Sciences, Tehran, Iran

Address for correspondence: Dr. Seyed-Hossein Abtahi, Feiz Hospital, Qods Sq., Isfahan, Iran.
E-mail: shf.abtahi@yahoo.com

REFERENCES

1. Lee MS, Rizzo JF 3rd, Lessell S. Neuro-ophthalmologic complications of cataract surgery. *Semin Ophthalmol* 2002;17:149-52.
2. Day AC, Donachie PH, Sparrow JM, Johnston RL; Royal College of Ophthalmologists' National Ophthalmology Database. The Royal College of Ophthalmologists' National Ophthalmology Database study of cataract surgery: report 1, visual outcomes and complications. *Eye (Lond)* 2015;29:552-60.
3. Pershing S, Morrison DE, Hernandez-Boussard T. Cataract surgery complications and revisit rates among three states. *Am J Ophthalmol* 2016;171:130-8.

This is an open access article distributed under the terms of the Creative Commons Attribution-NonCommercial-ShareAlike 3.0 License, which allows others to remix, tweak, and build upon the work non-commercially, as long as the author is credited and the new creations are licensed under the identical terms.

Access this article online	
Quick Response Code: 	Website: www.jmsjournal.net
	DOI: 10.4103/jrms.JRMS_236_17

How to cite this article: Abtahi S, Abtahi M, Mortazavi SA, Jahanbani-Ardakani H, Mazloumi M. Noting a black ring at bending: A postcataract surgery symptom! *J Res Med Sci* 2017;22:79.