

Classic high lateral tension and triangular resection methods to prevent dog ear and elongation scar in patients undergoing abdominoplasty: A comparative open-label clinical trial

Hossein Abdali^{1,2}, Mohammadbagher Heydari^{2,3}, Mahmood Omranifard², Mahdi Rasti²

¹Craniofacial Anomalies and Cleft Palate Research Center, Alzahra Research Institute, ²Department of Plastic Surgery, Isfahan University of Medical Sciences, Isfahan, ³Department of Surgery, Imam Reza Hospital, Kermanshah University of Medical Science, Kermanshah, Iran

Background: One of the most common operations in the plastic surgery course is abdominoplasty. Several methods were recommended for achieving better results. In the present study, efficacy of a new method compared with classical high lateral tension on preventing dog ear and elongation scar was evaluated. **Materials and Methods:** in an open-label, randomized clinical trial, seventy patients who were candidates for abdominoplasty were selected and randomly divided into two groups. The first group was operated by classic high lateral method and the second group was operated by a new method concentrating on changing incision line and angle. Dog ear prevention, length of scar, improvement, and postoperative complications were compared between the two groups. **Results:** The mean \pm standard deviation (SD) length of scar in treated patients with classical and new abdominoplasty surgical methods was 53.68 ± 6.34 and 41.71 ± 1.78 cm, respectively, and the length of scar in the group treated with the new method was significantly shorter ($P < 0.001$). The mean \pm SD distance between two anterior superior iliac spine in group treated by new method was significantly decreased after surgery (31.3 ± 1.3 cm) compared to before intervention (36.7 ± 3.9 cm) ($P < 0.01$). **Conclusion:** The new method is more likely to be successful in patients with high lateral tension abdominoplasty. However, according to the lack of similar studies in this regard and the fact that this method was introduced for the first time, it is recommended that further studies in this area are needed and patients in term of complications after surgery need a longer period of follow-up.

Key words: Abdominoplasty, dog ear, high lateral tension, scar length

How to cite this article: Abdali H, Heydari M, Omranifard M, Rasti M. Classic high lateral tension and triangular resection methods to prevent dog ear and elongation scar in patients undergoing abdominoplasty: A comparative open-label clinical trial. J Res Med Sci 2017;22:73.

INTRODUCTION

One of the most operation after significant weight loss is abdominoplasty to remove excess skin. The main goal of this procedure is to picking up the maximum amount of abdominal skin and subcutaneous tissues with best cosmetic results.^[1] Abdominoplasty began in 1899 with an operation performed by Kelly and became a common surgical approach.^[2] Varying degrees of skin laxity, increased fat tissue, muscle detachment, and relaxation of muscle sheath and deformities caused by scar as a

result of striae are common among patients who had been undergone this type of surgery. Abdominoplasty can be performed in patients with a wide range of medium lipodystrophy to high obesity. Fluid accumulation in the abdominal wall, infection, skin necrosis, responding to the strings, hypertrophic scars, fat tissue remaining in the epigastric, deep vein thrombosis, and pulmonary complications are potentially dangerous complications in abdominoplasty.^[2,3] The overall reported complication rate on this surgical method is about 11%, in which among them, the incidence of skin necrosis (8%) is the most common complication.^[4,5] Previous studies showed

Access this article online

Quick Response Code:



Website:
www.jmsjournal.net

DOI:
10.4103/jrms.JRMS_214_16

This is an open access article distributed under the terms of the Creative Commons Attribution-NonCommercial-ShareAlike 3.0 License, which allows others to remix, tweak, and build upon the work non-commercially, as long as the author is credited and the new creations are licensed under the identical terms.

For reprints contact: reprints@medknow.com

Address for correspondence: Dr. Mohammadbagher Heydari, Department of Plastic Surgery, Alzahra University Hospital, Isfahan University of Medical Sciences, Isfahan, Iran. E-mail: mohammadbagher_heydari@yahoo.com

Received: 17-03-2016; **Revised:** 10-08-2016; **Accepted:** 14-03-2017

that the observed complications following abdominoplasty were significantly related to gender, age, race, body mass index (BMI) of patients before surgery, and surgical skills.^[6-8]

In a study, the incidence of early complications was reported in 18% of patients including seroma (5%), hematoma (3%), infection (3%), skin or fat necrosis (2.5%).^[9] In addition to the general symptoms as mentioned earlier, the most important abdominoplasty complications include bleeding, seroma, infection, skin necrosis, thromboembolism, and fat embolism.^[10] According to the published documents by the American Society of Plastic Surgeons in 2004, the American Society of Plastic Surgeons documents, published in 2004, during the past 7 years, the number of abdominoplasty cases has been raised about 344%.^[11,12] A comparison of the high lateral tension abdominoplasty which is listed in literature as an acceptable method^[13] and new method, it seems the patients were less scarring and reduced complications, shorten the operation time and prevented the emergence of the dog ears. There is no reported epidemiology for dog ear but reported by some papers and it is a common side of abdominoplasty and important for taking to account. And our aim was to compare two methods in decreasing of abdominoplasty complications which noted above such as dog ear, etc.

MATERIALS AND METHODS

Study design and participants

This study is a clinical trial which was conducted in 2014 and 2015 in Al-Zahra Hospital, one of the biggest referral hospitals in the center of Iran affiliated to Isfahan University of Medical Sciences. The study population comprised candidate patients undergoing abdominoplasty surgery. The inclusion criteria consisted of no previous history of abdominal surgery, no scar in the upper abdomen, no history of severe comorbid conditions (e.g., diabetes or heart disease), BMI>40, lack of pregnancy or eventual future plans for pregnancy, no history of thromboembolism, nonsmoking, and nonsusceptibility to keloid or hypertrophic scar. Concomitant surgeries, body image disorder, and withdrawal of patients to participate in the study were considered exclusion criteria.

All participants provided informed written consent, and the Ethics Committee of the Isfahan University of Medical Sciences ethically approved the study (No: 394527). The trial has been registered in the Iranian Registry of Clinical Trials website at <http://www.irct.ir> (IR.MUI.Rec. 1394.3.527).

Procedure and variable assessment

The eligible seventy patients for undergoing abdominoplasty were randomized using random permuted blocks of size 2 into one of the surgical approaches. The demographic data and medical records of patients were recorded in a special form.

Markings were made with the patient in the upright position. As described earlier, the borders of the underwear are initially marked. Like a standard abdominoplasty, the patient is asked to elevate the redundant abdominal tissue for identification of the abdominal fold. A vertical distance of 7–8 cm is measured from the vulva commensure or base of the penis. Followed by marking of the lower incision line parallel to the abdominal fold, the inferior incision line is drawn laterally toward the anterior superior iliac spine (ASIS). In addition, the middle line and the suction areas in the flank and epigastric region of paramedian were marked and then the operation was started. After the injection of liquid tumescent, suction of flank area, epigastric region, and Mons pubis region was performed. Marked area in the lower part was cut and the abdominal flap become free and continued until the edge of ribs and xiphoid. Plication of abdominal wall was done, and then the operating table was placed in the V shape and the excess skin is marked in the midline. Key suture was made in the midline, and the umbilical cord exit area was marked and navel was removed from the cord. The upper limit of resection in this case was marked, and the excess skin was removed and in the lateral dog ear of the skin which was caused by the resection should be re-cut. Another line in lateral side is marked upward in straight line and incises sharply with 4–5 cm length and marked from lateral to medial and resected triangular skin and subcutaneous tissue. Anatomically, wound is closed [Figure 1]. In this new method, cut side up, and then a triangular piece is removed and then restored parity just made classic. To assess scar condition of patients, Vancouver criteria were used. The length of suture line is measured and compared to initial distance between midline to ASIS, and incision percentage in length was compared with classic technique. The four standard criteria, i.e., pigmentation, vascularity, pliability, and height were measured.

Statistical analysis

Data were analyzed using SPSS version 16 (SPSS Inc., Chicago, IL, USA). Quantitative and qualitative variables were expressed as mean \pm standard deviation (SD) and frequency (percentages). Normality of quantitative data was evaluated using Kolmogorov–Smirnov test, and Q-Q plot Chi-square test or Fisher's exact test were used for comparing qualitative data between studied groups while independent *t*-test or Mann–Whitney U-test was used for comparing quantitative data. Paired samples *t*-test was used for within-group comparisons.

RESULTS

In this study, seventy patients undergoing abdominoplasty were studied in two groups of 35 patients who were operated with classic abdominoplasty and 35 patients who were operated with triangular resection of abdominoplasty. All patients completed the study protocol [Figure 2].

Table 1 shows the demographic variables of the two groups. No significant differences were found between the studied groups in terms of age, sex, BMI, and duration of surgery. The average length of scar in the patients treated with classic method was significantly higher than those in new methods ($P < 0.001$) [Figure 3].

Table 2 shows the frequency of postoperative complications in the two groups. As can be seen, the incidence of dog ear in patients undergoing the new procedure was significantly lower than that of classical approach while no significant

differences were found between the two groups in terms of incidence of other complications.

The mean \pm SD distance between two ASIS groups before and after surgery in classic group was 37.9 ± 2.6 and 35 ± 7.4 cm, respectively ($P < 0.05$). The mean \pm SD distance between two ASIS groups treated by new method significantly decreased after surgery (31.3 ± 1.3 cm) compared to before intervention (36.7 ± 3.9 cm) ($P < 0.01$). Furthermore, the observed differences were significant between the two groups in which the observed difference

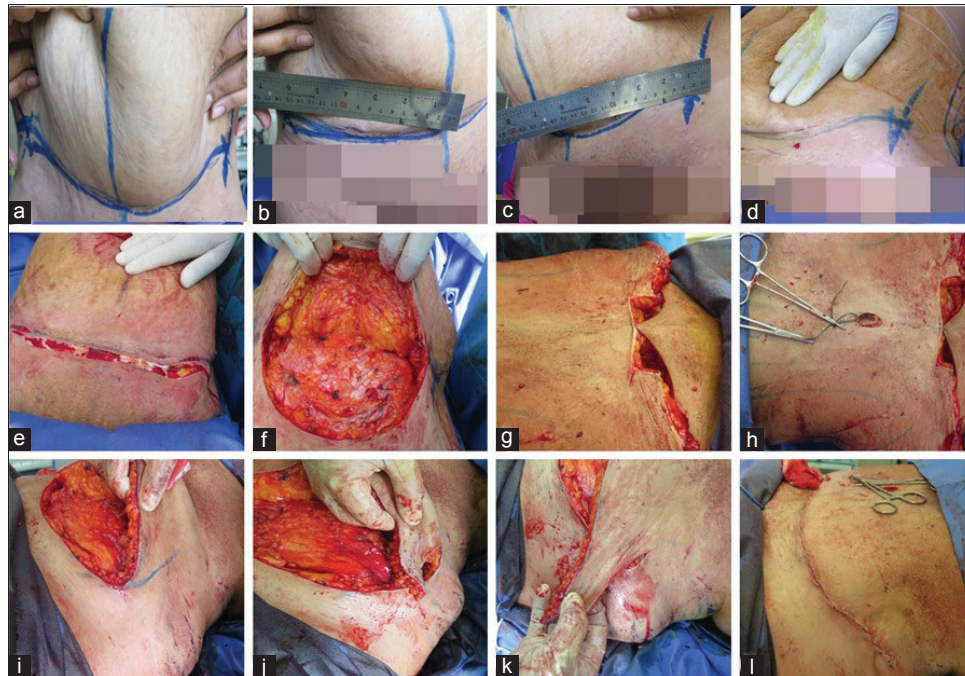


Figure 1: Procedure of triangular resection method: a-d. Preparation marking and mid-line measurement from right and left ASIS; e. Low crease incision; f. Subcutaneous dissection; g. Mid-line suture; h. Replacement umbilicus; i-k. Triangular resection of skin excess in lateral side; l. Skin and subcutaneous suture

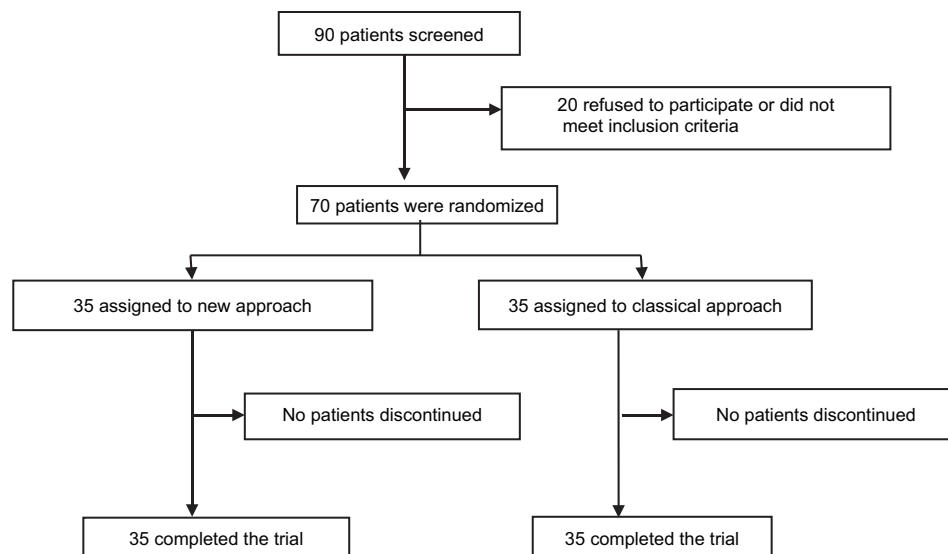


Figure 2: Flow diagram of recruitment of patients into the trial

was significantly higher in patients treated with new approach compared to classical method ($P < 0.001$) [Figure 3].

Table 1: Basic characteristics of the two studied groups

Variables	Groups		P
	Classical approach (%)	New approach (%)	
Age			
Mean±SD	38.4±8.6	37.9±5.6	0.76
<40	20 (57.1)	21 (60)	0.81
≥40	15 (42.9)	14 (40)	
Sex			
Male	1 (2.9)	4 (11.4)	0.36
Female	34 (97.1)	31 (88.6)	
BMI			
Mean±SD	27.03±2.37	26.7±1.59	0.50
Normal	7 (20)	4 (11.4)	0.25
Overweight	23 (65.7)	29 (82.9)	
Obese	5 (14.3)	2 (5.7)	
Operation time (min)	99.7±9.6	98±6.9	0.39

SD=Standard deviation; BMI = Body mass index

Table 2: Postoperative complications in the two groups

Variables	Groups		P*
	Classic approach (%)	New approach (%)	
Dog ear			
Yes	10 (28.6)	2 (5.7)	0.01
No	25 (71.4)	33 (94.3)	
Infection			
Yes	7 (20)	1 (2.9)	0.06
No	28 (80)	34 (97.1)	
Dehiscence			
Yes	3 (8.6)	1 (2.9)	0.61
No	32 (91.4)	34 (97.1)	
Other			
Yes	4 (11.4)	3 (8.6)	0.99
No	31 (88.6)	32 (91.4)	

*Resulted from Chi-square or Fisher's exact test

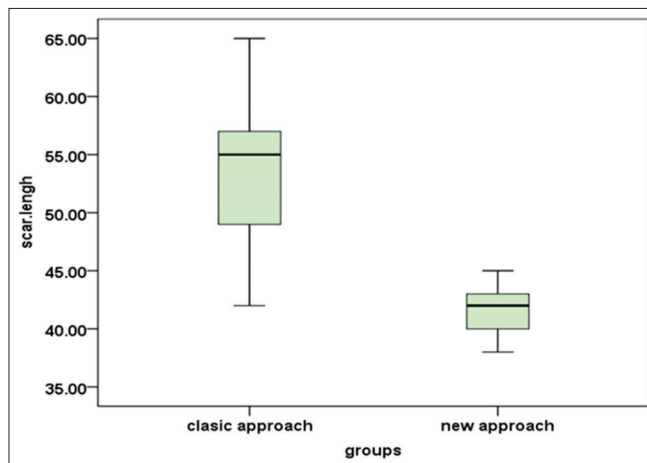


Figure 3: Box plot of scar length in two groups

A significant difference was found between the mean score of Vancouver criteria in the groups treated with classic and new methods (3.37 ± 1.09 vs. 3.97 ± 0.82 , respectively; $P < 0.05$). Table 3 shows the frequency of symptoms of ulcer scars according to the Vancouver criterion in two groups. Table 3 shows that the distribution of pigmentation intensity in both groups is statistically significant in which it was lower in new modality than classical approach. However, other symptoms were not significantly different between the two groups.

DISCUSSION

Abdominoplasty is one of the most common surgical procedures currently performed in the area of plastic surgery.^[4] Abdominoplasty is usually done with the purpose of health and beauty, but has some complications which are considerable.^[14-16] Classic abdominoplasty is currently taking place around the world and has complications in 11% of patients^[17,18] that some of these side effects are created as early symptoms, while other signs will appear in the final stages. The method which was introduced in this study is based on the change in the incision location, and experience of authors has shown that this method achieves a significant reduction in postoperative complications, especially during the scar specifications and other associated side effects. In the classic method of incision, operation is carried out in an area parallel to lower abdominal crisis but in the method introduced, the end of the incision is done on the lower abdomen, diagonally and in fact a triangular portion of lateral area is removed. Our study results did not indicate statistically significant difference between the two groups in terms of demographic variables, which are noted in Table 1. Accordingly, patients who had undergone the surgery by employing the triangular resection method had shorter length of scars, while the distance between the two ASIS was more. The study of postoperative complications showed that the incidence of dog ears that are actually quite common after abdominoplasty is significantly reduced using the new method, but the occurrence of other complications between the two groups was not considerably different.^[19] Furthermore, the liposuction was done in two groups and the amount of flank liposuction was matched in the two groups. Study on scar characteristics in both groups also showed that patients treated with the new method had more favorable situation in terms of pigmentations, although there was no significant difference in other items of Vancouver criteria, normal items were more desirable in the present technique.

One of the most important risk factors for postoperative complications in the classical way of the incision was the length of the scar which was shortened as a result of the new

Table 3: Frequency distribution of scar characteristics according to the Vancouver criterion

Variables	Groups		P*
	Classical approach (%)	New approach (%)	
Pigmentation			
Normal	13 (37.1)	4 (11.4)	0.03
Hypopigmentation	3 (8.6)	2 (5.7)	
Hyperpigmentation	19 (54.3)	29 (82.9)	
Vascularity			
Normal	19 (54.3)	16 (45.7)	0.22
Pink	14 (40)	19 (54.3)	
Red	2 (5.7)	0	
Purple	0	0	
Pliability			
Normal	26 (74.3)	26 (74.3)	0.59
Supple	8 (22.9)	9 (25.7)	
Firm	1 (2.9)	0	
Bonding	0	0	
Contracture	0	0	
Height			
Flat	21 (60)	19 (54.3)	63
<2 mm	14 (40)	16 (45.7)	
<5 mm	0	0	
>5	0	0	

*Resulted from Chi-square or Fisher's exact test

method.^[14,15,19,20] this method aim to reduce level of incision, wound infection, bleeding, rupture the skin and the length of scar. However, the manner which we introduced is restricted by some factors such as the procedure required, training, and experience.

CONCLUSION

This approach is more likely to be successful in patients with high lateral tension abdominoplasty. However, according to the lack of similar studies in this regard and the fact that this method was introduced for the first time, it is recommended that further studies in this area are needed, and patients in terms of complications after surgery need a longer period of follow-up.

Financial support and sponsorship

Nil.

Conflicts of interest

There are no conflicts of interest.

REFERENCES

1. Chaouat M, Levan P, Lalanne B, Buisson T, Nicolau P, Mimoun M. Abdominal dermolipectomies: Early postoperative complications

- and long-term unfavorable results. *Plast Reconstr Surg* 2000;106:1614-8.
2. Kargi E, Akduman D, Dokuzoguz B, Ozkoçak I, Tuncel A, Deren O, *et al.* Late complication of abdominoplasty in an obese patient: Systemic inflammatory response syndrome and seroma. *Plast Reconstr Surg* 2003;111:1568-71.
3. Ogden CL, Carroll MD, Kit BK, Flegal KM. Prevalence of childhood and adult obesity in the United States, 2011-2012. *JAMA* 2014;311:806-14.
4. Swift RW, Matarasso A, Rankin M. Abdominoplasty and abdominal contour surgery: A national plastic surgery survey. *Plast Reconstr Surg* 2007;119:426-7.
5. Scerri GV, Attwood A. Early complications following abdominoplasty: Towards better patient selection. *Eur J Plast Surg* 1993;16:283-6.
6. Roje Z, Karanovic N, Utrobicic I. Abdominoplasty complications: A comprehensive approach for the treatment of chronic seroma with pseudobursa. *Aesthetic Plast Surg* 2006;30:611-5.
7. van Uchelen JH, Werker PM, Kon M. Complications of abdominoplasty in 86 patients. *Plast Reconstr Surg* 2001;107:1869-73.
8. Fourme T, Vieillard-Baron A, Loubières Y, Julié C, Page B, Jardin F. Early fat embolism after liposuction. *Anesthesiology* 1998;89:782-4.
9. Stewart KJ, Stewart DA, Coghlan B, Harrison DH, Jones BM, Waterhouse N. Complications of 278 consecutive abdominoplasties. *J Plast Reconstr Aesthet Surg* 2006;59:1152-5.
10. Neaman KC, Hansen JE. Analysis of complications from abdominoplasty: A review of 206 cases at a university hospital. *Ann Plast Surg* 2007;58:292-8.
11. Floros C, Davis PK. Complications and long-term results following abdominoplasty: A retrospective study. *Br J Plast Surg* 1991;44:190-4.
12. Joshi D, Shah J, Kamat S, Chopra S, Nachimuthu S, Mukundan C, *et al.* Apronectomy with repair of large ventral hernia in a morbidly obese patient. *Eur J Plast Surg* 2011;29:195-8.
13. Spiegelman JI, Levine RH. Abdominoplasty: A comparison of outpatient and inpatient procedures shows that it is a safe and effective procedure for outpatients in an office-based surgery clinic. *Plast Reconstr Surg* 2006;118:517-22.
14. Yoho RA, Romaine JJ, O'Neil D. Review of the liposuction, abdominoplasty, and face-lift mortality and morbidity risk literature. *Dermatol Surg* 2005;31(7 Pt 1):733-43.
15. Soeliman FA, Azadbakht L. Weight loss maintenance: A review on dietary related strategies. *J Res Med Sci* 2014;19:268-75.
16. Agha-Alinejad H, Farzad B, Salari M, Kamjoo S, Harbaugh BL, Peeri M. Prevalence of overweight and obesity among Iranian preschoolers: Interrelationship with physical fitness. *J Res Med Sci* 2015;20:334-41.
17. World Health Organization. WHO Media Center. Obesity and Overweight. Geneva: World Health Organization;2012.
18. Kilpi F, Webber L, Musaigner A, Aitsi-Selmi A, Marsh T, Rtveladze K, *et al.* Alarming predictions for obesity and non-communicable diseases in the Middle East. *Public Health Nutr* 2014;17:1078-86.
19. Hafezi F, Nouhi A. Safe abdominoplasty with extensive liposuctioning. *Ann Plast Surg* 2006;57:149-53.
20. Au K, Hazard SW 3rd, Dyer AM, Boustred AM, Mackay DR, Miraliakbari R. Correlation of complications of body contouring surgery with increasing body mass index. *Aesthet Surg J* 2008;28:425-9.