

Updates in diagnosis and management of Ebola hemorrhagic fever

Salah Mohamed El Sayed^{1,2}, Ali A. Abdelrahman³, Hani Adnan Ozbak³, Hassan Abdullah Hemeg³, Ali Mohammed Kheyami⁴, Nasser Rezk³, Mohamed Baioumy El-Ghoul⁵, Manal Mohamed Helmy Nabo^{6,7}, Yasser Mohamed Fathy⁸

¹Department of Clinical Biochemistry and Molecular Medicine, Taibah College of Medicine, Taibah University, ³Department of Medical Laboratories Technology, Faculty of Applied Medical Sciences, Taibah University, ⁴Molecular Virology Unit, Central Laboratories and Blood Bank, Directorate of Health, ⁵Department of Medicine, Uhud General Hospital, ⁷Department of Pediatrics, Division of Pediatric Cardiology, Maternity and Children Hospital, King Abdullah Medical City, Al-Madinah Al-Munawwarah, Kingdom of Saudi Arabia, ²Department of Clinical Biochemistry, Sohag Faculty of Medicine, Sohag University, ⁶Department of Pediatrics, Sohag Teaching Hospital, Sohag, ⁸Atlas Medical Center, Ministry of Health, Cairo, Egypt

Ebola hemorrhagic fever is a lethal viral disease transmitted by contact with infected people and animals. Ebola infection represents a worldwide health threat causing enormous mortality rates and fatal epidemics. Major concern is pilgrimage seasons with possible transmission to Middle East populations. In this review, we aim to shed light on Ebola hemorrhagic fever as regard: virology, transmission, biology, pathogenesis, clinical picture, and complications to get the best results for prevention and management. We also aim to guide future research to new therapeutic perspectives to precise targets. Our methodology was to review the literature extensively to make an overall view of the biology of Ebola virus infection, its serious health effects and possible therapeutic benefits using currently available remedies and future perspectives. Key findings in Ebola patients are fever, hepatic impairment, hepatocellular necrosis, lymphopenia (for T-lymphocyte and natural killer cells) with lymphocyte apoptosis, hemorrhagic manifestations, and complications. Pathogenesis in Ebola infection includes oxidative stress, immune suppression of both cell-mediated and humoral immunities, hepatic and adrenal impairment and failure, hemorrhagic fever, activation of deleterious inflammatory pathways, for example, tumor necrosis factor-related apoptosis-inducing ligand, and factor of apoptotic signal death receptor pathways causing lymphocyte depletion. Several inflammatory mediators and cytokines are involved in pathogenesis, for example, interleukin-2, 6, 8, and 10 and others. In conclusion, Ebola hemorrhagic fever is a serious fatal viral infection that can be prevented using strict health measures and can be treated to some extent using some currently available remedies. Newer treatment lines, for example, prophetic medicine remedies as nigella sativa may be promising.

Key words: Ebola hemorrhagic fever, filoviruses, fruit bats, pathogenesis, reverse transcription-polymerase chain reaction

How to cite this article: El Sayed SM, Abdelrahman AA, Ozbak HA, Hemeg HA, Kheyami AM, Rezk N, El-Ghoul MB, Nabo MMH, Fathy YM. Updates in diagnosis and management of Ebola hemorrhagic fever. *J Res Med Sci* 2016;21:83.

INTRODUCTION

Ebola virus infection constitutes a highly infectious lethal zoonosis affecting both human and nonhuman primates that usually occurs in sporadic epidemics every few years (average every 1.5 years).^[1] Central Africa and sub-Saharan Africa are the most badly affected localities and constitute the source of world epidemics possibly due to human infections from the forest bats Zaire Ebola virus caused the largest

reported outbreak of Ebola in 2014 in the West Africa. This virus was transmitted to human through infected fruit bats, monkeys, apes, and pigs. Animals got the infection mostly through contact with bat saliva or feces.^[1-4]

Due to urgency, the WHO allowed the use of experimental treatments.^[5] This review aims to elucidate the health efforts exerted to combat Ebola virus and update the diagnostic and treatment lines to fight this lethal health problem. In this article, we review the

Access this article online

Quick Response Code:



Website:

www.jmsjournal.net

DOI:

10.4103/1735-1995.192500

This is an open access article distributed under the terms of the Creative Commons Attribution-NonCommercial-ShareAlike 3.0 License, which allows others to remix, tweak, and build upon the work non-commercially, as long as the author is credited and the new creations are licensed under the identical terms.

For reprints contact: reprints@medknow.com

Address for correspondence: Dr. Salah Mohamed El Sayed, Department of Clinical Biochemistry and Molecular Medicine, Taibah College of Medicine, Taibah University, Al-Madinah Al-Munawwarah, Kingdom of Saudi Arabia.

Department of Clinical Biochemistry, Sohag Faculty of Medicine, Sohag University, Sohag, Egypt.

E-mail: salahfazara@yahoo.com

Received: 06-01-2016; **Revised:** 22-02-2016; **Accepted:** 01-05-2016

literature extensively to find out possible diagnostic and therapeutic lines in light of our understanding of Ebola virology, transmission, and pathogenesis. We also aim at developing solid prevention measures.

EBOLA VIROLOGY

Ebola virus belongs to filoviruses (family: *Filoviridae*) [Figure 1] that include a group of large viruses that have a filamentary form (with characteristic filamentous particles) that may exceed 1000 nm (80–1400 nm) in diameter. Ebola virus is a nonsegmented negative-sense RNA virus. Ebola genome includes monocistronic genes that encode for a single protein, for example, nucleoprotein (NP), virion protein (VP) 35, VP40, VP30, VP24, and RNA-dependent RNA polymerase [Figure 2] in addition to the polycistronic glycoprotein gene. The genome of Ebola virus encodes for seven proteins and two nonstructural proteins.^[6-10]

EPIDEMIOLOGY OF EBOLA HEMORRHAGIC FEVER

Filovirus hemorrhagic fever was first reported as Marburg virus in 1967 in Germany and former Yugoslavia.^[11] In equatorial Africa and some African countries, for example, Gabon, Congo, Uganda, and Sudan, Ebola virus hemorrhagic fever still constitutes a big concern for the populations mostly due to increased numbers of outbreaks and cases that were mostly caused by Zaire Ebola virus. In the Philippines, in the far East, the emergence of Reston Ebola virus in pigs increases the concern of health authorities regarding public health, agriculture, and food safety, which may threaten the emergence of health problems in some parts of Asia.^[12]

In Ebola-endemic areas, both apes and man and other mammals might be the end hosts rather than reservoir hosts.^[13] As Ebola represents a classic zoonosis, persistence of Ebola virus in reservoir animals is generally found. Bats are frequently encountered in equatorial Africa and hunted for food in many places.^[14] African fruit bats and insectivorous bats might be the reservoir hosts for Ebola [Figure 3] as documented by detection of viral RNA and antibodies in three tree-roosting species of fruit bats: *hypsignathus monstrosus*, *epomops franqueti*, and *myonycteris torquata*.^[15,16] Further evidence was reported regarding filoviruses reservoir hosts where identification and isolation of Marburg virus from the cave-dwelling fruit bat *Rousettus aegyptiacus* was reported.^[17] However, that may need further research confirmation.^[18]

EBOLA TRANSMISSION

Ebola transmission occurs mainly through contact with infected subjects and blood products. Understanding the

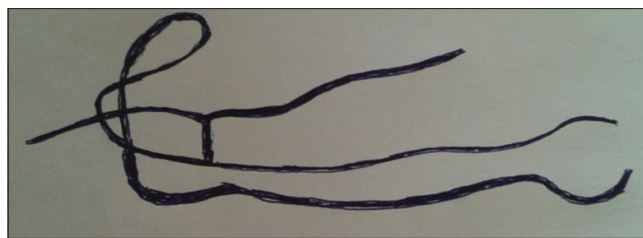


Figure 1: Ebola virus belongs to filoviruses. Filoviruses are large viruses that may reach 1400 nm in diameter

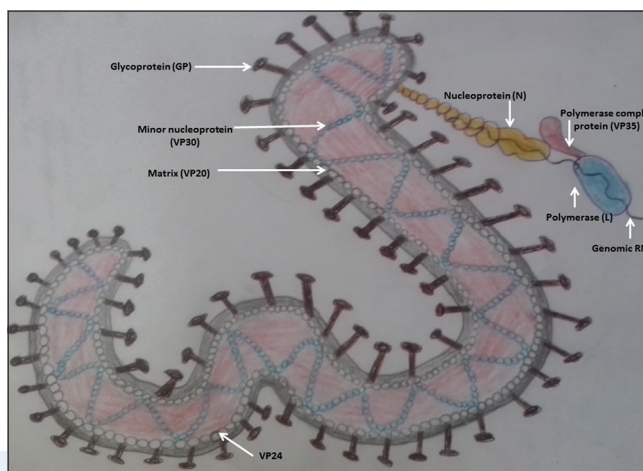


Figure 2: Structure of Ebola virus virion

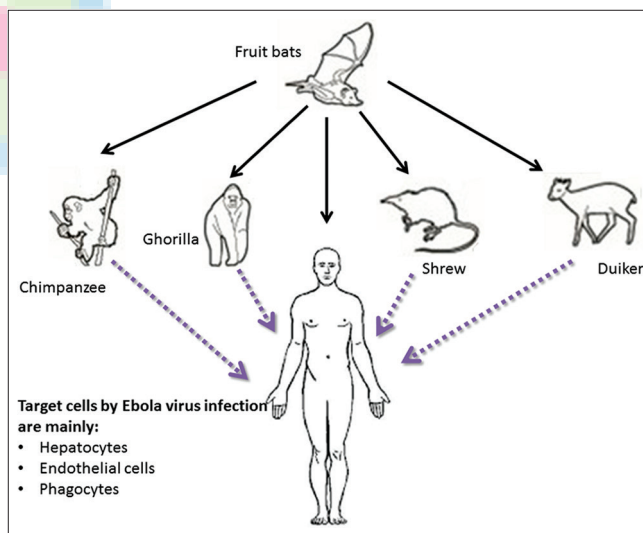


Figure 3: Mode of transmission of Ebola virus infection: Transmission of Ebola virus occurs when man consumes the flesh of fruit bats, flesh of animals fed on infected fruit bats, or through contacting or touching any contaminated matter with the virus

infectious routes and cycles through which Ebola virus can be transmitted seems critical to break the chain of transmission for future control and prevention against hemorrhagic fever viruses. Unlike respiratory viruses, both droplet and aerosol transmission regarding Ebola is thought to be rare. However, the blood-borne transmission may be critical as monocytes, macrophages, and dendritic

cells constitute the major replication sites for Ebola viruses. Therefore, blood and blood products transfusion may represent a big issue of concern. Ebola dissemination from the initial infection site may take place through monocytes, macrophages, and dendritic cells to regional lymph nodes reaching the lymphatic system, liver, and spleen through the blood.^[19]

Contact with infected patients, infected human body fluids, dead human bodies, infected cadavers, and infected animal carcasses may be the most critical route for transmitting the Ebola virus infection. Lack of early diagnosis of Ebola in rural and forest areas in Africa in addition to the lack of patients' isolation and application of quarantine measures may exaggerate the transmission of infection. Social habits regarding patient care, contact with patients' belongings and personal clothes (e.g., fomites, towels, and sheets),^[20] burial preparation (e.g., washing the dead body), and funeral ceremonies may increase the chance of Ebola transmission, particularly in epidemics.^[21,22]

Extreme care should be given to patients' body fluids even after recovery as Ebola virus was reported to be isolated from patients' biological fluids, for example, sputum, saliva, vomitus, breast milk, tears, sweat, genital secretions, urine, and feces.^[20] Moreover, Ebola virus was reported in breast milk and genital secretions for a long duration after recovery (13 weeks).^[20,23]

Intact skin represents an immunological defense against infection with Ebola as the virus was reported to enter the body through skin abrasions, mucosal surface breaks, and through contaminated water for parenteral

injection.^[24,25] Laboratory-induced and blood-borne infections (via contaminated needle stick and blood) have been reported in the 1976 outbreaks of Ebola virus in some African countries, for example, Sudan and Zaire.^[26,27]

As for the animal-borne transmission of infection, this was reported to occur through chimpanzees, bats, and nonhuman primates in equatorial Africa and may represent an important source of Ebola virus where reported organ infectivity titers reached 10^7 – 10^8 pfu/g.^[28] The bad nutritional habits of eating the flesh of chimpanzees and freshly killed bats (carriers of Ebola virus) or their slaughtering for food might be related to the emergence of outbreaks in Zaire, Congo, and Gabon. Even contact exposure with infected animals may cause Ebola virus transmission.^[14,15,29] Moreover, undercooking infected animals and exposure to infected blood may enhance the possibility of infection and enhance virus transmission through the oral route as evidenced by the report that Zaire Ebola virus was highly lethal when given orally to rhesus macaques.^[30]

EBOLA PATHOGENESIS

Pathogenesis of Ebola targets mainly the liver, adrenal cortex, lymphatic tissues, and some cells of the immune system causing many pathological effects [Figure 4]. Hemorrhagic fever is a descriptive pathological term for Ebola virus infection. The relatively large size of Ebola viruses may suggest a traumatic vascular injury to explain the origin of Ebola-induced hemorrhagic fever or the causes of inducing the hemorrhagic complications. However, this possibility was reported to be excluded upon vascular histological analysis of different tissues during autopsy.

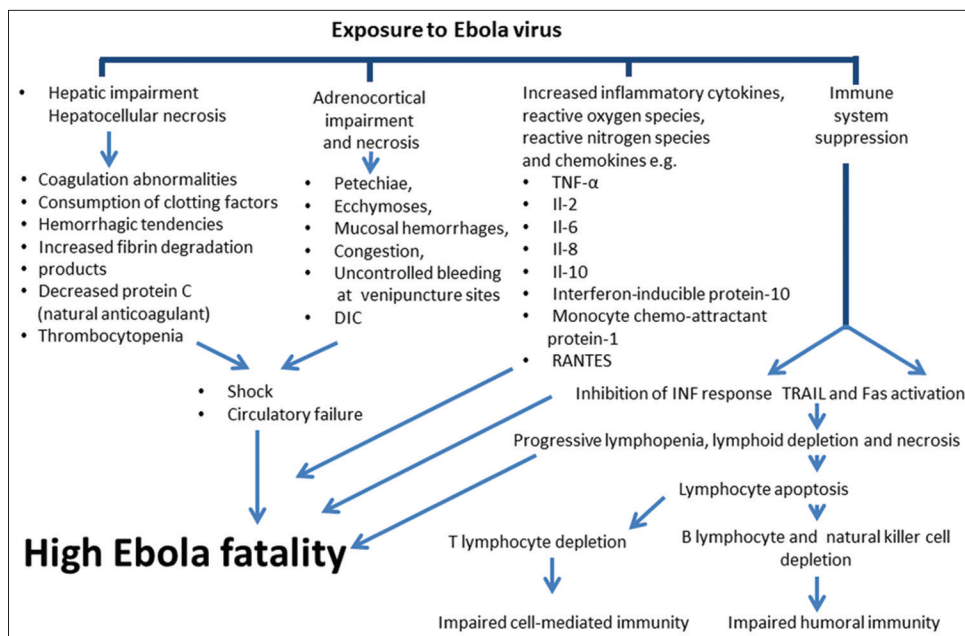


Figure 4: Pathogenesis of Ebola hemorrhagic fever

Lack of evidence for the occurrence of substantial vascular lesions in nonhuman primates infected with Ebola virus was documented in many studies.^[31-33] Interestingly, infection of endothelial cells with Ebola virus in cynomolgus macaques occurred only in the terminal stages of the disease, which excludes vascular injury as a cause for hemorrhagic diathesis occurring during Ebola infection.^[33] Laboratory investigations of Ebola patients presenting with hemorrhagic fever confirmed the presence of coagulation abnormalities (consumption of clotting factors) that manifested clinically as petechiae, ecchymoses, mucosal hemorrhages, congestion, and uncontrolled bleeding at venipuncture sites during Ebola hemorrhagic fever^[34] that is clinically correlated with disseminated intravascular coagulation (DIC).^[35]

Importantly, Ebola-induced marked hepatic impairment and hepatocellular necrosis in both infected patients and nonhuman primates with the secondary disturbance in protein and coagulation factor synthesis might be the underlying factor for the hemorrhagic tendencies, fibrinolysis, consumptive coagulopathy, increased concentrations of fibrin degradation products, and thrombocytopenia causing infrequent blood loss that occurs mainly in the gastrointestinal tract.^[36] Ebola-induced coagulopathy may be due to the expression or release of tissue factors from infected monocytes and macrophages or rapid reductions in serum level of protein C (natural anticoagulant) that were recorded during the course of Zaire Ebola virus infection of cynomolgus monkeys.^[37,38] Moreover, coagulopathy-induced hemorrhages are not large enough to be the underlying cause of death.

Adrenal cortex may be the second affected tissue with Ebola virus where adrenocortical infection and necrosis were reported in patients and nonhuman primates during Ebola virus epidemics, which may explain the fluid and electrolyte disturbances ending in shock and fatal circulatory failure that are usually met with in end-stage infections with Ebola viruses.^[39]

Lymphatic tissues are also affected with Ebola virus infections where lymphoid depletion and necrosis were reported in the spleen, thymus, and lymph nodes of patients with fatal disease and in experimentally infected nonhuman primates^[40] causing impairment of both cell-mediated and humoral immunities. Lymphocyte apoptosis during Ebola virus pathogenesis may be the underlying cause for the progressive lymphopenia and lymphoid depletion^[41,42] and was reported to be due to activation of tumor necrosis factor (TNF)-related apoptosis-inducing ligand and factor of apoptotic signal death receptor pathways.^[19,43] That was evidenced by the premortal depletion of circulating T-lymphocytes and natural killer cell populations in

the serum of patients who died of Ebola during fatal epidemics while in Ebola survivors, lymphocyte cell count did not decrease significantly.^[43] A similar hematological picture was noted in macaques infected with Zaire Ebola virus where the lymphocyte loss seemed to be greatest in T-lymphocytes and natural killer cells.^[19] Moreover, Ebola virus was reported to induce impairment in the dendritic cell function,^[19,43] which may be due to the immunosuppressive motif in the carboxyl-terminal region of the virus glycoproteins causing lymphocyte dysfunction or loss.^[44-47]

Ebola infection causes activation of antigen presenting cells and impairment of the coagulation systems causing multiorgan failure and septic shock. Blood and tissue chemistry may be severely affected by Ebola virus-induced inflammatory processes where released pro-inflammatory cytokines, chemokines, and other mediators (from antigen presenting cells), reactive oxygen, and nitrogen species help in the pathogenesis of Ebola hemorrhagic fever.

Moreover, there is reported increased levels of several inflammatory mediators and cytokines, for example, TNF- α , interleukin (IL)-2, IL-6, IL-8, IL-10, interferon (INF)-inducible protein-10, monocyte chemoattractant protein-1, and regulated upon activation normal T-cell expressed and secreted.^[19,41-42,48] Inhibition of the type-I INF response was also reported during Ebola virus infection.^[49] Interestingly, Ebola virus VP35 was reported to act as a type-I INF antagonist^[50,51] through blocking the activation of INF regulatory factor 3 and preventing the transcription of INF- β .^[50-52] Same INF inhibition was reported for VP24 of the Ebola virus that interferes with type-1 INF signaling.^[50-52]

BIOLOGY OF EBOLA HEMORRHAGIC FEVER

The incubation period of Ebola hemorrhagic fever virus is not long (3–21 days, average 12.7 ± 4.3 days).^[53,54] Bats may be a natural reservoir, which still needs further research confirmation to isolate the virus from bats. Fruit bats (where viral RNA and antibodies were isolated) are resistant to *Filoviridae*.^[14,15,55-59] The newest member of filoviruses (*Lloviucuevavirus*) was discovered in 2010 in Spain and was retrieved from bats.^[60-62]

Seasonal variation in mortality among the African chimpanzees may suggest that climatic changes may affect the Ebola epidemics.^[63,64] A close relationship between the dry conditions at the end of the rainy season was found to correlate with the onset of epidemics, migration of bats,^[14,15] and human contamination^[65] that may induce a change in the behavior of fruit-eating mammals with enhancement in virus circulation.^[66]

CLINICAL PICTURE OF EBOLA VIRAL INFECTION

The main characteristic of Ebola symptomatology includes hematological, lymphatic, and immunological disturbances that should raise a high index of suspicion and should be differentiated from blood diseases. Patients usually present with a flu-like syndrome having fever, chills, abdominal pain, headache, myalgia, malaise, arthralgia, cough, and sore throat with dysphagia. However, hemorrhagic manifestations and complications characterize Ebola and differentiate it from other fevers. Infection with Ebola may present with gastrointestinal bleeding, uncontrolled oozing from venipuncture sites (denoting Ebola complicated with DIC), petechiae, ecchymoses, purpura, epistaxis, gingival bleeding, and mucosal hemorrhages. At autopsy, postmortem evidence of visceral hemorrhagic effusions confirms the cause of death to be Ebola hemorrhagic fever.

A maculopapular rash is a diagnostic sign that later desquamates (at days 5–7) in survivors.^[67-70]

Nonspecific symptoms may make the diagnosis of Ebola hemorrhagic fever difficult, especially at primary health centers. However, nonspecific symptoms should be taken seriously in patients living in endemic areas, travelers to endemic areas, and at times of epidemics. Digestive disorders may be present, for example, nausea, vomiting, anorexia, and diarrhea. Respiratory symptoms may be presenting in the form of nasal discharge, conjunctival injection, postural hypotension, edema, chest pain, shortness of breath, and cough.

Neurological manifestations or complications may be dominating, for example, headache, confusion, and coma. Mortality rate was reported to decrease upon improving the prophylactic measures and decreasing the virus load.^[25,71-76] This is confirmed by data showing that viremia lower than $1 \times 10^{4-5}$ pfu/mL of blood was correlated with improved survival in patients and nonhuman primates infected experimentally.^[77]

LABORATORY DIAGNOSIS OF EBOLA VIRUS

Ebola hemorrhagic fever is often fatal, necessitating its early diagnosis to repress the progress of this vicious disease. However, the nonspecificity of early symptoms and limited laboratory facilities in endemic areas make the diagnosis challenging. A combination of some clinical manifestations in susceptible people should raise the possibility of Ebola infection and guide the laboratory investigations. Presumptive diagnosis includes nonspecific symptoms of fever, myalgia, malaise, headache, gastrointestinal complications, sore throat, and others. Conjunctivitis and maculopapular rashes may also appear. This is followed

by bloody diarrhea, dyspnea due to pulmonary edema, and irritability that progresses to DIC, hepatic and renal dysfunctions, seizures, shock, coma, and eventually death.^[78,79]

Preliminary investigative markers include leucopenia, thrombocytopenia, asthenia, transaminitis (aspartate transaminase and alanine transaminase [ALT]), and elevated levels of blood urea nitrogen. However, these need to be corroborated with specific tests. Laboratory diagnosis is usually made through virus enumeration, serology, nucleic acid tests, or, rarely, viral culture.^[80] Virus or viral particles can be detected in the blood at the onset of infection.

ELISA was the mainstay for diagnosis that detects viral antigen, infectious virus proteins, and virus-specific IgM and IgG antibodies in the serum.^[81] Viral antigenemia could be detected in virtually all the patients using a polyvalent hyperimmune rabbit serum specific for the Ebola subtypes. However, its sensitivity ($\approx 93\%$) in the acute phase of illness wanes thereafter with the disappearance of the antigen. The serum levels of virus-specific IgM and IgG antibodies were detectable at approximately the same time after disease onset (8–10 days), but IgM persisted for a much shorter period than IgG among the surviving convalescent patients. While IgM was measured in a capture assay using modified capture and detection antigens with the polyvalent rabbit serum as the antigen detector. Antihuman IgG (gamma chain specific) was used to detect bound immunoglobulins in IgG ELISA.

Infectious virus isolation though attempted initially (using confluent layers of Vero 6 cells in biosafety level 4 containment facility) has now been discontinued due to the requirement of stringent conditions and slow growth of virus in culture. If the cytopathic effect was observed, the viral cultures were harvested, and antigen was tested using indirect fluorescent antibody test. Fluorescent focus assay (FFA) was also used to enumerate the virus by immunofluorescent staining of infected cells. Attempts to quantify virus by Plaque Assay using neutral red staining were less successful than FFA.

ELISA has been replaced by reverse transcription-polymerase chain reaction (RT-PCR) that is more sensitive to be deployed even in epidemic settings. RT-PCR surveillance of blood, sputum/saliva/throat swabs, conjunctival swabs, stool, urine, semen, and sweat (from axillary, forehead, and inguinal regions) has been reported.^[82] This is a rapid and sensitive technique targeting viral nucleic acid. Viral RNA remained undetectable in saliva, sputum, conjunctival swabs, and stools due to viral RNA shedding. However, urine and sweat samples have been reported to remain positive for viral RNA up to 30–40 days and semen for

3 months. Several RT-PCR kits have now been approved such as RealStar Filovirus Screen RT-PCR Kit 1.0, Altona Diagnostics. The US Food and Drug Administration has also issued authorization on emergency use of Center for Disease Control and Prevention (CDC) Ebola NP real-time RT-PCR assay (<http://www.fda.gov/downloads/MedicalDevices/Safety/EmergencySituations/UCM418810.pdf>).

Ebola virus microRNAs have also been postulated to serve as noninvasive biomarkers for the diagnosis and prognosis of Ebola infection.^[83] Negative tests in patients with putative signs of clinical symptoms warrant repetition of the diagnostic assays.

TREATMENT OF EBOLA INFECTION

Supportive treatment and treatment of complications are of paramount importance. Whole blood transfusions from convalescent patients are needed for the treatment of Ebola hemorrhagic fever. Symptomatic treatments, for example, antihemorrhagic drugs, substitution treatments (including transfusions, plasmapheresis, and dialysis), and resuscitation are highly needed when necessary.^[84] The treatment of complications, for example, hypovolemia, electrolyte abnormalities, hematologic abnormalities, refractory shock, hypoxia, hemorrhage, septic shock, multiorgan failure, and DIC is critical and life-saving. The nematode-derived anticoagulation protein rNAPc2 was an effective treatment of nonhuman primates infected with Zaire Ebola virus.^[85] Effective post-exposure treatment of infection using vesicular stomatitis virus-based Ebola vaccine vector was effective in some animal models.^[86]

SPECIFIC TREATMENT

Ribavirin,^[87,88] antisense oligonucleotides, and RNA interference may be promising based on their efficacy in animal studies.^[28,89,90]

TKM-Ebola is a combination of small interfering RNAs that target Ebola polymerase enzyme, membrane-associated protein (VP24), and the complex protein (VP35). It is designed to block the replication of the Ebola virus. An Ebola nucleoside analog was recently reported to protect against infection with *Filoviridae* through inhibiting the viral polymerase in an animal model.^[91] Favipiravir is an antiviral agent that induces selective inhibition of viral RNA-dependent RNA polymerase without inhibiting RNA or DNA synthesis in mammalian cells. Favipiravir was approved in Japan in 2014 for treating influenza pandemics. It was also reported to have activity against some RNA viruses, for example, influenza viruses.^[92] Lamivudine may be helpful to patients having Ebola hemorrhagic fever. ZMapp is a potential therapeutic

material^[3] that is composed of three chimeric monoclonal antibodies.^[93]

TARGETING EBOLA BIOLOGY AS A FUTURE PERSPECTIVE

Based on our understanding of the key points in Ebola transmission, pathogenesis, and complications, it may be strongly suggested that herbal and prophetic medicine remedies, for example, nigella sativa (NS) may play a role in both prophylaxis and treatment.

NS was reported to exert potent antiviral effects against many viruses, for example, viral hepatitis, coronavirus, and others,^[94] which may suggest its use as a medicinal nutrition or nutritional supplement for treating Ebola virus disease.

NS was reported to possess potent anti-inflammatory effects where its active ingredient thymoquinone suppressed effectively the lipopolysaccharide-induced inflammatory reactions and reduced significantly the concentration of nitric oxide.^[95] Moreover, NS was reported to inhibit the inflammatory processes through suppressing the activities of IL-1, IL-6, nuclear factor- κ B,^[96] IL-1 β , cyclooxygenase-1, prostaglandin-E2, prostaglandin-D2,^[97] cyclooxygenase-2, and TNF- α ^[98] that act as potent inflammatory mediators and were reported to play a major role in the pathogenesis of Ebola virus infection.

Immunostimulating effects of NS include increased natural killer cell activity, increased count, and activity of T helper-1 lymphocytes (immune stimulant effect) versus T-helper-2 (immune suppressive effect). NS suppressed the production of IL-6 and TNF- α .^[99]

All the above-mentioned effects may abolish and antagonize many steps in the pathogenesis of Ebola-induced hepatic impairment, hematological disturbances, and inflammatory reactions, which are responsible for the fatal outcomes in Ebola virus infection.

Moreover, many hepatoprotective effects of NS were recently reported. NS was reported to exert many hepatoprotective effects against ischemia-reperfusion injury where NS treatment restored the serum level of liver enzymes (ALT, aspartate aminotransferase, and lactate dehydrogenase), reduced oxidative stress index, and enhanced the total antioxidant capacity to near normal values.^[100]

Financial support and sponsorship

This article is supported by the deanship of scientific research in Taibah University, Saudi Arabia.

Conflicts of interest

The authors have no conflicts of interest.

AUTHORS' CONTRIBUTION

SME: Drafted the article and figures, shared in the article preparation, and approved the submission. AAA: Prepared the biology part, shared in the article design, and approved the submission. HAO: Wrote the diagnosis section, shared in the article preparation, and approved the submission. HAH: Prepared epidemiology and transmission sections, shared in the article preparation, and approved the submission. AMK: Wrote Ebola virology, shared in the article preparation, revised the article, and approved the submission. NR: Prepared the treatment section, shared in the article preparation, revised the article, and approved the submission. MBE: Shared in the article preparation, revised the article, wrote the abstract, and approved the submission. MMHN: Prepared the pathogenesis section, shared in the article preparation, and approved the submission. YFM: Critically reviewed the article, added important parts in the body of the article, and approved the submission. SME, AAA, HAO, HAH, AMK, MMHN, MBE, and YMF are the abbreviations for the names of the authors as enlisted in the author list section.

REFERENCES

- Hartman AL, Bird BH, Towner JS, Antoniadou ZA, Zaki SR, Nichol ST. Inhibition of IRF-3 activation by VP35 is critical for the high level of virulence of *Ebola virus*. *J Virol* 2008;82:2699-704.
- Wauquier N, Becquart P, Padilla C, Baize S, Leroy EM. Human fatal zaire *Ebola virus* infection is associated with an aberrant innate immunity and with massive lymphocyte apoptosis. *PLoS Negl Trop Dis* 2010;4. pii: E837.
- Choi WY, Hong KJ, Hong JE, Lee WJ. Progress of vaccine and drug development for Ebola preparedness. *Clin Exp Vaccine Res* 2015;4:11-6.
- WHO Ebola Response Team. *Ebola virus* disease in West Africa – The first 9 months of the epidemic and forward projections. *N Engl J Med* 2014;371:1481-95.
- Chippaux JP. Outbreaks of *Ebola virus* disease in Africa: The beginnings of a tragic saga. *J Venom Anim Toxins Incl Trop Dis* 2014;20:44.
- Ascenzi P, Bocedi A, Heptonstall J, Capobianchi MR, Di Caro A, Mastrangelo E, et al. Ebolavirus and marburgvirus: Insight into the filoviridae family. *Mol Aspects Med* 2008;29:151-85.
- Feldmann H, Geisbert TW. Ebola haemorrhagic fever. *Lancet* 2011;377:849-62.
- Groseth A, Marzi A, Hoenen T, Herwig A, Gardner D, Becker S, et al. The *Ebola virus* glycoprotein contributes to but is not sufficient for virulence *in vivo*. *PLoS Pathog* 2012;8:e1002847.
- Feldmann H, Jones SM, Schnittler HJ, Geisbert T. Therapy and prophylaxis of *Ebola virus* infections. *Curr Opin Investig Drugs* 2005;6:823-30.
- Sanchez A, Geisbert TW, Feldmann H. Filoviridae: Marburg and *Ebola viruses*. In: Knipe DM, Howley PM, editors. *Fields Virology*. Philadelphia: Lippincott Williams and Wilkins; 2006. p. 1409-48.
- Siegert R, Shu HL, Slenczka W, Peters D, Müller G. On the etiology of an unknown human infection originating from monkeys. *Dtsch Med Wochenschr* 1967;92:2341-3.
- Barrette RW, Metwally SA, Rowland JM, Xu L, Zaki SR, Nichol ST, et al. Discovery of swine as a host for the *Reston ebolavirus*. *Science* 2009;325:204-6.
- Groseth A, Feldmann H, Strong JE. The ecology of *Ebola virus*. *Trends Microbiol* 2007;15:408-16.
- Leroy EM, Epelboin A, Mondonge V, Pourrut X, Gonzalez JP, Muyembe-Tamfum JJ, et al. Human Ebola outbreak resulting from direct exposure to fruit bats in Luebo, Democratic Republic of Congo, 2007. *Vector Borne Zoonotic Dis* 2009;9:723-8.
- Leroy EM, Kumulungui B, Pourrut X, Rouquet P, Hassanin A, Yaba P, et al. Fruit bats as reservoirs of *Ebola virus*. *Nature* 2005;438:575-6.
- Pourrut X, Délicat A, Rollin PE, Ksiazek TG, Gonzalez JP, Leroy EM. Spatial and temporal patterns of *Zaire ebolavirus* antibody prevalence in the possible reservoir bat species. *J Infect Dis* 2007;196 Suppl 2:S176-83.
- Towner JS, Amman BR, Sealy TK, Carroll SA, Comer JA, Kemp A, et al. Isolation of genetically diverse Marburg viruses from Egyptian fruit bats. *PLoS Pathog* 2009;5:e1000536.
- Swanepoel R, Leman PA, Burt FJ, Zachariades NA, Braack LE, Ksiazek TG, et al. Experimental inoculation of plants and animals with *Ebola virus*. *Emerg Infect Dis* 1996;2:321-5.
- Geisbert TW, Hensley LE, Larsen T, Young HA, Reed DS, Geisbert JB, et al. Pathogenesis of Ebola hemorrhagic fever in cynomolgus macaques: Evidence that dendritic cells are early and sustained targets of infection. *Am J Pathol* 2003;163:2347-70.
- Bausch DG, Towner JS, Dowell SF, Kaducu F, Lukwiya M, Sanchez A, et al. Assessment of the risk of *Ebola virus* transmission from bodily fluids and fomites. *J Infect Dis* 2007;196 Suppl 2:S142-7.
- Hewlett BS, Amola RP. Cultural contexts of Ebola in Northern Uganda. *Emerg Infect Dis* 2003;9:1242-8.
- Hewlett BS, Epelboin A, Hewlett BL, Formenty P. Medical anthropology and Ebola in Congo: Cultural models and humanistic care. *Bull Soc Pathol Exot* 2005;98:230-6.
- Kibadi K, Mupapa K, Kuvula K, Massamba M, Ndaberey D, Muyembe-Tamfum JJ, et al. Late ophthalmologic manifestations in survivors of the 1995 *Ebola virus* epidemic in Kikwit, Democratic Republic of the Congo. *J Infect Dis* 1999;179 Suppl 1:S13-4.
- Dowell SF, Mukunu R, Ksiazek TG, Khan AS, Rollin PE, Peters CJ. Transmission of Ebola hemorrhagic fever: A study of risk factors in family members, Kikwit, Democratic Republic of the Congo, 1995. *Commission de Lutte contre les Epidémies à Kikwit. J Infect Dis* 1999;179 Suppl 1:S87-91.
- Khan AS, Tshioko FK, Heymann DL, Le Guenno B, Nabeth P, Kerstiens B, et al. The reemergence of Ebola hemorrhagic fever, Democratic Republic of the Congo, 1995. *Commission de Lutte contre les Epidémies à Kikwit. J Infect Dis* 1999;179 Suppl 1:S76-86.
- Ebola haemorrhagic fever in Sudan, 1976. Report of a WHO/International study team. *Bull World Health Organ* 1978;56:247-70.
- Ebola haemorrhagic fever in Zaire, 1976. *Bull World Health Organ* 1978;56:271-93.
- Geisbert TW, Lee AC, Robbins M, Geisbert JB, Honko AN, Sood V, et al. Postexposure protection of non-human primates against a lethal *Ebola virus* challenge with RNA interference: A proof-of-concept study. *Lancet* 2010;375:1896-905.
- Georges-Courbot MC, Sanchez A, Lu CY, Baize S, Leroy E, Lansout-Soukate J, et al. Isolation and phylogenetic characterization of *Ebola viruses* causing different outbreaks in Gabon. *Emerg Infect Dis* 1997;3:59-62.
- Jaax NK, Davis KJ, Geisbert TJ, Vogel P, Jaax GP, Topper M,

- et al.* Lethal experimental infection of rhesus monkeys with Ebola-Zaire (Mayinga) virus by the oral and conjunctival route of exposure. *Arch Pathol Lab Med* 1996;120:140-55.
31. Ryabchikova EI, Kolesnikova LV, Luchko SV. An analysis of features of pathogenesis in two animal models of *Ebola virus* infection. *J Infect Dis* 1999;179 Suppl 1:S199-202.
 32. Baskerville A, Fisher-Hoch SP, Neild GH, Dowsett AB. Ultrastructural pathology of experimental Ebola haemorrhagic fever virus infection. *J Pathol* 1985;147:199-209.
 33. Geisbert TW, Young HA, Jahrling PB, Davis KJ, Kagan E, Hensley LE. Mechanisms underlying coagulation abnormalities in Ebola hemorrhagic fever: Overexpression of tissue factor in primate monocytes/macrophages is a key event. *J Infect Dis* 2003;188:1618-29.
 34. Isaäcson M. Viral hemorrhagic fever hazards for travelers in Africa. *Clin Infect Dis* 2001;33:1707-12.
 35. Levi M. Disseminated intravascular coagulation. *Crit Care Med* 2007;35:2191-5.
 36. Murphy FA. Pathogenesis of *Ebola virus* infection. In: Pattyn SR, editor. *Ebola Virus Haemorrhagic Fever*. Amsterdam: Elsevier/ North-Holland; 1978. p. 43-59.
 37. Reed DS, Hensley LE, Geisbert JB, Jahrling PB, Geisbert TW. Depletion of peripheral blood T lymphocytes and NK cells during the course of ebola hemorrhagic Fever in cynomolgus macaques. *Viral Immunol* 2004;17:390-400.
 38. Geisbert TW, Young HA, Jahrling PB, Davis KJ, Larsen T, Kagan E, *et al.* Pathogenesis of Ebola hemorrhagic fever in primate models: Evidence that hemorrhage is not a direct effect of virus-induced cytolysis of endothelial cells. *Am J Pathol* 2003;163:2371-82.
 39. Geisbert TW, Jaax NK. Marburg hemorrhagic fever: Report of a case studied by immunohistochemistry and electron microscopy. *Ultrastruct Pathol* 1998;22:3-17.
 40. Zaki SR, Goldsmith CS. Pathologic features of filovirus infections in humans. *Curr Top Microbiol Immunol* 1999;235:97-116.
 41. Baize S, Leroy EM, Mavoungou E, Fisher-Hoch SP. Apoptosis in fatal Ebola infection. Does the virus toll the bell for immune system? *Apoptosis* 2000;5:5-7.
 42. Baize S, Leroy EM, Georges-Courbot MC, Capron M, Lansoud-Soukate J, Debré P, *et al.* Defective humoral responses and extensive intravascular apoptosis are associated with fatal outcome in *Ebola virus*-infected patients. *Nat Med* 1999;5:423-6.
 43. Bosio CM, Aman MJ, Grogan C, Hogan R, Ruthel G, Negley D, *et al.* Ebola and Marburg viruses replicate in monocyte-derived dendritic cells without inducing the production of cytokines and full maturation. *J Infect Dis* 2003;188:1630-8.
 44. Sanchez A, Lukwiya M, Bausch D, Mahanty S, Sanchez AJ, Wagoner KD, Rollin PE. Analysis of human peripheral blood samples from fatal and nonfatal cases of Ebola (Sudan) hemorrhagic fever: Cellular responses, virus load, and nitric oxide levels. *J Virol* 2004;78:10370-7.
 45. Yaddanapudi K, Palacios G, Towner JS, Chen I, Sariol CA, Nichol ST, *et al.* Implication of a retrovirus-like glycoprotein peptide in the immunopathogenesis of Ebola and Marburg viruses. *FASEB J* 2006;20:2519-30.
 46. Volchkov VE, Blinov VM, Netesov SV. The envelope glycoprotein of *Ebola virus* contains an immunosuppressive-like domain similar to oncogenic retroviruses. *FEBS Lett* 1992;305:181-4.
 47. Chepurnov AA, Tuzova MN, Ternovoy VA, Chernukhin IV. Suppressive effect of *Ebola virus* on T cell proliferation *in vitro* is provided by a 125-kDa GP viral protein. *Immunol Lett* 1999;68:257-61.
 48. Villinger F, Rollin PE, Brar SS, Chikkala NF, Winter J, Sundstrom JB, *et al.* Markedly elevated levels of interferon (IFN)-gamma, IFN-alpha, interleukin (IL)-2, IL-10, and tumor necrosis factor-alpha associated with fatal *Ebola virus* infection. *J Infect Dis* 1999;179 Suppl 1:S188-91.
 49. Harcourt BH, Sanchez A, Offermann MK. *Ebola virus* selectively inhibits responses to interferons, but not to interleukin-1beta, in endothelial cells. *J Virol* 1999;73:3491-6.
 50. Basler CF, Wang X, Mühlberger E, Volchkov V, Paragas J, Klenk HD, *et al.* The *Ebola virus* VP35 protein functions as a type I IFN antagonist. *Proc Natl Acad Sci U S A* 2000;97:12289-94.
 51. Basler CF, Mikulasova A, Martinez-Sobrido L, Paragas J, Mühlberger E, Bray M, *et al.* The *Ebola virus* VP35 protein inhibits activation of interferon regulatory factor 3. *J Virol* 2003;77:7945-56.
 52. Reid SP, Leung LW, Hartman AL, Martinez O, Shaw ML, Carbonnelle C, *et al.* *Ebola virus* VP24 binds karyopherin alpha1 and blocks STAT1 nuclear accumulation. *J Virol* 2006;80:5156-67.
 53. Okware SI, Omaswa FG, Zaramba S, Opio A, Lutwama JJ, Kamugisha J, *et al.* An outbreak of Ebola in Uganda. *Trop Med Int Health* 2002;7:1068-75.
 54. Eichner M, Dowell SF, Firese N. Incubation period of ebola hemorrhagic virus subtype zaire. *Osong Public Health Res Perspect* 2011;2:3-7.
 55. Pourrut X, Kumulungui B, Wittmann T, Moussavou G, Délicat A, Yaba P, *et al.* The natural history of *Ebola virus* in Africa. *Microbes Infect* 2005;7:1005-14.
 56. Olival KJ, Islam A, Yu M, Anthony SJ, Epstein JH, Khan SA, *et al.* Ebola virus antibodies in fruit bats, bangladesh. *Emerg Infect Dis*. 2013;19:270-3.
 57. Pourrut X, Souris M, Towner JS, Rollin PE, Nichol ST, Gonzalez JP, *et al.* Large serological survey showing cocirculation of Ebola and Marburg viruses in Gabonese bat populations, and a high seroprevalence of both viruses in *Rousettus aegyptiacus*. *BMC Infect Dis* 2009;9:159.
 58. Hayman DT, Emmerich P, Yu M, Wang LF, Suu-Ire R, Fooks AR, *et al.* Long-term survival of an urban fruit bat seropositive for Ebola and Lagos bat viruses. *PLoS One* 2010;5:e11978.
 59. Hayman DT, Yu M, Crameri G, Wang LF, Suu-Ire R, Wood JL, *et al.* *Ebola virus* antibodies in fruit bats, Ghana, West Africa. *Emerg Infect Dis* 2012;18:1207-9.
 60. Smith CE, Simpson DI, Bowen ET, Zlotnik I. Fatal human disease from vervet monkeys. *Lancet* 1967;2:1119-21.
 61. Negredo A, Palacios G, Vázquez-Morón S, González F, Dopazo H, Molero F, *et al.* Discovery of an ebolavirus-like filovirus in europe. *PLoS Pathog* 2011;7:e1002304.
 62. Kuhn JH, Bào Y, Bavari S, Becker S, Bradfute S, Brauburger K, *et al.* Virus nomenclature below the species level: A standardized nomenclature for filovirus strains and variants rescued from cDNA. *Arch Virol* 2014;159:1229-37.
 63. Formenty P, Boesch C, Wyers M, Steiner C, Donati F, Dind F, *et al.* *Ebola virus* outbreak among wild chimpanzees living in a rain forest of Côte d'Ivoire. *J Infect Dis* 1999;179 Suppl 1:S120-6.
 64. Johnson BK, Wambui C, Ocheng D, Gichogo A, Oogo S, Libondo D, *et al.* Seasonal variation in antibodies against *Ebola virus* in Kenyan fever patients. *Lancet* 1986;1:1160.
 65. Pinzon JE, Wilson JM, Tucker CJ, Arthur R, Jahrling PB, Formenty P. Trigger events: Enviroclimatic coupling of Ebola hemorrhagic fever outbreaks. *Am J Trop Med Hyg* 2004;71:664-74.
 66. Gautier-Hion A, Michaloud G. Are figs always keystone resources for tropical frugivorous vertebrates? A test in Gabon. *Ecology* 1989;70:1826-33.
 67. Pattyn SR. The epidemic of hemorrhagic fever in Zaire (August-November 1976) and its implications. *Verh K Acad Geneesk Belg* 1983;45:201-25.
 68. Pattyn, SR. *Ebola virus haemorrhagic fever*. Amsterdam, North-Holland: Elsevier; 1978.

69. Peters CJ, LeDuc LW. Ebola: The virus and the disease. *J Infect Dis* 1999;179 Suppl 1:S1-288.
70. Feldmann H, Geisbert T, Kawaoka Y. Filoviruses: Recent advances and future challenges. *J Infect Dis* 2007;196 Suppl 2:S129-30.
71. Baron RC, McCormick JB, Zubeir OA. *Ebola virus* disease in Southern Sudan: Hospital dissemination and intrafamilial spread. *Bull World Health Organ* 1983;61:997-1003.
72. Carod-Artal FJ. Illness due the Ebola virus: Epidemiology and clinical manifestations within the context of an international public health emergency. *Rev Neurol* 2015;60:267-77.
73. Report of an International Commission. Ebola haemorrhagic fever in Zaire, 1976. *Bull World Health Organ* 1978;56:271-93.
74. Bwaka MA, Bonnet MJ, Calain P, Colebunders R, De Roo A, Guimard Y, *et al.* Ebola hemorrhagic fever in Kikwit, Democratic Republic of the Congo: Clinical observations in 103 patients. *J Infect Dis* 1999;179 Suppl 1:S1-7.
75. MacNeil A, Farnon EC, Wamala J, Okware S, Cannon DL, Reed Z, *et al.* Proportion of deaths and clinical features in Bundibugyo *Ebola virus* infection, Uganda. *Emerg Infect Dis* 2010;16:1969-72.
76. Roddy P, Howard N, Van Kerkhove MD, Lutwama J, Wamala J, Yoti Z, *et al.* Clinical manifestations and case management of Ebola haemorrhagic fever caused by a newly identified virus strain, Bundibugyo, Uganda, 2007-2008. *PLoS One* 2012;7:e52986.
77. Hensley LE, Stevens EL, Yan SB, Geisbert JB, Macias WL, Larsen T, *et al.* Recombinant human activated protein C for the postexposure treatment of Ebola hemorrhagic fever. *J Infect Dis* 2007;196 Suppl 2:S390-9.
78. Fhogartaigh CN, Aarons E. Viral haemorrhagic fever. *Clin Med (Lond)* 2015;15:61-6.
79. Barry M, Traoré FA, Sako FB, Kpamy DO, Bah EI, Poncin M, *et al.* Ebola outbreak in Conakry, Guinea: Epidemiological, clinical, and outcome features. *Med Mal Infect* 2014;44:491-4.
80. Martin P, Laupland KB, Frost EH, Valiquette L. Laboratory diagnosis of *Ebola virus* disease. *Intensive Care Med* 2015;41:895-8.
81. Ksiazek TG, Rollin PE, Williams AJ, Bressler DS, Martin ML, Swanepoel R, *et al.* Clinical virology of Ebola hemorrhagic fever (EHF): Virus, virus antigen, and IgG and IgM antibody findings among EHF patients in Kikwit, Democratic Republic of the Congo, 1995. *J Infect Dis* 1999;179 Suppl 1:S177-87.
82. Kreuels B, Wichmann D, Emmerich P, Schmidt-Chanasit J, de Heer G, Kluge S, *et al.* A case of severe *Ebola virus* infection complicated by gram-negative septicemia. *N Engl J Med* 2014;371:2394-401.
83. Liang H, Zhou Z, Zhang S, Zen K, Chen X, Zhang C. Identification of *Ebola virus* microRNAs and their putative pathological function. *Sci China Life Sci* 2014;57:973-81.
84. Clark DV, Jahrling PB, Lawler JV. Clinical management of filovirus-infected patients. *Viruses* 2012;4:1668-86.
85. Geisbert TW, Hensley LE, Jahrling PB, Larsen T, Geisbert JB, Paragas J, *et al.* Treatment of *Ebola virus* infection with a recombinant inhibitor of factor VIIa/tissue factor: A study in rhesus monkeys. *Lancet* 2003;362:1953-8.
86. Feldmann H, Jones SM, Daddario-DiCaprio KM, Geisbert JB, Ströher U, Grolla A, *et al.* Effective post-exposure treatment of Ebola infection. *PLoS Pathog* 2007;3:e2.
87. Huggins JW. Prospects for treatment of viral hemorrhagic fevers with ribavirin, a broad-spectrum antiviral drug. *Rev Infect Dis* 1989;11 Suppl 4:S750-61.
88. Ignatyev G, Steinkasserer A, Streltsova M, Atrasheuskaya A, Agafonov A, Lubitz W. Experimental study on the possibility of treatment of some hemorrhagic fevers. *J Biotechnol* 2000;83:67-76.
89. Geisbert TW, Hensley LE, Kagan E, Yu EZ, Geisbert JB, Daddario-DiCaprio K, *et al.* Postexposure protection of guinea pigs against a lethal *Ebola virus* challenge is conferred by RNA interference. *J Infect Dis* 2006;193:1650-7.
90. Warfield KL, Swenson DL, Olinger GG, Nichols DK, Pratt WD, Blouch R, *et al.* Gene-specific countermeasures against *Ebola virus* based on antisense phosphorodiamidate morpholino oligomers. *PLoS Pathog* 2006;2:e1.
91. Warren TK, Wells J, Panchal RG, Stuthman KS, Garza NL, Van Tongeren SA, *et al.* Protection against filovirus diseases by a novel broad-spectrum nucleoside analogue BCX4430. *Nature* 2014;508:402-5.
92. Furuta Y, Gowen BB, Takahashi K, Shiraki K, Smee DF, Barnard DL. Favipiravir (T-705), a novel viral RNA polymerase inhibitor. *Antiviral Res* 2013;100:446-54.
93. Zhang Y, Li D, Jin X, Huang Z. Fighting Ebola with ZMapp: Spotlight on plant-made antibody. *Sci China Life Sci* 2014;57:987-8.
94. Ahmad A, Husain A, Mujeeb M, Khan SA, Najmi AK, Siddique NA, *et al.* A review on therapeutic potential of *Nigella sativa*: A miracle herb. *Asian Pac J Trop Biomed* 2013;3:337-52.
95. Alemi M, Sabouni F, Sanjarian F, Haghbeen K, Ansari S. Anti-inflammatory effect of seeds and callus of *Nigella sativa* L. extracts on mix glial cells with regard to their thymoquinone content. *AAPS PharmSciTech* 2013;14:160-7.
96. Shuid AN, Mohamed N, Mohamed IN, Othman F, Suhaimi F, Mohd Ramli ES, *et al.* *Nigella sativa*: A potential antiosteoporotic agent. *Evid Based Complement Alternat Med* 2012;2012:696230.
97. El Mezayen R, El Gazzar M, Nicolls MR, Marecki JC, Dreskin SC, Nomiya H. Effect of thymoquinone on cyclooxygenase expression and prostaglandin production in a mouse model of allergic airway inflammation. *Immunol Lett* 2006;106:72-81.
98. Chehl N, Chipitsyna G, Gong Q, Yeo CJ, Arafat HA. Anti-inflammatory effects of the *Nigella sativa* seed extract, thymoquinone, in pancreatic cancer cells. *HPB (Oxford)* 2009;11:373-81.
99. Majdalawieh AF, Hmaidan R, Carr RI. *Nigella sativa* modulates splenocyte proliferation, Th1/Th2 cytokine profile, macrophage function and NK anti-tumor activity. *J Ethnopharmacol* 2010;131:268-75.
100. Yildiz F, Coban S, Terzi A, Ates M, Aksoy N, Cakir H, *et al.* *Nigella sativa* relieves the deleterious effects of ischemia reperfusion injury on liver. *World J Gastroenterol* 2008;14:5204-9.