

A bilobed testicle diagnosed with ultrasound in an 18-year-old boy

Farzaneh Hekmatnia, Mohammad Momeni¹, Ali Hekmatnia¹, Mohammad Mehdi Baradaran Mahdavi¹

Department of Medicine, St. George Medical School, University of London, London, UK, ¹Department of Radiology and Imaging, Isfahan University of Medical Sciences, Isfahan, Iran

Bilobed testicle is a very rare congenital malformation with an unknown etiology. Herein, we report an 18-year-old boy presented with a right-bilobed testicle mimicking a testicular tumor. The present case highlights the importance of considering bilobed testicle as a valuable differential diagnosis of testicular mass to prevent unnecessary surgery. Furthermore, the case could provide more information about presentation and management of bilobed testicle.

Key words: Bilobed, testicle, ultrasound

How to cite this article: Hekmatnia F, Momeni M, Hekmatnia A, Baradaran Mahdavi MM. A bilobed testicle diagnosed with ultrasound in an 18-year-old boy. *J Res Med Sci* 2016;21:62.

INTRODUCTION

Bilobed testicle is an uncommon congenital malformation. Six cases have been reported in the literature till date.^[1-6]

The etiology of bilobed testicle is poorly understood, but it may be presumed that this malformation is an incomplete type of polyorchidism.^[3]

Incomplete division of the genital ridge by peritoneal band is currently accepted as the possible mechanism of bilobed testicle. Complete division of genital ridge results in a condition known as polyorchidism. In comparison with bilobed testicle, polyorchidism is more common with approximately 100 cases reported in the literature. Polyorchidism has been associated with several pathologies such as malignancy, torsion, and inguinal hernia. Meanwhile, bilobed testicle considered as a benign condition according to the previous studies. However, lack of studies with long-term follow-up of cases and paucity of cases make it difficult to judge about bilobed testicle long-term outcome.^[3]

Herein, we present our experience with an 18-year-old male in whom a bilobed testicle diagnosed with ultrasound.

CASE REPORT

An 18-year-old boy referred to our hospital, Isfahan, Iran, in 2015 for a scrotal ultrasound study due to an incidental finding of a right testis mass during the postsurgical routine physical examination. He was otherwise healthy, with no family history of urological disorder. His history was remarkable for a congenital urethral stricture which was corrected surgically 3 months before the presentation.

The patient had no complaint of scrotal discomfort, erythema, or edema. On physical examination, a well-defined smooth mass was palpated in inferior pole of the right testis. The rest of the physical examination was unremarkable. Ultrasound revealed a well-defined mass measuring 20 mm × 16 mm × 16 mm, attached to the inferior pole of the right testicle by a deep transverse cleft [Figure 1]. The mass had a similar echotexture with normal adjacent testis. Color Doppler ultrasound also showed a normal centripetal vascularity in the mass

This is an open access article distributed under the terms of the Creative Commons Attribution-NonCommercial-ShareAlike 3.0 License, which allows others to remix, tweak, and build upon the work non-commercially, as long as the author is credited and the new creations are licensed under the identical terms.

For reprints contact: reprints@medknow.com

Access this article online

Quick Response Code:



Website:

www.jmsjournal.net

DOI:

10.4103/1735-1995.187337

Address for correspondence: Dr. Mohammad Momeni, Department of Radiology and Imaging, Isfahan University of Medical Sciences, Isfahan, Iran. E-mail: Dr.m.momeni@gmail.com

Received: 30-12-2015; **Revised:** 17-04-2016; **Accepted:** 02-05-2016

similar to the rest of the testicle [Figure 2]. Both testicles were of a similar size, with normal vascularity and normal-appearing epididymis in the ultrasound study. According to the ultrasound features, the differential diagnosis included bilobed testicle, polyorchidism, and intratesticular mass. With suspicious of a bilobed testicle, a magnetic resonance imaging (MRI) of the testis was performed. MRI showed a mass with the same signal features as the normal testicles and confirmed the diagnosis of bilobed testicle [Figure 3]. The patient was educated on the signs and symptoms of testicular torsion to report early if suspected, and a 6- and 12-month follow-up with physical examination and ultrasound were arranged for the patient. The patient is well, currently without any scrotal discomfort. The last ultrasound revealed no changes in the imaging characteristics.

DISCUSSION

Polyorchidism has been associated with several pathologies such as malignancy, torsion, and inguinal hernia. Meanwhile, bilobed testicle considered as a benign condition according to the previous studies. According to the previous studies, the risk of torsion in supernumerary testicles is 15% in comparison with 0.025% of the general population and 0.25% in cryptorchidism. However, out of the six cases of bilobed testicle reported in the literature, only one presented with testicular torsion and underwent orchiectomy. Therefore, patients should be made aware of the risks associated with bilobed testicle and educated on the signs and symptoms of testicular torsion to report early if suspected.^[3]

Considering the differences in presentation between bilobed testicle and polyorchidism, it is important to distinguish between the two entities. The main distinguishing feature is that in polyorchidism, the supernumerary testicle is much smaller than the main testicle.^[4]

Ultrasound and MRI are useful for diagnosis of this anomaly. Radiographic findings include a lobulated testis with normal echotexture, and the hemi-testicular structure is similar to the rest of the testis. There is a shallow cleft between two parts of the testis that resembles the cleavage furrow during cytokinesis in cell division^[5] and could be named as “cleavage furrow sign.”

There are no data in the literature regarding the long-term care of bilobed testicle. Polyorchidism is much more common in comparison to bilobed testicle, and due to the similarities in etiology, we rely on the literature for decisions regarding the management of bilobed testicle. Surgical management is not routine even with the suspected increased risk of malignancy in association with bilobed testicle. Thus, if uncomplicated, surgery is not required in bilobed testicle in contrast to cryptorchidism.^[3,6]

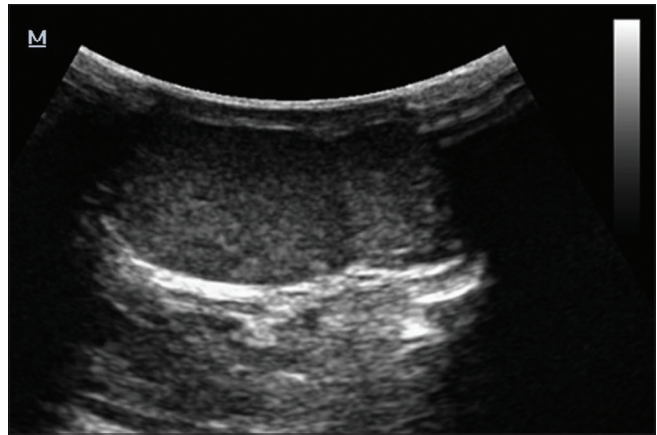


Figure 1: Ultrasound demonstrates a right bilobed testicle

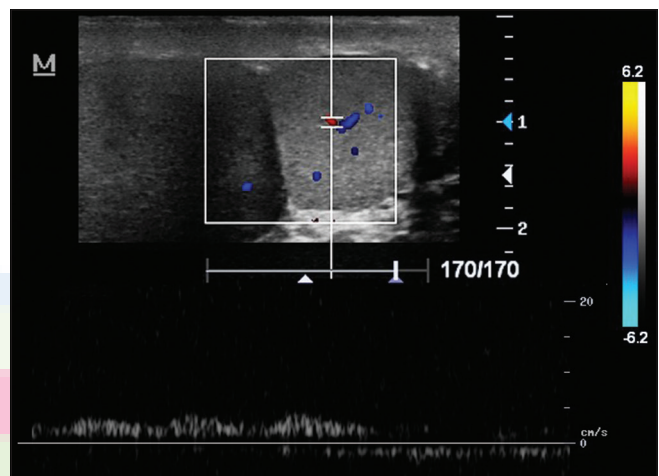


Figure 2: Color Doppler ultrasound shows a normal vascularity in the mass similar to the normal adjacent testis

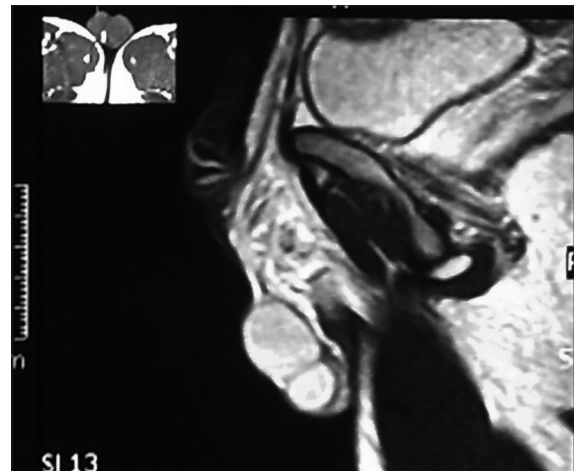


Figure 3: Sagittal T2-weighted image showed a mass with the same signal features as the normal testicles

Regular follow-up appointments at the hospital create excessive concern for the patients and their family. If the patient experiences no change during 12 months after diagnosis, he/she may be discharged to primary care. Regular

self-examination should be taught and recommended even though it may be difficult due to the anatomy. If there is ever any suspicion or concern of change, ultrasound should be carried out. Unlike polyorchidism, monitoring tumor markers is not indicated in bilobed testicles as the risk of malignancy is not as high in comparison and there are no indications in the literature supporting this.^[3,7]

Our patient was fit and well on presentation and remained asymptomatic during follow-up. The only positive sign on investigation was a well-defined smooth mass which was palpated in the inferior pole of the right testis. His ultrasound studies showed no change, and therefore, no surgical intervention was indicated. The presentation our case confirms that bilobed testicle is a benign malformation and conservative management may be appropriate in uncomplicated cases such as our case.

Financial support and sponsorship

Nil.

Conflicts of interest

There are no conflicts of interest.

AUTHORS' CONTRIBUTION

AH contributed to the conception of the work, conducting the study, revising the draft, approval of the final version

of the manuscript, and agreed for all aspects of the work. MM contributed to the conception of the work, drafting and revising the draft, approval of the final version of the manuscript, and agreed for all aspects of the work. FH contributed to the conception of the work, drafting and revising the draft, approval of the final version of the manuscript, and agreed for all aspects of the work. MB contributed to the conception of the work, drafting and revising the draft, approval of the final version of the manuscript, and agreed for all aspects of the work.

REFERENCES

1. Beiko D, Macneily AE. Torsion of bilobed testis and biopsy-proven ipsilateral supernumerary testis in an adolescent. *Can Urol Assoc J* 2010;4:E67-70.
2. De Carli C, Guerra L, Leonard M. Bilobed testicle in children: Diagnosis and management. *Can Urol Assoc J* 2009;3:E87-8.
3. Halliday LJ. Management of a bilobed testicle in a 12-year-old boy. *J Surg Case Rep* 2013;2013. pii: Rjt112.
4. Hamdan A, Abdulla A, Yousef M. Evaluation of testicular disease using ultrasound. *Int J* 2013;2:12-9.
5. Shuster CB, Burgess DR. Targeted new membrane addition in the cleavage furrow is a late, separate event in cytokinesis. *Proc Natl Acad Sci U S A* 2002;99:3633-8.
6. McAlister WH, Manley CB. Bilobed testicle. *Pediatr Radiol* 1987;17:82.
7. Méndez-Gallart R, Estevez-Martínez E, Rodríguez-Barca P, García-Palacios M, Bautista-Casasnovas A. Incomplete unilateral polyorchidism (bilobed testicle) mimicking testicular tumour. *J Pediatr Surg* 2012;47:2140-2.

