

Arnebia euchroma ointment can reduce abdominal fat thickness and abdominal circumference of overweight women: A randomized controlled study

Mansour Siavash, Mohsen Naseri¹, Mojgan Rahimi²

Endocrine and Metabolism Research Center, Isfahan University of Medical Sciences, ²Department of Internal Medicine, Isfahan University of Medical Sciences, Isfahan, ¹Traditional Medicine Clinical Trial Research Center, Shahed University, Tehran, Iran

Background: Obesity is a worldwide health problem which is associated with a lot of complications. One of these comorbidities is the metabolic syndrome that is in correlation with abdominal fat thickness and waist circumference. Various methods were used to reduce abdominal fat thickness such as liposuction. A noninvasive method is the topical agent. In this study, we investigated the effectiveness of *Arnebia euchroma* (AE) ointment on the abdominal fat thickness. **Materials and Methods:** This study was a double-blind clinical trial which was done at the endocrinology clinic in Khorshid Hospital, Isfahan, Iran, in 2014. After explaining the procedure and obtaining informed consent, the candidates were randomly divided into the case and control groups. The participants of the case and control groups applied AE ointment or placebo for 6 weeks on their abdominal area. Body mass index, waist and buttock circumference, and abdominal fat thickness were measured in both case and control groups at their first visit and then at the next 2, 4, and 6 weeks. We used *t*-test for comparing parametric variables between groups, paired *t*-test for changes from baseline to final, and repeated measure ANOVA for changes at different steps. **Results:** Sixty female candidates participated in this study (thirty in each group). Ten patients left the study and fifty participants finished the trial. At the end of the study, participants had a significant weight loss (2.96 ± 1.6 kg, $P < 0.001$) that was slightly more in the case group (3.15 ± 1.5 kg vs. 2.75 ± 1.7 , $P = 0.375$). Abdominal circumference also decreased significantly in the participants (11.3 ± 6.7 cm, $P < 0.001$), but the changes were more significant in the case group (13.9 vs. 6.5 cm, $P = 0.004$). Similarly, abdominal fat thickness decreased significantly in the participants (2.3 ± 1.1 cm, $P < 0.001$), although changes were not significantly different between two groups (2.53 vs. 2.04 cm, $P = 0.139$). **Conclusion:** Topical AE ointment can reduce the abdominal fat thickness as well as the waist circumference without causing any side effect.

Key words: Abdominal circumference, *Arnebia euchroma*, fatty thickness, herbal ointment, topical appliance

How to cite this article: Siavash M, Naseri M, Rahimi M. *Arnebia euchroma* ointment can reduce abdominal fat thickness and abdominal circumference of overweight women: A randomized controlled study. J Res Med Sci 2016;21:63.

INTRODUCTION

Obesity, excess body fat, is a growing health problem in most developed and some developing countries.^[1] It is a very important risk factor for cardiovascular disease, and also a risk factor for type 2 diabetes mellitus, hypertension, osteoarthritis, fatty liver, and other problems, which have collectively been named metabolic syndrome.^[2,3] The metabolic syndrome is characterized

by the clustering of disorders which includes high blood pressure, high insulin concentrations, excess body weight with central obesity, and an altered lipid profile (dyslipidemia) that increases the likelihood of developing micro- and macro-vascular complications, including coronary heart disease or stroke.^[4,5]

Abdominal circumference (AC) and abdominal fat thickness (AF) are the important aspects of metabolic syndrome. Measures to reduce AC and AF may reduce the risk of comorbidities associated with metabolic syndrome.

This is an open access article distributed under the terms of the Creative Commons Attribution-NonCommercial-ShareAlike 3.0 License, which allows others to remix, tweak, and build upon the work non-commercially, as long as the author is credited and the new creations are licensed under the identical terms.

For reprints contact: reprints@medknow.com

Access this article online

Quick Response Code:



Website:

www.jmsjournal.net

DOI:

10.4103/1735-1995.187347

Address for correspondence: Dr. Mojgan Rahimi, Department of Internal Medicine, Isfahan University of Medical Sciences, Isfahan, Iran.

E-mail: dr.rahimimojgan@gmail.com

Received: 16-08-2015; **Revised:** 17-10-2015; **Accepted:** 11-04-2016

To date, the main interventions to reduce these risks are based on nutritional and physical activity modifications,^[6-8] and there have been rare reports of topical applications for reduction of AC or AF.^[9] Therefore, this study was aimed to investigate the effectiveness of *Arnebia euchroma* (AE) ointment on AC and AF.

AE (Havachobeh or Abukhalsa) is a traditional medical plant that grows in Asia (Iran), the Himalayas, and North Africa. Hydroxynaphthoquinones (alkannin and shikonin) are the active components of this traditional medicine that have anti-inflammatory, anti-bacterial, anti-fungal, and immune-modulatory roles.^[10-12] AE was a safe medication used to improve wound healing in burn victims in some studies.^[10] The histologic evaluation of the wounds of the rats treated by AE ointment showed that it has improving effects on blood vessels and their density, fibroblast formation, granulation tissue formation, and collagen bundle synthesis.^[11] Based on the positive findings of AE, we designed a double-blind single-center clinical trial to investigate the effectiveness of AE ointment on AC and AF.

MATERIALS AND METHODS

Arnebia euchroma ointment preparation

The main part of the ointment is AE (8.7%). In addition, it consisted of solid paraffin (40.87%), waxy paraffin (29.43%), castor oil (20%), and rosemary essence (1%). To prepare the ointment, 50 g of AE powdered root and 500 g of solid paraffin were first heated up to 70°C for about 12 h. Waxy paraffin, castor oil, and rosemary essence were then added to the mixture and the mixture was cooled down. Finally, 50 g of the ointment was packed and kept in the temperature between 0°C and 4°C. The rosemary essence was added to make the product more favorable. The placebo ointment that was used in the control group contained eucerin and had the same odor and color as AE ointment.

Subjects and intervention

This study was a double-blind randomized clinical trial. Sixty female candidates were selected from the endocrinology clinic of Khorshid Hospital, Isfahan, Iran. The inclusion criteria were female gender, age between 25 and 40, and body mass index (BMI) >25. In addition, the candidates were on usual diet and had no considerable past medical history such as hypothyroidism, diabetes mellitus, or use of the steroid drugs during the past 3 months. If the participants showed allergic reaction to the ointment or did not follow the ointment usage instruction, they were excluded from the study.

The procedure was explained thoroughly and informed consent was obtained from each participant. Then, the

participants were randomly divided into the case and control groups (thirty in each group) by selecting a number from a box.

The case group applied the handmade AE ointment every day for 6 weeks, whereas the control group applied the placebo ointment with the same instruction. The instruction to use the ointment was to apply 1 cc to the whole abdominal area except around the belly button (i.e., 10 cm²) and to cover the area with a plastic sheet. The candidates were required to do aerobic activities for 30 min after the application of ointment to the skin. All the candidates were instructed to eat their usual diet during the day and a low calorie meal (i.e., salad or cooked vegetables) for dinner.

BMI, abdominal and buttock circumference, and AF were measured at their first visit and after 2, 4, and 6 weeks. AC was measured by the tape meter and AF was measured by skinfold caliper. All the measurements were conducted by the same person and the same devices during the course of the study.

Statistical analysis

Quantitative data were expressed as mean ± standard deviation whereas qualitative data as frequency (percentage). Normality of quantitatively studied variables was evaluated using Q-Q plot and Kolmogorov-Smirnov statistical test. Within- and between-groups analyses over the study period were conducted using repeated measures ANOVA. Mauchly's sphericity test was conducted to assess sphericity as a prerequisite assumption. Huynh-Feldt correction was applied when this assumption was not satisfied. Within-group comparisons at each follow-up time points were tested using repeated contrasts.

Between-groups analysis in each time point of follow-up period was conducted using independent *t*-test. Chi-square test was used for comparing the categorical data between two studied groups. All analyses were performed in SPSS (version 16, SPSS Inc., Chicago, IL, USA).

The study was approved by the vice chancellor of research, Isfahan University of Medical Sciences by the number 393786.

RESULTS

Sixty female candidates participated in this study (thirty in each group). Ten patients left the study (one for pregnancy, one for ovarian cyst, one for hyper-reactive airway and dyspnea, two for migration, and five for personal or familial problems). Fifty participants finished the trial (26 in the case and 24 in the control group) [Figure 1]. Forty-four candidates (88%) were married and 6 (12%) were single.

Although randomly divided, the two groups were different regarding weight, BMI, and AC, but were similar in age, height, buttock circumference, and AF. The education level was also equal in the groups ($P = 0.597$). The baseline characteristics of the participants are presented in Table 1.

At the end of the study, participants had a significant weight loss (2.96 ± 1.6 kg, $P < 0.001$) that was slightly higher in the case group (3.15 ± 1.5 kg vs. 2.75 ± 1.7 , $P = 0.375$). AC also decreased significantly in the participants (11.3 ± 6.7 cm, $P < 0.001$), but the changes were more significant in the case group (13.9 vs. 6.5 cm, $P = 0.004$). AC decrement at each visit (evaluated by repeated measures) was also more significant in the case group ($P = 0.01$) [Figure 2]. Similarly,

AF decreased significantly in the participants (2.3 ± 1.1 cm, $P < 0.001$) [Figure 3]. Although changes were not significantly different between two groups (2.53 vs. 2.04 cm, $P = 0.139$), its decrement at each visit (evaluated by repeated measures) was more obvious in the case group ($P = 0.08$) [Table 2].

As changes of AC and fat thickness could be attributed to weight reduction, we controlled its role as a covariate and did not observe significant effects ($P = 0.517$).

Two participants of the case group experienced mild irritation at the ointment application site. There was no severe drug reaction or other complications due to AE ointment.

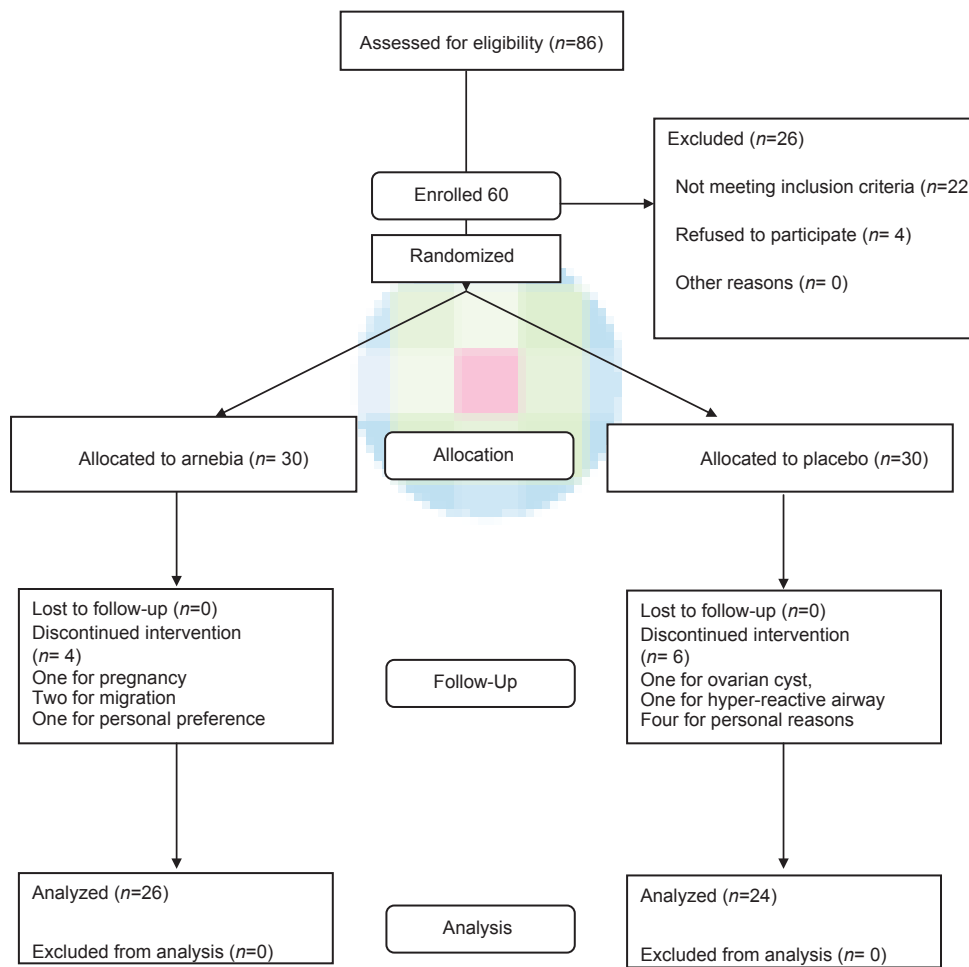


Figure 1: The consort E-flowchart - May 2015

Table 1: Baseline data of the participants

Group	Age*	Height	Weight	Body mass index	Abdominal circumference	Buttock circumference	Abdominal fat thickness
Case	35.8±3.2	162.8±6.1	79.51±3.8	30.0±4.0	105.6±10.1	108.3±9.9	4.7±1.2
Control	33.8±5.5	162.3±5.4	72.6±9.0	27.6±2.8	97.3±7.9	104.8±7.5	4.0±1.2
Total	34.8±4.5	162.6±5.7	76.2±12.1	28.8±3.6	101.6±9.9	106.6±8.9	4.4±1.2
P	0.103	0.773	0.043	0.022	0.002	0.161	0.081

*Mean±SD. SD = Standard deviation

DISCUSSIONS

The present study showed the potential efficacy of topical AE ointment on AC and AF reduction.

AE is a plant that grows in Asia and North Africa. Roots of AE have naphthoquinone.^[12] Naphthoquinone is made of two prominent components; water-insoluble pigments named alkannin and shikonin. These components have various pharmacotherapeutic roles such as immune-modulation, anti-inflammation, and wound healing. Their anti-microbial role works against methicillin-resistant *Staphylococcus aureus* and vancomycin-resistant enterococci. They also induce positive stimulatory effect on epithelialization, collagen bundle and fibroblast proliferation, and angiogenesis.^[13] In one study, shikonin is used as traditional excrete that stimulate epithelial transition and reduce microRNA expression during wound healing.^[10] Tumor necrosis factor-alpha (TNF-alpha) is a major inflammatory agent that plays a crucial role in the tissue damage.

Hydroxynaphthoquinone can reduce the amount of TNF-alpha serum level and its expression.^[11]

An ancient herbal formula, containing AE (named “marhame-mafasel or joint balm”), has been traditionally used for decreasing the inflammation of the joints in conditions such as rheumatoid arthritis, and our observations had shown that some patients also experience some skin fat reduction at the site of its application. It is the first study that evaluates this herbal medicine for abdominal fat reduction.

The participants of the *Arnebia* group had 5 cm more reduction of the AC. This degree of change in the abdominal obesity may have significant clinical benefits. Although the effects on fat thickness in this study of brief duration were not very significant, it may have potential clinical applications.

Several studies have focused on the importance and necessity of a suitable strategy to reduce abdominal fat

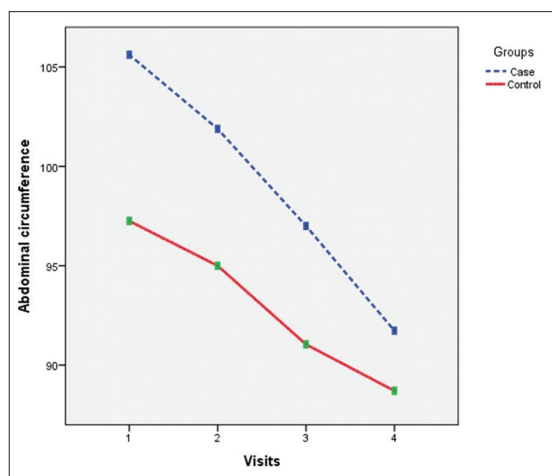


Figure 2: Changes of abdominal circumference during the study

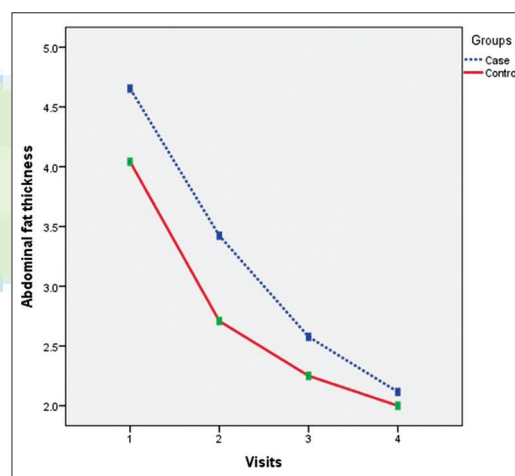


Figure 3: Changes of abdominal fat thickness

Table 2: Changes of main variables

	Visit 1 Baseline	Visit 2	Visit 3	Visit 4 Final	P (Within group)	P (Between group)
AC						
Case	105.6 (10.1)	101.9 (9.4)	97.0 (11.0)	91.7 (9.8)	0.000	0.016
Control	97.3 (7.9)	95.0 (7.6)	91.0 (7.8)	88.7 (7.4)	0.000	0.012*
AT						
Case	4.7 (1.2)	3.4 (0.7)	2.7 (0.4)	2.2 (0.3)	0.000	0.002
Control	4.0 (1.2)	2.7 (0.7)	2.3 (0.4)	1.9 (0.2)	0.000	0.002*
Buttock						
Case	108.3 (9.9)			106.8 (9.2)	0.000	0.326
Control	104.8 (7.5)			103.8 (7.1)	0.011	0.176*
Weight						
Case	79.5 (13.8)			76.4 (13.3)	0.000	0.419
Control	72.6 (9.0)			69.9 (8.6)	0.000	

*Adjusted for weight changes

both surgically and medically.^[14,15] However, some studies implied that there was no main causal role between the AF reduction and obesity comorbidities. The visceral AF decrement was considered to be more crucial than subcutaneous fat layer in association with obesity health risks. In contrast, one study on the omentectomy patients demonstrated that the insulin sensitivity was not influenced by visceral AF omitting. Furthermore, subcutaneous fat reduction such as liposuction did not improve insulin resistance and inflammatory risks.

Fat loss occurs by a combination of hormonal and metabolic effects. It occurs from within the body by the way of a calorie deficit (simply decreasing calorie intake and increasing physical activity). Every 3500-calorie deficit will result in a 1-pound loss of fat. By this view, we do not expect a topical remedy to be effective for fat loss. However, at the cellular level, fat can be burnt and releasing energy as heat at the mitochondria membrane. Further studies are needed to clarify if this or others are the mechanism of action of AE ointment.

Our study had some limitations: First, we evaluated limited number of participants. Larger studies with longer duration may display more significant results. Second, our study shows only decrease of AC and fat thickness. Whether AE ointment beside decrease of AC and fat thickness will result in better clinical outcome for the obese people or not should be investigated in long-term studies.

CONCLUSION

The present study showed that topical AE ointment can reduce AF as well as AC. In addition, AE ointment had no short- or long-term adverse effects on the skin in comparison to other topical and local methods to reduce the abdominal fat.

Acknowledgments

We would like to thank the Isfahan University of Medical Sciences.

Financial support and sponsorship

Vice chancellor of research, Isfahan University of Medical Sciences.

Conflicts of interest

The authors have no conflicts of interest.

AUTHORS' CONTRIBUTION

- MS designed the study, observed and manages its conduct, analyzed the result, and finalized the manuscript.
- MN produced the *Arnebia* ointment, helped to design

the study, and finalized the manuscript.

- MR helped to design the study, conducted the study, produces the primary manuscript, and finalized it.

REFERENCES

1. National Task Force on the Prevention and Treatment of Obesity. Overweight, obesity, and health risk. *Arch Intern Med* 2000;160:898-904.
2. Siavash M, Sadeghi M, Salarifar F, Amini M, Shojaee-Moradie F. Comparison of body mass index and waist/height ratio in predicting definite coronary artery disease. *Ann Nutr Metab* 2008;53:162-6.
3. Oh S, Tanaka K, Noh JW, So R, Tsujimoto T, Sasai H, et al. Abdominal obesity: Causal factor or simply a symptom of obesity-related health risk. *Diabetes Metab Syndr Obes* 2014;7:289-96.
4. Anderssen SA, Holme I, Urdal P, Hjermann I. Associations between central obesity and indexes of hemostatic, carbohydrate and lipid metabolism. Results of a 1-year intervention from the Oslo Diet and Exercise Study. *Scand J Med Sci Sports* 1998;8:109-15.
5. Boehm BO, Claudi-Boehm S. The metabolic syndrome. *Scand J Clin Lab Invest Suppl* 2005;240:3-13.
6. Costigan SA, Eather N, Plotnikoff RC, Taaffe DR, Lubans DR. High-intensity interval training for improving health-related fitness in adolescents: A systematic review and meta-analysis. *Br J Sports Med* 2015;49:1253-61.
7. Copaci I, Lupescu I, Caceaune E, Chiriac G, Ismail G. Noninvasive markers of improvement of liver steatosis achieved by weight reduction in patients with nonalcoholic fatty liver disease. *Rom J Intern Med* 2015;53:54-62.
8. Castaldo G, Palmieri V, Galdo G, Castaldo L, Molettieri P, Vitale A, et al. Aggressive nutritional strategy in morbid obesity in clinical practice: Safety, feasibility, and effects on metabolic and haemodynamic risk factors. *Obes Res Clin Pract* 2015. pii: S1871-403X00065-4.
9. Caruso MK, Pekarovic S, Raum WJ, Greenway F. Topical fat reduction from the waist. *Diabetes Obes Metab* 2007;9:300-3.
10. Aliasl J, Khoshzaban F, Barikbin B, Naseri M, Kamalinejad M, Emadi F, et al. Comparing the healing effects of *Arnebia euchroma* ointment with petrolatum on the ulcers caused by fractional CO₂ laser: A single-blinded clinical trial. *Iran Red Crescent Med J* 2014;16:e16239.
11. Fan HY, Zhang ZL, Liu K, Yang MY, Lv WH, Che X, et al. Effectiveness of a hydroxynaphthoquinone fraction from *Arnebia euchroma* in rats with experimental colitis. *World J Gastroenterol* 2013;19:9318-27.
12. Syklovska-Baranek K, Pilarek M, Cichosz M, Pietrosiuk A. Liquid perfluorodecalin application for *in situ* extraction and enhanced naphthoquinones production in *Arnebia euchroma* cell suspension cultures. *Appl Biochem Biotechnol* 2014;172:2618-27.
13. Ashkani-Esfahani S, Imanieh MH, Khoshneviszadeh M, Meshksar A, Noorafshan A, Geramizadeh B, et al. The healing effect of *Arnebia euchroma* in second degree burn wounds in rat as an animal model. *Iran Red Crescent Med J* 2012;14:70-4.
14. Bermudez V, Rojas J, Salazar J, Anez R, Toledo A, Bello L, et al. Sensitivity and specificity improvement in abdominal obesity diagnosis using cluster analysis during waist circumference cut-off point selection. *J Diabetes Res* 2015;2015:750265.
15. Ahmad Kiadaliri A, Jafari M, Vaez Mahdavi MR, Faghizadeh S, Kalantari N, Asadi-Lari M. The prevalence of adulthood overweight and obesity in Tehran: Findings from Urban HEART-2 study. *Med J Islam Repub Iran* 2015;29:178.