

Pseudo-subarachnoid hemorrhage and optic neuritis in an 18-year-old girl with sodium valproate overdose

Sir,

There are some neurological side effects and sequels following sodium VPA use in therapeutic or toxic doses. In this letter, a case report of VPA overdose with rare neurological findings is presented.

An 18-year-old girl was admitted to the emergency department of medical toxicology 1 h after attempted suicide with ingestion of 200 tablets of sodium VPA (80 mg). She had no history of known physical illness. On admission, she had loss of consciousness, with normal vital signs and midsize, reactive pupils.

Gastric decontamination including gastric lavage and multiple doses of activated charcoal were considered for the patient. Twelve hours later, the patient was intubated and transferred to Intensive Care Unit because of low level of consciousness (coma). Pupils were dilated and nonreactive to light at this time. Serum level of VPA was 1270 $\mu\text{g}/\text{mL}$, and serum ammonia level was 9.04 $\mu\text{g}/\text{mL}$, 24 h after admission. Brain computerized tomographic (CT) scan showed brain edema and high probability of subarachnoid hemorrhage (SAH) [Figure 1]. Lumbar puncture was

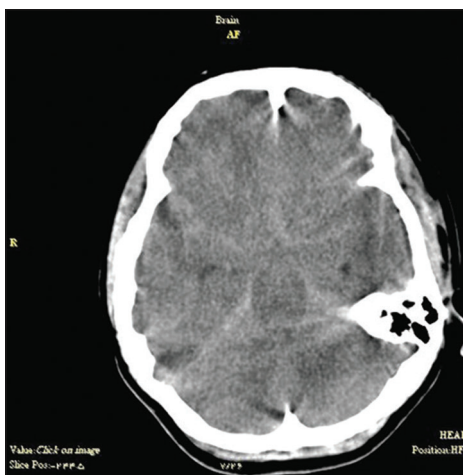


Figure 1: Noncontrast cranial computerized tomographic scan: Areas of abnormally increased density in the subarachnoid spaces and interhemispheric fissures suggestive of subarachnoid hemorrhage

not performed because her family refused to fill out informed consent. Brain (CT) angiography represented no evidence of SAH, and pseudo-SAH (PSAH) was considered to describe this condition [Figure 2].

L-carnitine tablet was begun immediately after admission. Because of documented hyperammonemia, loss of consciousness and respiratory symptoms, hemodialysis was performed, and sodium benzoate was prescribed. Level of consciousness improved prominently, and she was completely alert 6 days after admission. Ammonia level turned back to normal; although she had lost her right eye vision completely (no light perception) and her left eye vision had been decreased significantly (count finger). Funduscopic examination by an ophthalmologist revealed no evidence of disk swelling or papillitis and retrobulbar neuritis following drug toxicity was diagnosed. Brain magnetic resonance imaging was normal at this time [Figure 3]. After 1 month follow-up, no change in visual acuity was detected.

Neurologic sequels following VPA overdose are rarely reported. Bigler on 1985 reported a 24-year-old man with severe VPA toxicity which involved liver, heart, eyes, and brain. Reduced acuity of vision was due to optic neuritis which remained for more than 2 months; coma in that case lasted for 13 days.^[1] This case was admitted 18 h after consumption of 100 g VPA. Brain CT scan was normal 15 days after admission although hypodense areas were reported in both thalami in CT scan which was performed 20 days after the first one. Serum level of VPA was 300.25 $\mu\text{g}/\text{mL}$ 2 days and 61.01 $\mu\text{g}/\text{mL}$ 4 days after admission. It was the only other report of optic neuritis due to VPA toxicity.

Moreover, only one other case of PSAH in brain CT scan of a patient with VPA toxicity had been reported by Min

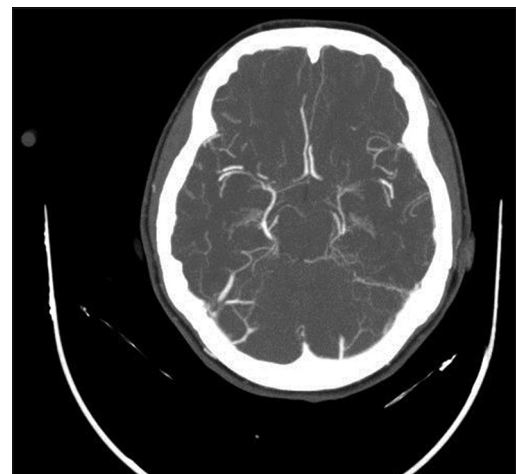


Figure 2: Computerized tomographic angiography of brain vessels, with no evidence of saccular aneurysm and hemorrhage in subarachnoid spaces

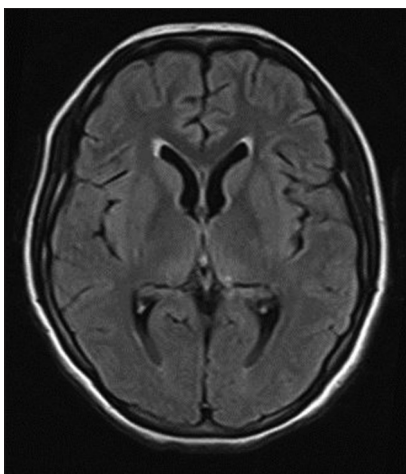


Figure 3: Normal brain magnetic resonance imaging

and Tse. The presence of cerebral edema has been stated as the reason for this false positive image.^[2] This case was a 22-year-old male who admitted after consumption of 50 g VPA. Serum VPA level was 637.71 µg/mL, hours after consumption and serum ammonia concentration was 279 µg/mL.

In our case, we had simultaneously two rare neurologic sequels in an 18-year-old girl after consumption of 200 tablets of sodium VPA: PSAH and optic neuritis. Very high serum levels of valproic acid may act as a contrast agent particularly in the context of brain edema; although it is just a theory and future investigations are needed to confirm it. Physicians should be aware of neurologic sequels following VPA poisoning.

Acknowledgments

We would appreciate all kind attempts of staff in Intensive Care Unit of Imam Reza Hospital.

Financial support and sponsorship

Nil.

Conflicts of interest

The authors have no conflicts of interest.

Bit a Dadpour, Hassan Abbaspour¹, Ali Pourzahed², Ahmad Bagheri Moghadam¹

Department of Medical Toxicology, Addiction Research Centre,

¹Department of Anesthesiology, Cardiac Anesthesia Research Centre,

²Department of Neurology, Medical Toxicology Research Centre, Mashhad University of Medical Sciences, Mashhad, Iran

Address for correspondence: Assist. Prof. Ahmad Bagheri Moghadam, Department of Anaesthesiology and Critical Care, Imam Reza Hospital, Mashhad University of Medical Sciences, Mashhad, Iran.
E-mail: bagheria@mums.ac.ir

REFERENCES

1. Bigler D. Neurological sequelae after intoxication with sodium valproate. *Acta Neurol Scand* 1985;72:351-2.
2. Min YG, Tse ML. Image in toxicology: Pseudo-subarachnoid hemorrhage in a case of severe valproic acid poisoning. *Clin Toxicol (Phila)* 2011;49:699-700.

This is an open access article distributed under the terms of the Creative Commons Attribution-NonCommercial-ShareAlike 3.0 License, which allows others to remix, tweak, and build upon the work non-commercially, as long as the author is credited and the new creations are licensed under the identical terms.

Access this article online	
Quick Response Code:	Website: www.jmsjournal.net
	DOI: 10.4103/1735-1995.183998

How to cite this article: Dadpour B, Abbaspour H, Pourzahed A, Bagheri Moghadam A. Pseudo-subarachnoid hemorrhage and optic neuritis in an 18-year-old girl with sodium valproate overdose. *J Res Med Sci* 2016;21:43.