

Voice rehabilitation with tragal cartilage and perichondrium after vertical partial laryngectomy for glottic cancer

Magdalena Chirilă, Cristina Țiple, Florina Veronica Dinescu, Rodica Mureșan¹, Sorana D. Bolboacă²

Departments of ENT and ²Medical Informatics and Biostatistic, Iuliu Hațieganu University of Medicine and Pharmacy, ¹Department of Phoniatry, Emergency County Hospital, Cluj-Napoca, Romania

Background: The goal of the study is to test medialization of the neocord after oncological surgery for glottic cancer, using autologous tragal cartilage and perichondrium by the direct approach. **Materials and Methods:** Sixteen patients underwent comprehensive assessment including auditory perceptual assessment, videostrobolaryngoscopy, and acoustic voice analysis. The cartilage graft was inserted into a pocket created in the thyroarytenoid — lateral cricoarytenoid muscle complex or the excavated musculomembranous part of the neocord, and fixed by placing the perichondrium by the direct approach. The patients were evaluated preoperatively, and at 14 days, 60 days, and 6 months later. **Results:** Improvement of voice and breathiness was correlated with the increase of closed quotient and harmonic-to-noise ratio; the acoustic voice parameters studied showed significant differences between preoperative and postoperative voices, and these objective measurements of voice changes provided accurate and documentary evidence of the results of surgical treatment. **Conclusion:** This method may be considered a safe and efficient phonosurgical procedure for voice restoration.

Key words: Cartilage, glottic cancer, medialization, partial laryngectomy, perichondrium, voice restoration

How to cite this article: Chirila M, Tiple C, Dinescu FV, Muresan R, Bolboaca SD. Voice rehabilitation with tragal cartilage and perichondrium after vertical partial laryngectomy for glottic cancer. J Res Med Sci 2015;20:323-8.

INTRODUCTION

The quality of a patient's life after any given cancer surgery usually is regarded as a second-priority consideration after oncologic safety. Contemporary health care professionals often include resultant qualitative dimensions that are specific and important for the patient when evaluating the success of any procedure.^[1] Excising part or all of a larynx as a cancer operation results in changes that transgress anatomic, physiologic, psychologic, and social common principles.^[2] When total or partial laryngectomy procedures are performed, profound changes in anatomy and physiology and thus, voice are inevitable.^[1] Hans von Leden's statement remains broadly true, that "during the first 100 years of our specialty, laryngeal surgery was devoted largely to the removal of neoplasms, and any potential improvement in voice was really a by-product of this process".

Zeitels *et al.* in 1867^[3] was probably the first to cure an early glottic cancer with a vertical partial laryngectomy by transcervical approach, procedure which has always been associated with a temporary or permanent tracheostomy. Over time, it was determined that voice quality would improve if the cartilage was resected lateral to the

cancerous glottal soft-tissue because this would enhance aerodynamic valvular competency of the neoglottis and this principal remains today in laryngeal framework surgery techniques. During the last 25 years, there has been an expansion of the role of endoscopic glottic cancer management with the introduction of the CO₂ laser so that transoral partial laryngectomy is commonplace.^[4]

External or endoscopic vertical partial laryngectomies had provided opportunities for voice rehabilitation by reconstructing the neoglottal valve by using a combination of medialization laryngoplasty techniques that were primarily developed for unilateral vocal fold paralysis. This paper is about a new technique and functional voice outcomes of medialization of the neocord resulting after a vertical partial laryngectomy for an early glottic cancer by means of augmentation of the paraglottic space or the excavated musculomembranous vocal fold with autologous tragal cartilage and perichondrium.

MATERIALS AND METHODS

This prospective nonrandomized study was reviewed and approved by the Ethics Committee of "Iuliu

Address for correspondence: Dr. Magdalena Chirilă, Department of ENT, Iuliu Hațieganu University of Medicine and Pharmacy, Cluj-Napoca, 13 Emil Isac, 400023, Cluj-Napoca, Romania. E-mail: chirila_magda@yahoo.com

Received: 31-07-2014; **Revised:** 24-02-2015; **Accepted:** 01-03-2015

Hațieganu" University of Medicine and Pharmacy, Cluj-Napoca, Romania. The study included 16 patients which were at 2 years follow-up after surgical treatment for an early glottic cancer. The surgeries were performed between August 2011 and November 2013 in our clinic. The inclusion criteria were:

1. Patients who underwent a vertical partial laryngectomy (endoscopic CO₂ laser assisted types IV cordectomy or a classical cordectomy by median thyrotomy or fronto-lateral laryngectomy);
2. No other types of partial laryngectomy;
3. No prior oncological therapy;
4. 2 years follow-up for T1-T2 glottic cancer without any evidence of local recurrence (clinic and imagistic) with negative biopsy;
5. Informed consent with a wide description of the surgical procedure, the expected outcomes and the possible complications; and
6. Acceptance of the follow-up schedule, in which it was explained that, the subject may discontinue participation at any time without penalty.

The exclusion criteria were:

1. Oncological follow-up <2 years;
2. Failure to comply the follow-up schedule.

All the patients were men with average age of 49.7 years. They underwent three types of vertical partial laryngectomy 2 years ago [Table 1] without any adjuvant or neoadjuvant oncological therapy (radiotherapy or chemotherapy).

All the patients complained of a breathy and asthenic voice with inefficient cough. All patients received speech and language therapy preoperatively (about ten sessions) and postoperatively (about five sessions).

All the patients underwent comprehensive assessment including smoking and drinking habits, laryngeal status,

auditory perceptual assessment, videostrobolaryngoscopy, and acoustic voice analysis. The patients were evaluated preoperatively, and at 14 days, 60 days, and 6 months postoperatively.

Surgery

All the surgical procedures were performed under general anesthesia with oro-tracheal intubation.

The tragal cartilage and perichondrium composite graft was obtained through a horizontal incision at 2 mm from the upper tip of the tragus. A transfixion incision through the tragal cartilage was done with respect 2 mm from the superior part of the cartilage. The inner tragal perichondrium was dissected and the composite graft was harvested. The perichondrium was isolated from the cartilage and put it into the Ringer solution. The cartilage was prepared in more pieces of 0.5 mm [Figure 1] and put them into the Ringer solution.

The new cord resulting after surgical treatment of glottic cancer was visualized through direct microlaryngoscopy. A superior cordotomy was performed and the fibrous scar was smoothly dissected, anteriorly and posteriorly, from the thyroid ala. The cartilage pieces were inserted one by one into the thyroarytenoid – lateral cricoarytenoid muscle complex pocket [Figure 2] to obtain the desired medialization of the vocal fold, with respect to the horizontal and vertical planes of the vocal folds. In case of excavated musculomembranous vocal fold the pocket was created on those excavated part and the pieces of the cartilage were inserted in the same manner.

To prevent the cartilage extrusion was used the tragal perichondrium and placed it under the incision borders in an inlay technique, resulting a supplementary medialization of the vocal fold [Figure 3].

Table 1: Type of vertical partial laryngectomy

Surgery	TNM	Primary tumor site	Number of cases
Endoscopic CO ₂ laser assisted type IV cordectomy	T1aN0M0	Middle third of vocal fold	6
Classical cordectomy by transcervical approach	T1aN0M0	2/3 of vocal fold without anterior commissure involvement	2
	T2N0M0	2/3 of vocal fold with impaired mobility	1
Fronto-lateral partial laryngectomy	T1aN0M0	Vocal fold with anterior commissure involvement	5
	T2N0M0	Vocal fold with anterior commissure involvement and impaired mobility	2

TNM = Tumor-node-metastasis

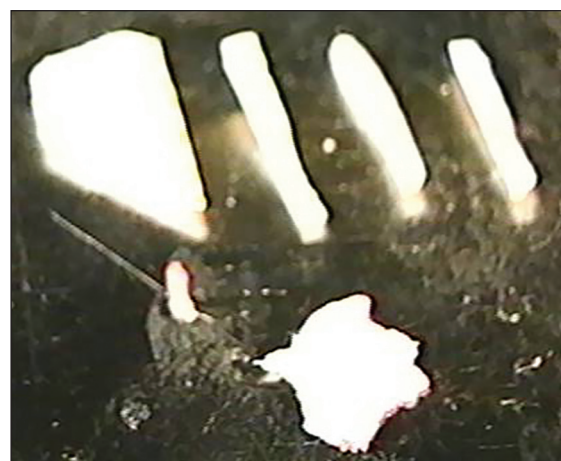


Figure 1: The tragal cartilage and perichondrium

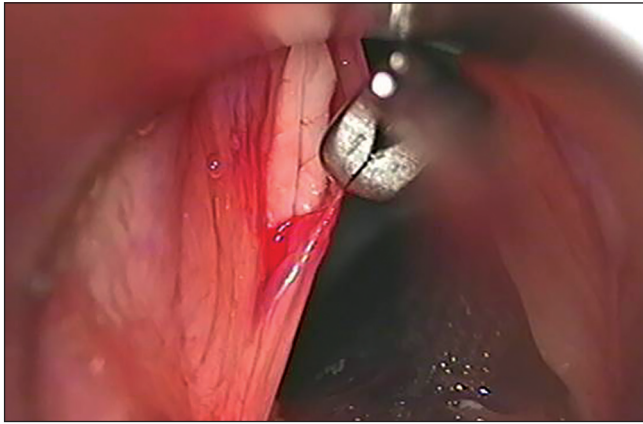


Figure 2: Cartilage insertion

Each patient received 1.2 g augmentine (according to Antibio prophylaxy Guide of the Romanian Society of Anesthesiology and Intensive Care) and 8 mg dexametazone intraoperatively.

All the patients were observed in the hospital for 1-day after surgery. The first videolaryngoscopy was done during the 1st day after surgery. The patients were evaluated at 14 days, and then at 60 days, and 6 months later.

Voice analysis

Vocal function was evaluated using a multidimensional set of perceptive, acoustic, videolaryngostroboscopic (VLS), aerodynamic and subjective measurements according to the protocol elaborated by the Committee on Phoniatrics of the European Laryngological Society.^[5]

Each patient underwent rigid videostrobolaryngoscopy (Storz 90° rigid telescope connected to a charge-coupled device, camera model 20200042, Storz, Germany, and a light source) before and at 1st day after surgery, and then at each follow-up visit. The following stroboscopic parameters were evaluated:

1. Longitudinal glottal closure,
2. Regularity of vibration of vocal cords,
3. Mucosal wave.

For the rating of each stroboscopic parameter, a 100-mm visual analogue scale (VAS) was used (0, no deviance; 100, severe deviance).

Vocal function was assessed and voice recordings were performed before surgery and 14 days, and then at 60 days, and 6 months after neocord medialization. The patients were recorded counting from 1 to 10, reading a standardized passage, and sustaining the vowels /a/, /i/, and /u/ at a comfortable pitch and loudness in an acoustically treated room. The recorded samples were evaluated by the speech-language therapist, a

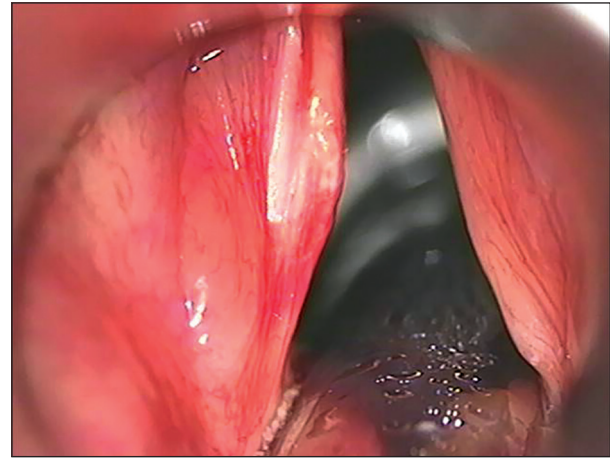


Figure 3: Final surgical result

simplified, clinically feasible version of the GRBAS scale (GRB) consisting of G (grade), R (rough) and B (breathy) factors was adopted to assess hoarseness using a 4-point grading system (0, normal; 1, slight; 2, moderate; 3, extreme). The evaluation of patient's impression about the quality of his voice was carried out on a 100-mm-long VAS.

Voice analysis was performed by using Praat software v.5.3.04 (created by Paul Boersma and David Weenink, Institute of Phonetic Sciences, University of Amsterdam, Amsterdam, The Netherlands). The acoustic voice analysis was performed in a soundproof room; a constant mouth-to-microphone distance of 30 cm was maintained. The patients were instructed to sustain the vowel /i/ at a comfortable pitch and loudness and fundamental frequency (FO), jitter, shimmer, closed quotient (CQ) and harmonic-to-noise ratio (HNR) values were obtained.

Statistical analysis is presented as means and standard deviations (SDs) for each parameter were obtained for the preoperative and postoperative trials. The comparison of the perceptual data and acoustic voice analysis of the patients pre- and post-operatively were done using paired sample Student's *t*-test, with a significance level set to 0.05. A repeated measures analysis of variance (ANOVA) was used to analyse if there were any statistically significant changes in objective or subjective measures at different times of the follow-up. The follow-up visits were the within-subject variable for each subjective and objective measure, and the analysis also included Bonferroni *post-hoc* test. For all objective measures, Mauchly's test showed that sphericity can be assumed. For the subjective data Mauchly's test showed that sphericity cannot be assumed and the significance level was therefore corrected using the Greenhouse-Geisser method. The Statistica 8.0 software (StatSoft, Tulsa, OK) were used for the statistical analysis.

RESULTS

Sixteen patients who underwent medialization of the neocord were randomly selected for this study. The medialization laryngoplasty used autologous tragal cartilage and perichondrium and was performed by the direct microlaryngoscopic approach, by the same surgeon, in the same way, and under general anesthesia.

Videolaryngostroboscopic analysis has shown remarkable medialization of the neocord and more efficient glottal closure [Table 2] with more efficient vocal fold adduction. As a consequence of successful medialization of the neovocal fold, the degree of hoarseness and breathiness were found significantly decreased after surgery. Overall, the postoperative patient group revealed significant improvement to various degrees in the rated perceptual characteristics [Figure 4a and b].

A high degree of patient satisfaction with the surgery was achieved. The patients' own subjective evaluations of hoarseness on VAS decreased in average from 76.7 (SD 14.6) points before surgery to 19.8 (SD 12.0) points after medialization ($P < 0.001$).

Table 3 shows the preoperative and postoperative mean values and SDs of each acoustic voice parameter employed in this study. There was a statistically significant improvement in mean jitter, shimmer, CQ and HNR. The mean of fundamental frequency did not show any statistically significant changes from preoperative to postoperative samples. According to the data presented, acoustic voice parameters considered to reflect hoarseness, roughness and breathiness of voice improved considerably after surgery.

The results of the ANOVA revealed that time of follow-up did not have statistical significant effect on variables FO and HNR. However, for jitter, shimmer, and CQ the *post-hoc* test showed that the changes between the first and the final follow-up visits were significant ($P < 0.05$ for all of them). These results are presented in Table 4. Time of the follow-up visit showed a very large effect on all three subjective measures: both for breathiness as for hoarseness, differences in each pair of follow-up visits were significant [Table 5]. Two analyses were conducted to study the correlations between the changes in subjective and objective

variables within time. The Pearson's analysis with a level of 0.029 showed a significant linear correlations between the subjective and objective data.

DISCUSSION

The human larynx has four major physiologic functions, and its structure has evolved to integrate these vital but largely incompatible roles: Airway control (opening for respiration and closure for protection of the lower airway); swallowing; phonation; and effort closure during strenuous activity and coughing.^[1] A direct and wide surgical intervention in the vocal fold will deteriorate the voice because of scar development. Scars are very detrimental to the vocal fold vibration because for the vibrations to occur, the Bernoulli effect is essential to allow the closing of the vocal folds during the vibratory cycle.^[6]

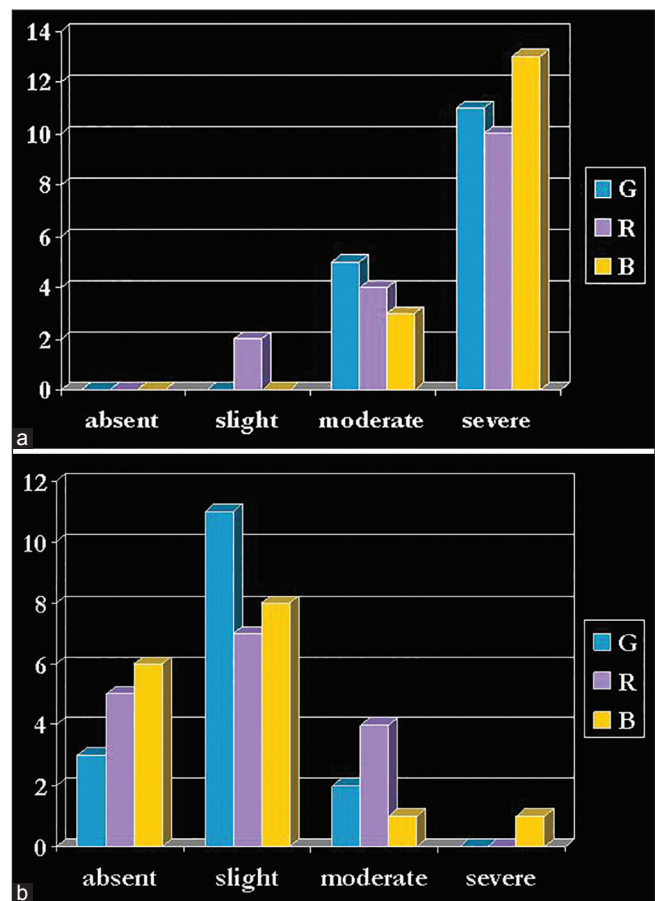


Figure 4: Perceptive evaluation of dysphonia pre (a) and postoperatively (b)

Table 2: Means of VLS parameters before and after medialization

Parameters	Mean (SD)		Difference		P
	Preoperative	Postoperative	Absolute	Percentage	
Longitudinal glottal closure	78.8 (21.5)	15.0 (12.5)	63.8	80.9	0.000
Regularity of vibration of vocal cords	82.8 (15.6)	48.6 (27.5)	34.2	41.6	0.000
Mucosal wave	72.7 (20.6)	42.2 (26.4)	30.5	42.2	0.000

SD = Standard deviation; VLS = Videolaryngostroboscopic

Table 3: Mean acoustic voice parameters before and after medialization

Acoustic voice parameter	Preoperative	Postoperative	P
FO (Hz)	142.2 (47.8)	146.7 (45.2)	0.582
Jitter (%)	1.47 (1.14)	0.31 (0.18)	0.000
Shimmer (%)	7.79 (4.92)	2.76 (1.68)	0.000
HNR	11.52±5.45	20.76±6.49	0.008
CQ (%)	24.88±16.47	50.00±8.23	0.001

FO = Fundamental frequency; CQ = Closed quotient; HNR = Harmonic-to-noise ratio

Table 4: Results from the univariate tests of the repeated measures ANOVA (sphericity assumed) for objective acoustic parameters

Acoustic measure	df	F	Significant
FO (Hz)	3	1.144	0.379
Jitter	3	3.785	0.006
Shimmer	3	3.247	0.023
HNR	3	1.141	0.339
CQ	3	3.531	0.019

Statistical parameters given are: df = Degree of freedom; F = F value; Significant = P value; where P < 0.05 indicates statistical significance. Acoustic measures are: FO = Fundamental frequency, jitter, shimmer; HNR = Harmonic-to-noise ratio; CQ = Closed quotient; ANOVA = Analysis of variance

Table 5: Results from the univariate tests of the repeated measures ANOVA (Greenhouse-Geisser) for subjective parameters

Symptom	df	F	Significant
Breathiness	1.805	28.776	<0.05
Hoarseness	1.842	14.763	<0.05

Statistical parameters given are: df = Degree of freedom; F = F value; Significant = P value; where P < 0.05 indicates statistical significance; ANOVA = Analysis of variance

When a glottic cancer resection requires excision of vocal musculature, the resulting neocord is usually concave, which leads to aerodynamic insufficiency during phonation.^[4] The goals of the clinician who manages malignancies of the larynx are to avoid the potential for local failure and mortality from cancer and when possible, to prevent total loss of the larynx.^[1] The three pillars on which organ-preservation surgery of the larynx is built are:

1. Accurate assessment of the origin and extent of the lesion,
2. Accurate assessment of the patient as a surgical candidate, and
3. A thorough understanding of the available surgical techniques and the preoperative management issues.^[7]

The simplest version of vertical partial laryngectomy is cordectomy with midline thyrotomy, a limited open procedure that involves excision of the involved true vocal fold and its adjacent internal perichondrium. The fronto-lateral vertical partial laryngectomy involves excision of one vocal cord, a portion of the contralateral vocal cord, and a portion of the thyroid cartilage.^[1] Alternatively, endoscopic CO₂ laser assisted type IV cordectomy involves

excision of entire vocal fold, from vocal process to anterior commissure, and internal perichondrium.^[8] Each of the above conservation laryngeal procedures involves resection of laryngeal structures and therefore, results in some degree of dysphonia. The degree of dysphonia is more dependent on the original location of the tumor, the type of resection performed, the tissue elasticity inherent to the remaining laryngeal structures, and the effects of postoperative changes including fibrosis.^[9] The postoperative role of the speech pathologist, therefore, is to identify (by use of laryngeal videostroboscopy) the primary source of phonation because these patients have been shown to exhibit a primary (true vocal cord) and secondary (supraglottic neolarynx) source of vibration. Behaviors that adversely affect vocal quality should be targeted first.^[10] Patients who did not require resection of muscle did not typically require phonosurgical reconstruction of the vocal fold.^[4]

Voice restoration is based on re-establishing glottal competency by reconfiguration of the glottal valve. This goal can be done by transoral lipoinjection or medialization laryngoplasty.^[4] When a large amount of paraglottic tissue is resected, an initial microlaryngoscopic lipoinjection is used to augment the paraglottic region and facilitate implant medialization later by transcervical approach. The lipoinjection may be used as the sole medialization procedure on a small concave defects.^[4,11]

Learning and being inspired from the tympanic membrane restoration surgery, we envisioned a vocal fold medialization technique that combines the advantages of tragal cartilage/perichondrium composite grafts (used in functional tympanic membrane reconstruction) and endolaryngeal microsurgery performed by the transoral approach. A composite graft has several advantages, including the fact that it does not cause rejections (biocompatibility); it is not reabsorbed (durability), and is easily obtained and easily handled.

Analysis of VLS images demonstrated a remarkable effect of surgical medialization of the new vocal fold and confirmed the more efficient glottic closure pattern after surgery. As a consequence, the degree of hoarseness and breathiness was found significantly decreased after medialization because of improved vocal cord adduction.

A significant decrease of amplitude perturbation (jitter and shimmer) reflected improvement of the stability of acoustic signal, decrease of turbulent noise (HNR measurement), improvement of closure quotient, and finally, a more efficient pattern of phonation. Thus, the acoustic voice parameters studied showed significant differences between preoperative and postoperative voices, and these objective measurements of voice

changes provided accurate and documentary evidence of the results of surgical treatment. The degree of each patient's satisfaction with the results of treatment is one of the most important parameters of the success of phonosurgery, as it is the patient who has to live with his/her voice.^[12,13] A significant decrease of hoarseness (as assessed by the speech and language therapist on GRB or by self-evaluation by the patient on VAS) reflected improvement of the postoperative social acceptability of the patient's voice in this study.

Voice rehabilitation with medialization of the neocord with tragal cartilage and perichondrium by transoral microlaryngoscopic approach, although offering improvement from the preoperative voice and significant patient satisfaction, does not provide a total recovery to normal voice. This is not a totally unexpected finding since the underlying condition of the fibrous neocord is still present and alters vocal fold vibration.

CONCLUSION

This method of medialization for voice restoration after surgery for glottic cancer, using autologous tragal cartilage and perichondrium and endolaryngeal microsurgery by transoral approach, may be considered a safe and efficient phonosurgical procedure.

ACKNOWLEDGMENTS

This paper was published under the frame of European Social Found, Human Resources Development Operational Programme 2007-2013, project no. POSDRU/159/1.5/S/138776.

AUTHOR'S CONTRIBUTION

MC: Collected data, Surgeon, conceived and designed study, interpreted data, wrote article, revised article; CT; FVD: Collected data, interpreted data, wrote article RM: Phoniatic analysis, conceived and designed study, interpreted data, wrote article; revised article; SDB: Statistical analysis, conceived and designed study, interpreted data, wrote article; revised article.

REFERENCES

1. Sparano A, Ruiz C, Weinstein GS. Voice rehabilitation after external partial laryngeal surgery. *Otolaryngol Clin North Am* 2004;37:637-53.
2. Friedrich G, Remacle M, Birchall M, Marie JP, Arens C. Defining phonosurgery: A proposal for classification and nomenclature by the Phonosurgery Committee of the European Laryngological Society (ELS). *Eur Arch Otorhinolaryngol* 2007;264:1191-200.
3. Zeitels SM. Jacob Da Silva Solis-Cohen: America's first head and neck surgeon. *Head Neck Surg* 1997;19:342-6.
4. Zeitels SM. Optimizing voice after endoscopic partial laryngectomy. *Otolaryngol Clin North Am* 2004;37:627-36.
5. Dejonkere PH, Bradley P, Clemente P, Cornut G, Crevier-Buchman L, Friedrich G, *et al.* A basic protocol for functional assessment of voice pathology, especially for investigating the efficacy of (phonosurgical) treatments and evaluating new assessment techniques. *Eur Arch Otorhinolaryngol* 2001;258:77-82.
6. Isshiki N. Mechanical and dynamic aspects of voice production as related to voice therapy and phonosurgery. *J Voice* 1998;12:125-37.
7. Weinstein GS, Laccourreye O. Organ preservation surgery of the larynx. In: Weinstein GS, Laccourreye O, Brasnu D, Laccourreye H. (eds) *Organ Preservation Surgery for Laryngeal Cancer*. San Diego: Singular Publishing Group; 2000. p. 1-8.
8. Remacle M, Eckel HE, Antonelli A, Brasnu D, Chevalier D, Friedrich G, *et al.* Endoscopic cordectomy. A proposal for a classification by the Working Committee, European Laryngological Society. *Eur Arch Otorhinolaryngol* 2000;257:227-31.
9. Ruiz C, Crevier-Buchman L. Speech/voice rehabilitation following organ preservation surgery. In: Weinstein GS, Laccourreye O, Brasnu D, Laccourreye H. (eds) *Organ Preservation Surgery for Laryngeal Cancer*. San Diego: Singular Publishing Group; 2000. p. 171-4.
10. Blaugrund SM, Gould WJ, Haji T, Metzger J, Bloch C, Baer T. Voice analysis of the partially ablated larynx. A preliminary report. *Ann Otol Rhinol Laryngol* 1984;93:311-7.
11. Piazza C, Bolzoni Villaret A, Redaelli De Zinis LO, Cattaneo A, Cocco D, Peretti G. Phonosurgery after endoscopic cordectomies. II. Delayed medialization techniques for major glottic incompetence after total and extended resections. *Eur Arch Otorhinolaryngol* 2007;264:1185-90.
12. Hajioff D, Rattenbury H, Carrie S, Carding P, Wilson J. The effect of Isshiki type 1 thyroplasty on quality of life and vocal performance. *Clin Otolaryngol* 2000;25:418-22.
13. Harries ML, Morrison M. Short-term results of laryngeal framework surgery – thyroplasty type 1: A pilot study. *J Otolaryngol* 1995;24:281-7.

Source of Support: This paper was published under the frame of European Social Found, Human Resources Development Operational Programme 2007-2013, project no. POSDRU/159/1.5/S/138776. **Conflict of Interest:** None declared.