

Breast cancer screening: Evidence of the effect of adjunct ultrasound screening in women with unilateral mammography-negative dense breasts

Atoosa Adibi, Maryam Golshahi, Mehri Sirus, Kimia Kazemi¹

Department of Radiology, ¹Department of Radiology, Medical faculty, Isfahan University of Medical Sciences, Isfahan, Iran

Background: Patients with the previous history of breast cancer are in risk of contralateral breast cancer. On the other hand, increased breast density is a risk factor for breast cancer and the sensitivity of detecting nonpalpable cancers in screening mammography in radiographically dense breasts is low. The use of ultrasonography in dense breast remains a controversial topic. The purpose of this study was to assess the usefulness of routine ultrasonography in follow-up of women with the previous history of breast cancer and negative mammography but dense breasts. **Materials and Methods:** In a cross-sectional study, a total of 267 individuals with unilateral postmastectomy mammogram screened and 153 subjects assigned to study. There were 28 subjects with American College of Radiology (ACR) breast density 2 and 125 with ACR breast density 3-4, which there was no new finding in their mammogram in comparison to previous studies. We assumed subjects with ACR breast density 3-4 as mammographic Breast Imaging Reporting and Data System (BI-RADS) category 0 for malignancy. Standard two-view mammogram was performed for all participants, and breast ultrasound (US) examinations were performed by an expert radiologist in radial and anti-radial planes. The data were analyzed using SPSS version 20.0 (SPSS Inc., Chicago, Illinois, USA). **Results:** The results showed that in subjects with ACR breast density 3-4, when there was no new density in two consecutive mammograms in comparison to previous studies, US also showed no possibility for malignancy (BI-RADS 1-2). And also in subjects with ACR breast density 2, when the mammographic results were BI-RADS 1-2, the US results was the same. **Conclusion:** Our data indicate that for the detection of breast cancer, sensitivity of US was not greater than mammography in patients with postmastectomy unilateral dense breast if there is not any new density.

Key words: Breast cancer, breast density, breast imaging reporting and data system, mammography, ultrasound

How to cite this article: Adibi A, Golshahi M, Sirus M, Kazemi K. Breast cancer screening: evidence of the effect of adjunct ultrasound screening in women with unilateral mammography-negative dense breasts J Res Med Sci 2015;20:228-32.

INTRODUCTION

Cancer of the breast is the most prevalent cancer in women worldwide and also in Iranian women.^[1-2] In spite of many progresses in identifying genetic markers and risk factors for breast cancer, approximately 70-80% of cases will occur in women without any known major predictor.^[3] When there is no effectual primary prevention measures, screening, and early detection could be an important way for reducing the mortality rate of breast cancer and to prolong patients' life; it emphasizes on detecting cancer at an early stage when tumor size is preferably smaller than 1 cm, lymph nodes are negative and there is no evidence of distant spread.^[4] As a primary method for screening, mammography has been established and shown to reduce mortality from breast cancer about 30-50%.^[5,6] But still, in screening with mammography the sensitivity to nonpalpable cancer in women with

dense breasts is as low as 30-48%.^[7] This is more important in Iranian breast cancer women whom are diagnosed at the younger age (10 years younger than western countries), and so the density of mammary tissue is higher.^[8-10] In addition, dense breast tissue is an independent marker that strongly associated with breast cancer risk especially in subjects with higher risk of interval cancer that is, cancer detected between screening tests.^[11,12] The performance of this method is reduced to detection of cancer in women with dense breast because mammograms are summation images, and all of breast tissue overlap in each view; so because of overlying dense breast tissue, cancers may not be seen.^[13]

American Cancer Society has recommended magnetic resonance imaging to screen women who are very high risk for breast cancer, but it carry risks of the contrast media and is costly.^[14] Screening with a supplemental

Address for correspondence: Prof. Atoosa Adibi, Department of Radiology, Alzahra Hospital, Sofeh Street, Isfahan, Iran.
E-mail: a_adibi@med.mui.ac.ir

Received: 27-12-2014; **Revised:** 08-02-2015; **Accepted:** 09-03-2015

ultrasound (US) has the potential to identify early, node-negative cancers that not seen on mammography.^[7] It has been greatly reported that in diagnosis of breast cancer US is more sensitive than mammography and had been shown to identify mammographically occult breast cancers in dense breasts.^[5,15-17] It is easily available and is largely inexpensive.

Ultrasound images the tissue to the chest wall; it is a cross-sectional technique, which displays the tissue without overlap.^[18,19] However, the skill and time that is necessary to detect nonpalpable, small tumors with hand-held imaging has reduced widespread use of US and shortage of qualified personnel and lack of the uniformity limit wide implementation of this method. Low specificity of US can lead to higher rates of false positive results.^[9]

Previous studies showed different results; most of them concluded the possibility that ultrasonography may identify occult breast carcinoma in dense breasts.^[20-22] But some showed a low cancer detection rate of ultrasonography in dense breasts and stated that adding ultrasonography to negative mammography seems to have limited cost-effectiveness and is controversial for women who have no major risk factors other than dense breasts.^[23,24]

However, women who have a personal history of breast cancer are at increased risk of contralateral interval cancer, so a tailored screening method should be used in this group of patients.^[25]

In this study, we aimed to assess the role of breast ultrasonography as a complement to unilateral mammography in screening of radiologically dense breasts in patients with unilateral previous mastectomy and no obvious new density in comparison to previous mammograms.

MATERIALS AND METHODS

Study design and participants

This was a cross-sectional study, which was carried out on 2012-2013. The study followed the Declaration of Helsinki on Biomedical Research Involving Human Subjects and was approved by the Ethics Committee from the Isfahan University of Medical Sciences. All participants provided written or oral informed consent.

The American College of Radiology (ACR) has developed a Breast Imaging Reporting And Data System (BI-RADS) classification for breast US examinations in 2003,^[26] which is analogous to the BI-RADS classification for mammography, categorizing from ACR 1 to 5.^[27] The supplemental US for the detection of cancer are primarily

appropriate for women with ACR breast density 3 or 4, because >90% of the women in whom cancer was detected by US had ACR breast density 3 or 4.^[23,28] Also based on ACR BI-RADS category for probability of malignancy in mammographic and ultrasonographic findings, BI-RADS categories 1-2 indicate negative or benign findings respectively, and BI-RADS categories 3-5 indicate probably benign, suspicious abnormality, and highly suggestive of malignancy. Category 0 is set for results that require additional imaging due to limited assessment.^[27] Subjects were chosen from patients who came to seyed al shohada Hospital (Isfahan, Iran) for routine mammographic yearly screening, after mastectomy. All subjects met the following inclusion criteria:

1. 18-65 years aged women;
2. Asymptomatic subjects with previous history of unilateral mastectomy due to a known breast cancer;
3. Having at least one previous contralateral mammography through past years with ACR breast density 2-4 (scattered fibroglandular densities, heterogeneously dense or extremely radiographically dense breasts);
4. Presence of no new density in new mammography in comparison with previous mammography for subjects with ACR breast density 3-4;
5. Diagnosed with BI-RADS category 1-2 for malignancy for subjects with ACR density 2 in both consecutive mammograms.

A total of 267 individuals screened and 153 subjects met all inclusion and no exclusion criteria who assigned to study [Flow Chart 1]. There were 28 subjects with ACR breast density 2 and 125 with ACR breast density 3-4. We assumed subjects with ACR breast density 3-4 as BI-RADS category 0 for malignancy. Two subjects dropped out in the study process because of not participating in US imaging. Demographic data included age, duration of mastectomy and family history.

Procedures and variables assessment

Mammograms were carried out with a Planmeca device in standard cranio-caudal and medio-lateral oblique views, and breast US examinations were performed on a general electric S6 with a multi frequency linear probe (10-14 MHz). The breasts were scanned in radial and anti-radial planes. US examination was performed by an expert radiologist.

Physicians who did the US were blinded for results of mammography.

Statistical methods

Independent samples test and Fisher's exact test were used for analysis. Data were analyzed by SPSS version 20.0 (SPSS Inc., Chicago, Illinois, USA). A $P < 0.05$ was considered

as statistically significant. Continuous variables were expressed as mean (standard deviation [SD]).

RESULTS

From 153 subjects, there were 28 (18.3%) subjects with ACR breast density 2 and 125 (81.7) with ACR breast density 3-4. In 28 subjects with ACR breast density 2, there were 16 (7.8%) subjects with BI-RADS 1, and 12 (10.5%) subjects with BI-RADS 2.

Mean (SD) age of 153 participants was 44.5 (9.6) years (range, 29-61 years). They were all asymptomatic with no known clinical findings. The mean (SD) years from mastectomy was 3.6 (1.1) years (range, 2-6 years).

In these participants, 16 (10.5%) subjects had family history of first degree relatives with breast cancer while 13 (8.5%) had family history of second-degree relatives with breast cancer. Three (1.1%) subjects had both family history of first- and second-degree relatives with breast cancer.

The subjects with ACR breast density 3-4 and ACR breast density 2, didn't differ in age, years of mastectomy and family history of breast cancer, significantly [Table 1].

After screening with US, all of subjects with BI-RADS 0 in mammography who didn't have any new density, diagnosed with BI-RADS 1-2 ultrasonographically; there were 89 (71.8%) subjects with BI-RADS 1 and 35 (28.2%) subjects with BI-RADS 2.

Also all of the subjects with BI-RADS 1-2 in mammography, diagnosed with the BI-RADS 1 or 2 ultrasonographically; there were 15 (55.5%) subjects with BI-RADS 1 and 12 (44.4%) subjects with BI-RADS 2. Four patients with BI-RADS 2 in mammography diagnosed with BI-RADS 1 in US assessment; they had arterial calcification that is not detectable with US.

There was no one with BI-RADS 3-5 in all of the 151 subjects who screened by US [Table 2].

Table 1: Demographics and clinical characteristics of subjects (n = 153)

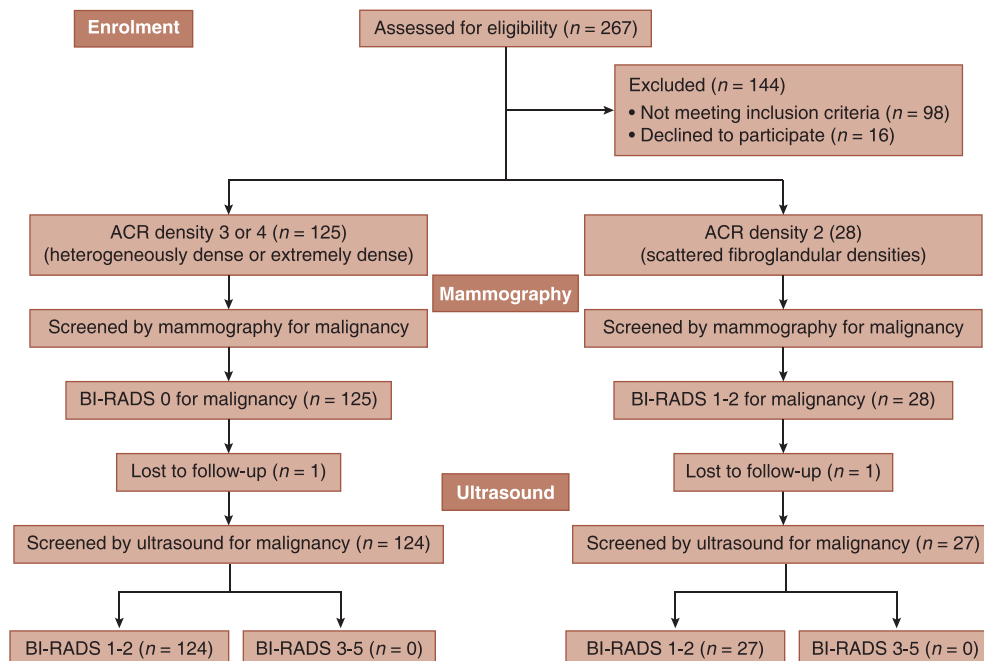
Characteristics	ACR density 3-4 (n = 125)	ACR density 2 (n = 28)	P
Age, mean (SD) year	44.9 (9.6)	42.3 (9.8)	0.206
Mastectomy duration, mean (SD) year	3.5 (1.1)	3.2 (1.2)	0.126
Family history			
First degree	11 (8.8)	5 (17.8)	0.174
Second degree	10 (8.0)	3 (10.7)	0.707

All variables are number (%) unless otherwise indicated; P value is extracted from independent samples test and Fisher's exact test; ACR = American college of radiology; SD = Standard deviation

Table 2: BI-RADS category for malignancy after ultrasound screening (n = 151)

Ultrasound	BI-RADS (0) in mammography (n = 124)	BI-RADS (1) in mammography (n = 12)	BI-RADS (2) in mammography (n = 15)
BI-RADS 1	89 (71.8)	7 (58.3)	8 (53.3)
BI-RADS 2	35 (28.2)	5 (41.7)	7 (46.7)
BI-RADS 3-5	0 (0)	0 (0)	0 (0)

All variables are number (%); BI-RADS = Breast imaging reporting and data system



Flow Chart 1: Study design flow chart

DISCUSSION

The use of supplemental US for the detection of breast cancer is recommended as a supplemental screening for women who have dense breasts.^[7] In this study, we assessed the usefulness of this method as a complement to mammography in screening of radiologically dense breasts other than essentially fatty (ACR breast density 2-4) for malignancy.

The results showed that in subjects with ACR breast density 3-4, when there was no new density in two consecutive mammograms, US also showed no possibility for malignancy (BI-RADS 1-2). And also in subjects with ACR breast density 2, when the mammographic results were BI-RADS 1-2, the US results was the same.

This is in against with some recent studies. Leong *et al.* revealed the relevant of supplementary US screening in identifying early stage clinically and mammographically occult breast cancers in dense breast women.^[29] Also, Shen *et al.* and Parris *et al.* showed that US is more sensitive than mammography for early detecting of breast cancer. They concluded that formal screening breast US as an adjunct to mammography increases cancer detection rate.^[30,31]

On the other hand, this is consistent with Brancato *et al.* study that showed a low cancer detection rate, considerably lower compared to other clinical studies of US in dense breasts.^[23] They stated that adding US to negative mammography in dense breasts seems to have limited cost-effectiveness, and should not be used in routine practice. Also, sickles concluded that the use of screening US remains controversial between women who have no major risk factors other than dense breasts.^[24]

One of possible adverse effects of additional breast US is more rates of biopsy in the evaluated subjects (2.3-4.7%), which is substantially higher than the biopsy rates of about 1-2% resulting from mammographic screenings.^[32] In addition, as the major limitation of US, is its low specificity, after biopsy the positive predictive value of US (mean 10.3%) was significantly lower than that of mammography (mean 38%),^[33,34] that is, 3 times more subjects need to undergo a biopsy per cancer detected. Although findings identified by US can be biopsied easily in a minimally-invasive procedure, the psychological stress that women experience for biopsy because of a false-positive US result should be considered.

There is a need for prospective studies of second-line, risk-adjusted, supplemental breast US screening in women with dense breast, performed within the frame work of population-based mammography screening-programs.

ACKNOWLEDGMENT

The authors wish to thank the collaboration of radiology service of Seyed al Shohada hospital and also the Isfahan University of Medical Sciences (Isfahan, Iran) supports.

AUTHOR'S CONTRIBUTION

AA contributed in the conception of the work, conducting the study, revising the draft, approval of the final version of the manuscript, and agreed for all aspects of the work. MG contributed in the conception of the work, conducting the study, revising the draft, approval of the final version of the manuscript, and agreed for all aspects of the work. MS contributed in the conception of the work, revising the draft, approval of the final version of the manuscript, and agreed for all aspects of the work. KK contributed in the conception and design of the work, data analysis, writing the draft, approval of the final version of the manuscript, and agreed for all aspects of the work.

REFERENCES

1. Akbari ME, Khayamzadeh M, Abachzadeh K. Iran Cancer Report, Cancer Research Center. Tehran, Qom: Darolfekr, Shahid Beheshti University of Medical Sciences; 2008.
2. Jemal A, Siegel R, Xu J, Ward E. Cancer statistics, 2010. *CA Cancer J Clin* 2010;60:277-300.
3. Gail MH, Brinton LA, Byar DP, Corle DK, Green SB, Schairer C, *et al.* Projecting individualized probabilities of developing breast cancer for white females who are being examined annually. *J Natl Cancer Inst* 1989;81:1879-86.
4. Michaelson JS, Silverstein M, Sgroi D, Cheongsiamtoy JA, Taghian A, Powell S, *et al.* The effect of tumor size and lymph node status on breast carcinoma lethality. *Cancer* 2003;98:2133-43.
5. Mainiero MB, Lourenco A, Mahoney MC, Newell MS, Bailey L, Barke LD, *et al.* ACR Appropriateness Criteria Breast Cancer Screening. *J Am Coll Radiol* 2013;10:11-4.
6. Feig S. Comparison of costs and benefits of breast cancer screening with mammography, ultrasonography, and MRI. *Obstet Gynecol Clin North Am* 2011;38:179-96, ix.
7. Kelly KM, Dean J, Comulada WS, Lee SJ. Breast cancer detection using automated whole breast ultrasound and mammography in radiographically dense breasts. *Eur Radiol* 2010;20:734-42.
8. Attarian H, Pirzadeh A, Rezvani H, Esfahani F, Tabarraei M, Ghadiani M, *et al.* Clinico-pathologic manifestations of Iranian patients with breast cancer. *Pak J Med Sci* 2011;27:182-5.
9. Berg WA, Blume JD, Cormack JB, Mendelson EB, Lehrer D, Böhm-Vélez M, *et al.* Combined screening with ultrasound and mammography vs mammography alone in women at elevated risk of breast cancer. *JAMA* 2008;299:2151-63.
10. Han JG, Jiang YD, Zhang CH, Pang D, Zhang M, Wang YB, *et al.* Clinicopathologic characteristics and prognosis of young patients with breast cancer. *Breast* 2011;20:370-2.
11. Boyd NF, Guo H, Martin LJ, Sun L, Stone J, Fishell E, *et al.* Mammographic density and the risk and detection of breast cancer. *N Engl J Med* 2007;356:227-36.
12. Kerlikowske K, Ichikawa L, Miglioretti DL, Buist DS, Vacek PM, Smith-Bindman R, *et al.* Longitudinal measurement of clinical

- mammographic breast density to improve estimation of breast cancer risk. *J Natl Cancer Inst* 2007;99:386-95.
13. Birdwell RL, Ikeda DM, O'Shaughnessy KF, Sickles EA. Mammographic characteristics of 115 missed cancers later detected with screening mammography and the potential utility of computer-aided detection. *Radiology* 2001;219:192-202.
 14. Kelly KM, Richwald GA. Automated whole-breast ultrasound: Advancing the performance of breast cancer screening. *Semin Ultrasound CT MR* 2011;32:273-80.
 15. Huang Y, Kang M, Li H, Li JY, Zhang JY, Liu LH, *et al.* Combined performance of physical examination, mammography, and ultrasonography for breast cancer screening among Chinese women: A follow-up study. *Curr Oncol* 2012;19:eS22-30.
 16. Lehman CD, Lee CI, Loving VA, Portillo MS, Peacock S, DeMartini WB. Accuracy and value of breast ultrasound for primary imaging evaluation of symptomatic women 30-39 years of age. *AJR Am J Roentgenol* 2012;199:1169-77.
 17. Newell MS, Birdwell RL, D'Orsi CJ, Bassett LW, Mahoney MC, Bailey L, *et al.* ACR Appropriateness Criteria® on nonpalpable mammographic findings (excluding calcifications). *J Am Coll Radiol* 2010;7:920-30.
 18. Benson SR, Blue J, Judd K, Harman JE. Ultrasound is now better than mammography for the detection of invasive breast cancer. *Am J Surg* 2004;188:381-5.
 19. Berg WA, Gutierrez L, NessAiver MS, Carter WB, Bhargavan M, Lewis RS, *et al.* Diagnostic accuracy of mammography, clinical examination, US, and MR imaging in preoperative assessment of breast cancer. *Radiology* 2004;233:830-49.
 20. Weigert J, Steenbergen S. The connecticut experiments second year: Ultrasound in the screening of women with dense breasts. *Breast J* 2015;21:175-80.
 21. Venturini E, Losio C, Panizza P, Rodighiero MG, Fedele I, Tacchini S, *et al.* Tailored breast cancer screening program with microdose mammography, US, and MR Imaging: Short-term results of a pilot study in 40-49-year-old women. *Radiology* 2013;268:347-55.
 22. Hooley RJ, Greenberg KL, Stackhouse RM, Geisel JL, Butler RS, Philpotts LE. Screening US in patients with mammographically dense breasts: Initial experience with Connecticut Public Act 09-41. *Radiology* 2012;265:59-69.
 23. Brancato B, Bonardi R, Catarzi S, Iacconi C, Risso G, Taschini R, *et al.* Negligible advantages and excess costs of routine addition of breast ultrasonography to mammography in dense breasts. *Tumori* 2007;93:562-6.
 24. Sickles EA. The use of breast imaging to screen women at high risk for cancer. *Radiol Clin North Am* 2010;48:859-78.
 25. Houssami N, Abraham LA, Kerlikowske K, Buist DS, Irwig L, Lee J, *et al.* Risk factors for second screen-detected or interval breast cancers in women with a personal history of breast cancer participating in mammography screening. *Cancer Epidemiol Biomarkers Prev* 2013;22:946-61.
 26. Mendelson EB, Baum JK, Berg WA, Merritt CB, Rubin E. Breast Imaging Reporting and Data System BIRADS: Ultrasound. American College of Radiology; 2003.
 27. D'Orsi DB, Berg W. Breast Imaging Reporting and Data System, BI-RADS: Mammography. Reston, VA: American College of Radiology; 2003.
 28. Berg WA. Supplemental screening sonography in dense breasts. *Radiol Clin North Am* 2004;42:845-51, vi.
 29. Leong LC, Gogna A, Pant R, Ng FC, Sim LS. Supplementary breast ultrasound screening in Asian women with negative but dense mammograms-a pilot study. *Ann Acad Med Singapore* 2012;41:432-9.
 30. Shen SJ, Sun Q, Xu YL, Zhou YD, Guan JH, Mao F, *et al.* Comparative analysis of early diagnostic tools for breast cancer. *Zhonghua Zhong Liu Za Zhi* 2012;34:877-80.
 31. Parris T, Wakefield D, Frimmer H. Real world performance of screening breast ultrasound following enactment of Connecticut Bill 458. *Breast J* 2013;19:64-70.
 32. Morton MJ, Whaley DH, Brandt KR, Amrami KK. Screening mammograms: Interpretation with computer-aided detection — Prospective evaluation. *Radiology* 2006;239:375-83.
 33. Cupples TE, Cunningham JE, Reynolds JC. Impact of computer-aided detection in a regional screening mammography program. *AJR Am J Roentgenol* 2005;185:944-50.
 34. Berg WA. Rationale for a trial of screening breast ultrasound: American College of Radiology Imaging Network (ACRIN) 6666. *AJR Am J Roentgenol* 2003;180:1225-8.

Source of Support: Nil, **Conflict of Interest:** None declared.