

Hydatid cyst with intracavitary fungal ball: Does it require lung resection?

Sir,

An association of echinococcal pulmonary hydatid cyst with fungal infection is rarely seen in humans.^[1,2] We detected a cystic lesion located in the left lung with chest radiographic examination in a 24-year-old female patient that had been suffering from back pain and cough for a month. Cystic lesion was visualized with a size of 24 mm × 13 mm in the superior segment of inferior lobe of the left lung by computed tomography (CT).

The patient was surgically treated. The cystic cavity was drained and obliterated using cystectomy and capitonage techniques. Betadine® (povidine iodine 10% (Betadine solution; Purdue Frederick Co., Norwalk, CT, USA)) solution was used as a germicidal agent, and hypertonic NaCl was applied for drainage. The bronchial openings in the cavity were closed by nonabsorbable suture materials [Figure 1]. Typical *Aspergillus* hyphae and perforated, lamellar and the necrotic membrane of the hydatid cyst were visualized by histopathological examination of cyst contents. Findings were compatible with fungus ball that developed on the basis of a hydatid cyst [Figure 1].

The patient did not have any postoperative complications and was not administered albendazole for hydatid cyst or itraconazole for aspergillosis. A CT examination that was taken at the postoperative 6th month was clear, suggesting full recovery of the disease [Figure 2].

Secondary infections, which develop due to ruptured hydatid cysts in the bronchial system, are usually bacterial; however, they are rarely caused by fungal infection. Radiological findings may lead to suspicion of the disease, it does not provide clear and specific data. Definitive data is usually obtained through surgery^[1] and this co-infection is determined incidentally.

When the presence of aspergilloma is known in the preoperative period, the most common surgical approach would be a lung resection in patients with an adequate pulmonary reserve.^[2] On the other hand, there is no doubt regarding the closing of bronchial openings in the cavity and complete operation by cystectomy-capitonage in cases of small hydatid cyst cavity with noncomplicated, noninvasive

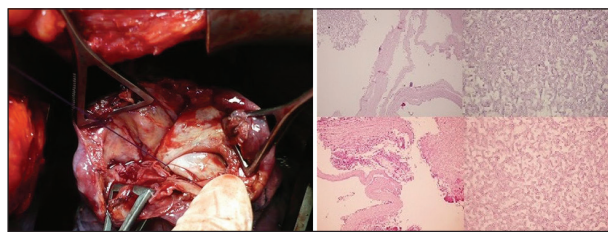


Figure 1: The left panel shows operative view of the opened hydatid cyst cavity, and the right panel shows histopathological examination showing typical *Aspergillus* hyphae and membrane of the hydatid cyst (H and E, ×40) and *Aspergillus* hyphae making a 45° angle on the fungus ball (H and E, ×400)

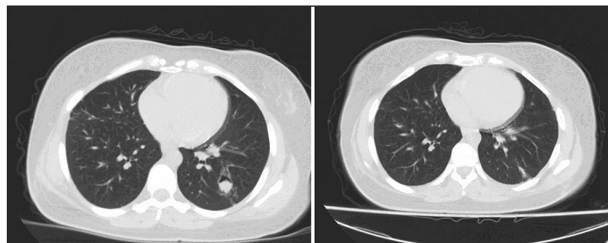


Figure 2: The left panel shows computed tomography (CT) image of the patient before surgery and the right panel shows CT image of the patient postoperative 6th month

aspergilloma when adequate sterilization can be accommodated, as in the current case. However, further research is required to determine the optional therapeutic approach in patients with insufficient pulmonary reserves and to avoid pulmonary resection.

AUTHOR'S CONTRIBUTION

SY contributed in the conception of the work, conducting the study, revising the draft, approval of the final version of the manuscript, and agreed for all aspects of the work. SG contributed in the conception of the work, drafting and revising the draft, approval of the final version of the manuscript, and agreed for all aspects of the work. OU contributed in the conception of the work, conducting the study, revising the draft, approval of the final version of the manuscript, and agreed for all aspects of the work. AU contributed in the conception of the work, revising the draft, approval of the final version of the manuscript, and agreed for all aspects of the work.

Serkan Yazgan, Soner GURSOY, Ozan USLUER, Ahmet UCIVET

Department of Thoracic Surgery, Izmir Dr. Suat Seren Chest Diseases and Thoracic Surgery Training and Research Hospital, Izmir, Turkey

Address for correspondence: Dr. Serkan Yazgan, Department of Thoracic Surgery, Izmir Dr. Suat Seren Chest Diseases and Thoracic Surgery Training and Research Hospital, Izmir, Turkey.
E-mail: serkanyazgan@gmail.com

REFERENCES

1. Manzoor MU, Faruqi ZS, Ahmed Q, Uddin N, Khan A. Aspergilloma complicating newly diagnosed pulmonary echinococcal (hydatid) cyst: A rare occurrence. *Br J Radiol* 2008;81:e279-81.
2. Vasquez JC, Montesinos E, Rojas L, Peralta J, Delarosa J, Leon JJ. Surgical management of *Aspergillus* colonization associated with lung hydatid disease. *Ann Thorac Cardiovasc Surg* 2008;14:116-8.