

Mucinous adenocarcinoma of the appendix

Sir,

Primary tumors of the appendix are unusual, and most of them (almost 85%) are carcinoids.^[1] Adenocarcinomas of the appendix are rare entities, representing <0.5% of all gastrointestinal malignancies and 4-6% over lesions of the appendix neoplasm.^[2] In one series, the age-adjusted incidence of cancer of the appendix was 0.12 cases per 1,000,000 people per year.^[3] Here, we report a case of a mucinous adenocarcinoma of the appendix, the workup of the diagnosis, and treatment results.

A 72-year-old woman was admitted to our hospital with a right lower abdominal mass, without any other complaints. The patient did not report any alteration of bowel habits or body weight loss. On admission, vital signs were stable. On examination of the abdomen, she had a painless soft lump in the right lower abdomen. All initial laboratory findings were normal. Computed tomography (CT) revealed a large cystic mass with irregular margins measuring 8.6 cm × 7.5 cm × 6.2 cm in the right lower abdominal cavity [Figure 1].

Exploration was performed through a midline incision. During the operation, a large gelatinous collection was found around the appendix [Figure 2]. The origin of the mass was tip of the appendix and was extended from the liver to the pelvic. Liver, uterus, and ovaries were intact. There was no lymphadenopathy. The patient underwent appendectomy, resection of the mass and peritoneal washing. The histopathological examination of the specimen surprisingly revealed a mucinous adenocarcinoma of the appendix [Figure 3]. A total colonoscopy and baseline tumor markers (carcinoembryonic antigen, CA-125, CA-19-9) were normal. The patient was referred to oncology center, and six cycles of FOLFOX chemotherapy were administered.

The patient was then scheduled for a second operation and underwent a right hemicolectomy, which is proposed as the treatment of choice for this type of neoplasms. There was no evidence of synchronous ovarian tumor, but in order to avoid the risk of recurrence and given the age of the patient, bilateral oophorectomy was performed. No metastases were observed during the hospitalization and surveillance of 1-year. The colonoscopy and CT scan were performed 1-year later and did not reveal any malignant tumor.

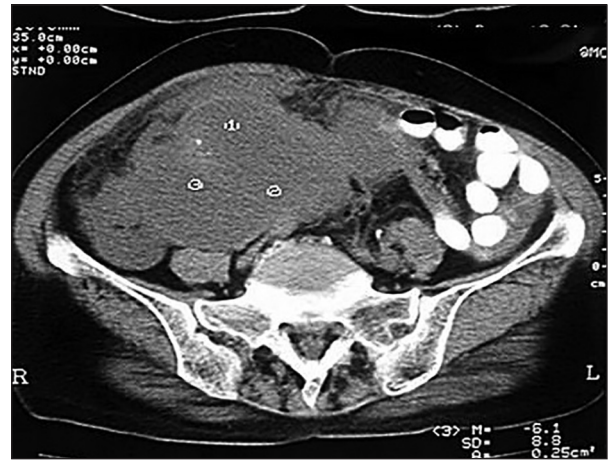

Figure 1: Computed tomography revealed a large cystic mass with irregular margins measuring 8.6 cm × 7.5 cm × 6.2 cm in the right lower abdominal cavity

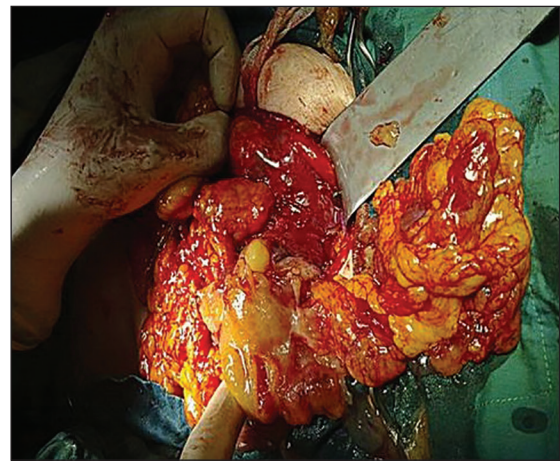


Figure 2: During the operation a large gelatinous collection was found around the appendix

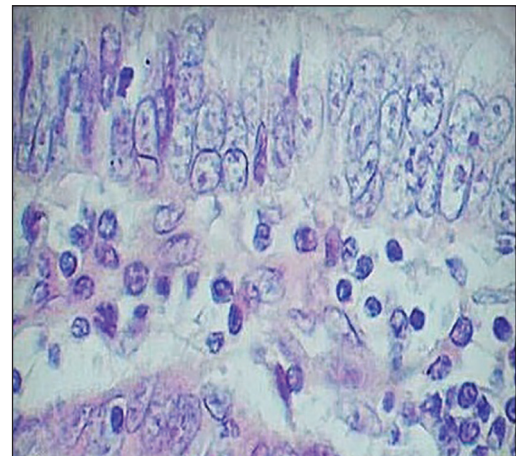


Figure 3: Tumor cells contain mucin with the invasion of the muscular layer of the appendix

In conclusion, primary adenocarcinoma of the appendix has diverse clinical manifestations. Recognition of carcinoma in the presence of an acutely inflamed appendix is difficult. Surgeons should keep in mind

the possibility of primary appendicular malignancy when managing patients with suspected appendicular mass or acute appendicitis. Intraoperative diagnosis requires a high index of suspicion, careful intra-abdominal examination, frozen sections of all suspicious appendices, and permanent sections of all appendices. To improve the outcome, right hemicolectomy should be recommended.

AUTHOR'S CONTRIBUTION

IF, NM and ZT designed the study and were responsible for the overall study management. NM and IF prepared the manuscript. All authors approved the final version of the manuscript, and agreed for all aspects of the work.

Iraj Feizi, Nasrollah Maleki¹, Zahra Tavosi¹

Department of Surgery, School of Medicine,
Imam Khomeini Hospital, Ardabil University of Medical Sciences,

Ardabil, ¹Department of Internal Medicine, School of Medicine,
Shohadaye Khalije Fars Hospital, Bushehr University of Medical
Sciences, Bushehr, Iran

Address for correspondence: Dr. Nasrollah Maleki,
Department of Internal Medicine, Shohadaye Khalije Fars Hospital,
Bushehr University of Medical Sciences, Bushehr, Iran.
E-mail: malekinasrollah@yahoo.com

REFERENCES

1. Pickhardt PJ, Levy AD, Rohrmann CA Jr, Kende AI. Primary neoplasms of the appendix: Radiologic spectrum of disease with pathologic correlation. *Radiographics* 2003;23:645-62.
2. Connor SJ, Hanna GB, Frizelle FA. Appendiceal tumors: Retrospective clinicopathologic analysis of appendiceal tumors from 7,970 appendectomies. *Dis Colon Rectum* 1998;41:75-80.
3. McCusker ME, Coté TR, Clegg LX, Sobin LH. Primary malignant neoplasms of the appendix: A population-based study from the surveillance, epidemiology and end-results program, 1973-1998. *Cancer* 2002;94:3307-12.