

# Photorefractive keratectomy in the management of postradial keratotomy hyperopia and astigmatism

Mohammad Ghoreishi, Mohammad-Ali Abtahi<sup>1,2</sup>, Iman Seyedzadeh<sup>1,2</sup>, Hamid Fesharaki<sup>1,2</sup>, Mohadeseh Mohammadnia<sup>1,2</sup>, Hamidreza Jahanbani-Ardakani<sup>3,4</sup>, Seyed-Hossein Abtahi<sup>1,2,3</sup>

Research and Development Department, Persian Eye Clinic, <sup>1</sup>Isfahan Eye Research Center, Feiz Eye Hospital, Isfahan University of Medical Sciences, <sup>2</sup>Department of Ophthalmology, Feiz Eye Hospital, Isfahan University of Medical Sciences, <sup>3</sup>Isfahan Medical Students Research Center, Isfahan University of Medical Sciences, <sup>4</sup>Student of Medicine, Faculty of Medicine, Isfahan University of Medical Sciences, Isfahan, Iran

**Background:** The aim of this study is to evaluate the results of photorefractive keratectomy (PRK) in the management of postoperative hyperopia and astigmatism in patients with history of radial keratotomy (RK). **Materials and Methods:** This prospective nonrandomized noncomparative interventional case series enrolled consecutive eyes treated with PRK after RK. In cases, in which (1) wavefront (WF) scan was undetectable during primary examinations; and/or, (2) WF data were not transferable to the excimer laser device, patients were treated with the tissue-saving (TS) mode. Patients with detectable/transferable WF were assigned to WF-guided advanced personalized treatment (APT). **Results:** Thirty-two and 47 eyes were managed by APT and TS modes, respectively. Pooled analysis of both APT and TS groups showed improvement in uncorrected distant visual acuity and corrected distant visual acuity. The amount of sphere, cylinder, corneal cylinder, spherical equivalent, defocus equivalent, and total aberration showed improvement as well. **Conclusion:** PRK seems to bring favorable outcome and safety profile in the management of post-RK hyperopia and astigmatism. It is crucial for practitioners to warn their patients about the fact that they may still have progressive refractive instability regardless of their choice on the laser method of vision correction.

**Key words:** Astigmatism, hyperopia, mitomycin-C, photorefractive keratectomy, radial keratectomy

**How to cite this article:** Ghoreishi M, Abtahi MA, Seyedzadeh I, Fesharaki H, Mohammadnia M, Jahanbani-Ardakani H, et al. Photorefractive keratectomy in the management of postradial keratotomy hyperopia and astigmatism. *J Res Med Sci* 2017;22:82.

## INTRODUCTION

Radial keratotomy (RK) is now named as an obsolete procedure though by its advent in 1980's RK had been considered to be a reasonable treatment for low to moderate degrees of myopia.<sup>[1,2]</sup> As regards, the procedure of RK, 90%–95% radial incisions on the cornea were made to produce peripheral steepening and central flattening. The main complication of RK over the ensuing postoperative years has been refractive instability and progressive hyperopia.<sup>[3,4]</sup> Since 1991, photorefractive keratectomy (PRK) has been used to correct residual refractive errors of RK.<sup>[5]</sup>

In clinical practice, there may be situations, in which an ophthalmologist visits a patient with severe post-RK refractive errors; herein comes the question of whether further surgical procedures bring acceptable refractive efficacy and safety.

Before 2000, to correct patients' residual refractive errors, RK and laser refractive procedures were applied interchangeably.<sup>[6,7]</sup> In the literature, post-RK laser *in situ* keratomileusis (LASIK) has been acknowledged as a reasonable choice to correct the residual refractive errors;<sup>[8-13]</sup> however, LASIK flap complications, epithelial ingrowths, and keratectasia are not uncommon.<sup>[14-16]</sup>

Regarding the use of PRK, existing literatures lack consensus and none of the therapeutic procedures

Access this article online	
Quick Response Code:	Website: www.jmsjournal.net
	DOI: 10.4103/jrms.JRMS_478_15

This is an open access article distributed under the terms of the Creative Commons Attribution-NonCommercial-ShareAlike 3.0 License, which allows others to remix, tweak, and build upon the work non-commercially, as long as the author is credited and the new creations are licensed under the identical terms.

**For reprints contact:** reprints@medknow.com

**Address for correspondence:** Dr. Mohammad-Ali Abtahi, Feiz Hospital, Qods Square, Isfahan, Iran. E-mail: sma.abtahi63@gmail.com

**Received:** 15-09-2015; **Revised:** 24-02-2016; **Accepted:** 16-04-2017

put forward therein are completely convincing.<sup>[17]</sup> One of the protocols employs off-label use of intraoperative mitomycin-C (MMC) which can effectively control cornea haze as a major complication of post-RK PRK.<sup>[18-20]</sup> As far as, we have been able to ascertain, the only recent large report on this topic comes from Brazil that enrolled 61 eyes,<sup>[21]</sup> since then few large series of patients has yet to be studied.<sup>[22,23]</sup> The present study was planned to address this topic and evaluate the refractive efficacy and safety of PRK with MMC in the management of post-RK hyperopia and astigmatism in a large Iranian cohort.

## MATERIALS AND METHODS

### Study design and ethics

This prospective nonrandomized, noncomparative, interventional case series enrolled consecutive eyes treated with PRK after RK in Iran between April 2012 and December 2014. All procedures were performed by 1 surgeon (M. G.) using a uniform technique with one protocol.

Patients had a positive defocus equivalent (consecutive hyperopia after primary RK surgery).

To minimize the difference of corneal parameters in the morning and evening, all subjects had a concise preoperative examination at about 10 AM. Examinations were uncorrected distant visual acuity (UDVA), corrected distant visual acuity (CDVA), subjective/cycloplegic refraction, wavefront (WF) analysis with Hartman-Shack based Zywave aberrometer, and Pentacam topography (Pentacam HR, Oculus, Wetzlar, Germany).

The study protocol adhered to the tenets of the Declaration of Helsinki and was approved by the Ethics Committee of Isfahan University of Medical Sciences. Data collection was in conformity with country laws, and all of the patients were informed about every possible side effects of each procedure. Signed informed consent was obtained from each patient before inclusion. All of patients' data were recorded, documented, and reported confidentially.

### Patients and the participation criteria

Eighty eyes from 58 patients were enrolled at baseline. Subjects were eligible for participation if they were otherwise healthy, literate with history of RK surgery with refraction of + 8.0 diopters of hyperopia, and -7.0 diopters of astigmatism. Corneal thickness should have been 480  $\mu\text{m}$  or more.

The exclusion criteria of the study were cataract, keratoconus and corneal pathology, glaucoma and/or ocular hypertension, endocrine or collagen vascular diseases, diabetic retinopathy, pregnancy/lactation. Patients were also

excluded if they did not undergo follow-up examinations for 6 months [Flow Chart 1].

### Surgical method and postoperative care

Following a 5% povidone-iodine scrub of eyelids and face, topical tetracaine 1% was instilled into each eye preoperatively. After primary preparations, the 9 mm central cornea was deepithelized by a blunt spatula. The flying spot Technolas 217-z excimer system (Bausch and Lomb) was employed for laser ablation.

Patients were treated with two protocols based on the following criteria:

1. In cases, in which (1) WF scan was undetectable during primary examinations; and/or, (2) WF data were not transferable to the excimer laser device, patients were treated with the tissue-saving (TS) mode
2. Patients with detectable/transferable WF were assigned to WF-guided advanced personalized treatment (APT).

The amount of ablation performed was 90% of cycloplegic refraction. MMC 0.02% was applied to the stromal bed for up to 60 s; the surface was irrigated with a balanced salt solution. Then, topical ciprofloxacin drop was instilled, and soft bandage contact lenses (Acuvue; Johnson and Johnson Vision Care, Jacksonville, FL, USA) were administered.

Postoperatively, topical betamethasone 0.1% was used every 3 h and topical ciprofloxacin every 6 h. On the day 6 of follow-up, patients were assessed for complete corneal epithelial healing; and consequently, contact lenses were removed.<sup>[24]</sup>

Up to 1-month after surgery, Fluorometholone and Artelac drops were used every 6 h. At this time, patients were evaluated for their intraocular pressure. UDVA, CDVA, cycloplegic refraction, WF, and grade of haze formation were assessed at 6 months.

Using a questionnaire, patients were asked for the following objective items: overall satisfaction (as more than 80%, 60%–80%, 40%–60%, and <40%), excellence of day/night vision (as excellent, good, moderate, and weak), and severity of postoperative symptoms, i.e. halo, photophobia, pain, burn, drying, and burning (as nil, mild, moderate, and severe).

### Statistical measures

All data were collected in an Excel database (Microsoft Office 2003, Microsoft Corp.). Decimal UDVA and CDVA were converted from Snellen values to the logarithm of the minimum angle of resolution for statistical calculations.

Statistical analysis was performed using SPSS software version 13.0 (SPSS Inc., Chicago, IL, USA). Data were

expressed as means ± standard deviation and  $P < 0.05$  was considered statistically significant. Paired  $t$ -test was used to assess the difference between preoperative and postoperative data. Linear regression analysis was used for the evaluation of the correlation between intended and achieved correction. Chi-square test was used for the analysis of qualitative data.

## RESULTS

Of 58 patients included in the study, one missed the 6-months follow-up examinations and was excluded from our study. Of the rest of the patients, 18 were male, and 39 were female. Mean age was  $43.40 \pm 4.60$  with a range of 31–56 years. The majority of the eyes (73%) had 8 RK incisions; 21.6% and 5.4% had 6 and 4 RK incisions, respectively.

Thirty-two and 47 eyes were managed by APT and TS modes, respectively. Demographics, visual and refractive results of the patients are summarized in Tables 1 and 2.

Pooled analysis of both APT and TS groups showed improvement in UDVA and CDVA. The amount of sphere, cylinder, corneal cylinder, spherical equivalent, defocus equivalent, and total aberration showed improvement as well [Tables 1 and 2].

Changes in higher order and spherical aberration were not statistically significant ( $P = 0.670$  and  $0.405$ , respectively). Eighty-four percent of our patients achieved UDVA of 20/40 or better. Figure 1 shows that attempted spherical equivalent was strongly correlated with achieved one ( $R^2 = 0.8671$ ). Figure 2 depicts changes in pre- and post-operative astigmatism. Figures 3-5 show excellence of day/night vision, severity of postoperative symptoms, and overall satisfaction, respectively.

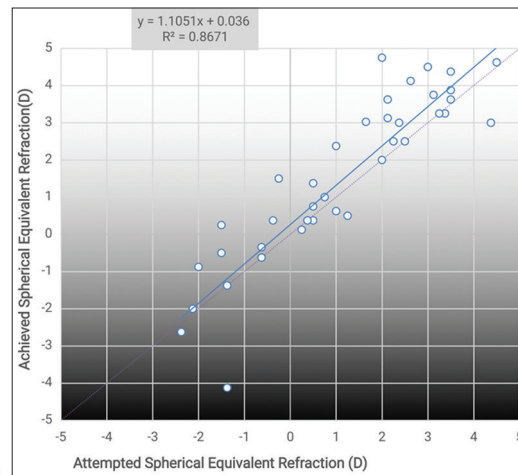


Figure 1: Spherical equivalent attempted versus achieved

Table 1: Visual and refractive parameters pre- and post-operative

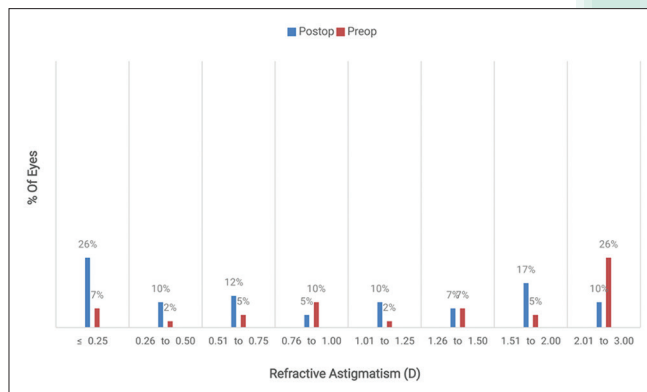
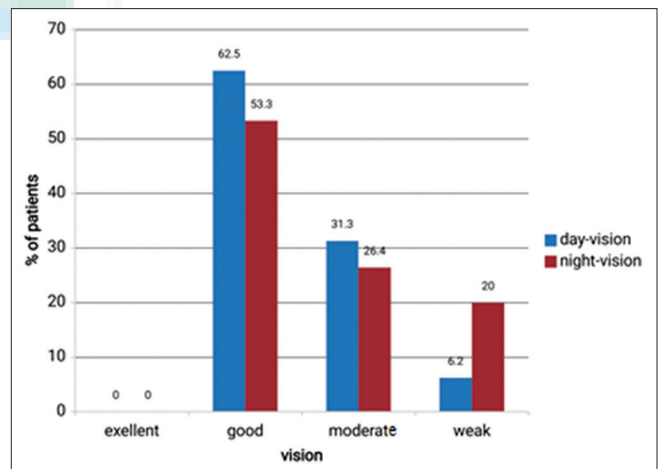
Group (n)	APT (32)	Tissue-saving (47)	Pooled analysis (79 eyes)
Male/female	11/21	16/31	27/52
Age (years), mean±SD (range)	43.33±6.4 (31-56)	43.43±3.8 (36-50)	43.4±4.6 (31-56)
UDVA (logMAR)			
Preoperative	0.49±0.35 (0.15-1.3)	0.45±0.37 (0.05-2)	0.46±0.36 (0.05-2)
Postoperative	0.12±0.13 (0-0.4)	0.23±0.18 (0-0.7)	0.2±0.17 (0-0.7)
P	0.002	0.001	0.000
CDVA (logMAR)			
Preoperative	0.16±0.16 (0-0.52)	0.18±0.13 (0-0.52)	0.18±0.13 (0-0.52)
Postoperative	0.07±0.12 (-0.04-0.4)	0.11±0.12 (0-0.52)	0.10±0.12 (-0.04-0.52)
P	0.006	0.009	0.000
Sphere (D)			
Preoperative	1.56±1.33 (0.0-4.0)	3.13±1.97 (0.0-7.0)	2.68±1.93 (0.0-7.0)
Postoperative	0.58±0.81 (0.0-1.75)	0.11±0.9 (-1.75-2.75)	0.24±0.89 (-1.75-2.75)
P	0.061	0.000	0.000
Cylinder (D)			
Preoperative	-2.77±1.46 (-5.25--0.75)	-2.8±2.04 (-8.00-0.0)	-2.8±1.87 (-8.0-0.0)
Postoperative	-0.62±0.69 (-1.75-0.0)	-1.37±1.0 (-3.5-0.0)	-1.15±0.98 (-3.5-0.0)
P	0.001	0.000	0.000
SE (D)			
Preoperative	0.18±1.81 (-2.37-3.12)	1.73±2.1 (-2.0-6.0)	1.29±2.12 (-2.37-6.0)
Postoperative	0.27±0.84 (-0.62±2.75)	-0.58±1.02 (-2.75-2.75)	-0.33±1.04 (-2.75-2.75)
P	0.387	0.000	0.000
DE (D)			
Preoperative	2.95±1.15 (1.37±5.5)	4.53±2.32 (0.62-9.37)	4.08±2.17 (0.62 to 9.37)
Postoperative	0.89±0.93 (0.0-2.75)	1.19±0.87 (0.0-3.62)	1.11±0.89 (0.0 to 3.62)
P	0.001	0.000	0.000

CDVA = Corrected distance visual acuity; DE = Defocus equivalent; logMAR = Logarithm of the minimum angle of resolution; SD = Standard deviation; SE = Spherical equivalent; UDVA = Uncorrected distance visual acuity; APT = Advanced personalized treatment

**Table 2: Aberrometry and keratometry parameters pre- and post-operative**

Group (n)	APT (32)	Tissue-saving (47)	Pooled analysis (79 eyes)
Total aberration (6 mm)			
Preoperative	4.16±1.23 (1.75-5.75)	4.67±1.94 (1.92-8.32)	4.47±1.69 (1.92-8.32)
Postoperative	2.39±0.64 (1.6-3.54)	2.97±1.09 (1.56-5.32)	2.74±0.97 (1.56-5.32)
P	0.000	0.000	0.000
Higher-order aberration (6 mm)			
Preoperative	1.28±0.47 (0.56-2.3)	1.98±0.91 (0.41-4.04)	1.67±0.83 (0.41-4.04)
Postoperative	1.29±0.54 (0.63-2.38)	1.63±0.61 (0.78-2.73)	1.59±0.59 (0.63-2.73)
P	0.901	0.031	0.670
Spherical aberration (6 mm)			
Preoperative	1.12±0.44 (0.54-2.22)	1.82±0.94 (0.24-3.89)	1.53±0.82 (0.24-3.89)
Postoperative	1.25±0.52 (0.62-2.28)	1.55±0.62 (0.57-2.73)	1.44±0.60 (0.57-2.73)
P	0.371	0.149	0.405
K <sub>min</sub> (D)			
Preoperative	37.69±2.63 (32.8-42.1)	35.09±4.42 (29.5-46.5)	35.83±4.13 (29.5-46.5)
Postoperative	38.4±3.31 (32-43.1)	37.95±3.77 (32-46.5)	38.08±3.61 (32-46.5)
P	0.259	0.000	0.000
K <sub>max</sub> (D)			
Preoperative	40.43±3.15 (36.8-46.3)	37.93±4.21 (32.4-48)	38.65±3.98 (32.4-48)
Postoperative	40.06±3.28 (32.9-44.9)	39.54±3.11 (32.9-48)	36.69±3.44 (32.9-48)
P	0.659	0.001	0.016
Average K (D)			
Preoperative	39.05±2.73 (34.7-44.0)	36.46±3.98 (31.5-47.3)	37.18±3.67 (31.5-47.3)
Postoperative	38.95±3.23 (32.4-43.7)	38.77±3.66 (32.4-47.3)	38.82±3.50 (32.4-47.3)
P	0.920	0.000	0.000
Corneal cylinder			
Preoperative	2.82±1.38 (0.6-5.0)	3.18±2.66 (0.3-11.5)	3.08±2.35 (0.3-11.5)
Postoperative	1.66±1.42 (0.2-5.0)	1.59±1.04 (0.2-4.1)	1.61±1.12 (0.2-5.0)
P	0.008	0.001	0.000

K = Keratometry; APT = Advanced personalized treatment

**Figure 2:** Refractive astigmatism**Figure 3:** Excellence of day/night vision

## DISCUSSION

For refractive surgeons, encountering RK patients with consecutive hyperopia is a challenging situation. This may come either from a primary overcorrection or from a progressive postoperative process. To manage such a complicated condition, LASIK and PRK have been proposed to be promising.<sup>[18-20]</sup> Although either mechanical microkeratome or the femtosecond LASIK surgeries have

shown favorable initial outcomes, such methods are not without complications.<sup>[18,19]</sup> Flap-related issues, especially epithelial in growth and splitting RK incisions can cause flap fragmentation along with the possibility corneal ectasia. Due to such possibilities, some authors believe that LASIK should be avoided in eyes with more than 8 RK incisions.<sup>[18,19]</sup> About the advantages of PRK over LASIK, the

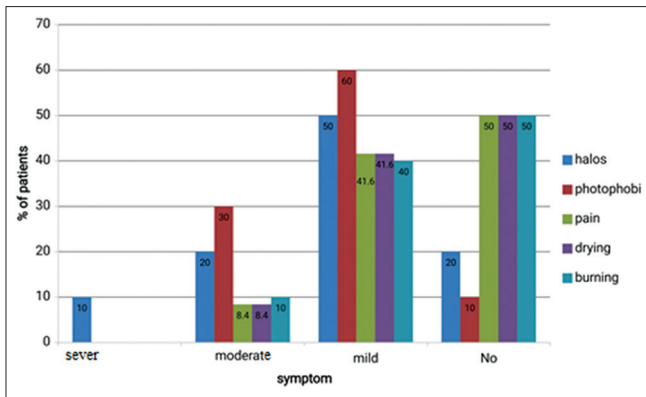


Figure 4: Severity of postoperative symptoms, 6 months postoperative

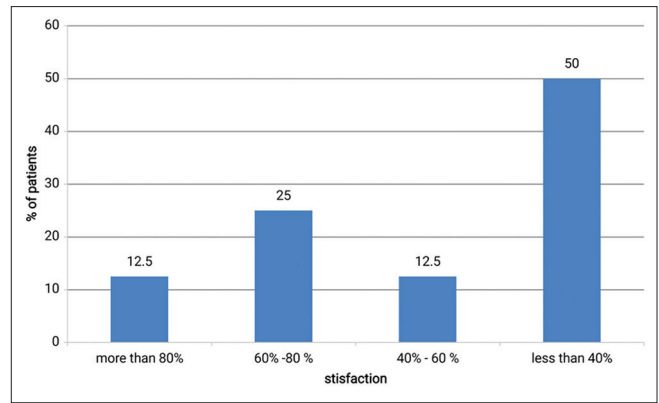
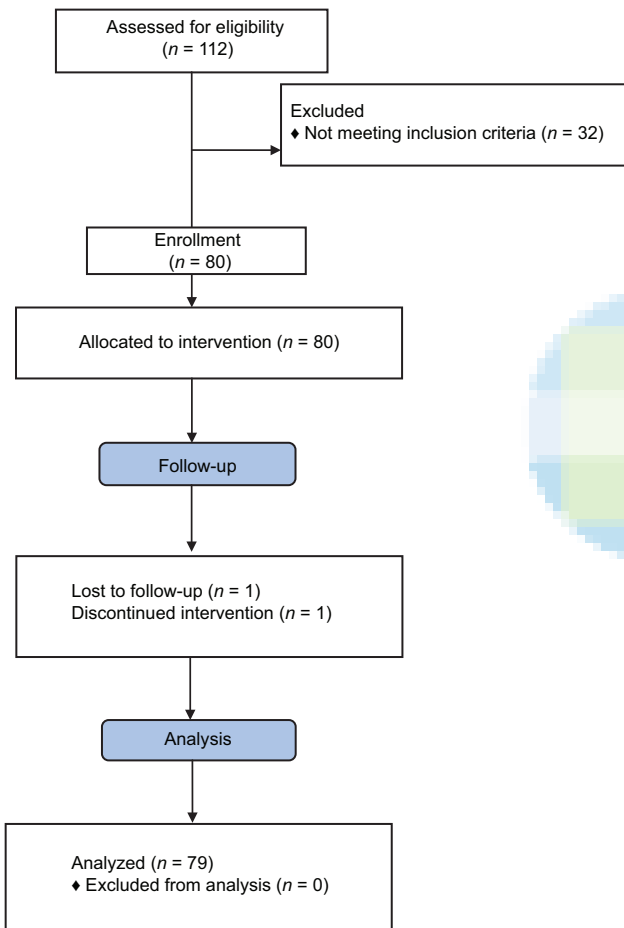


Figure 5: Overall satisfaction, 6 months postoperative



Flow Chart 1: Participants' flow

following points are noteworthy: first: PRK avoids additive weakening of the cornea, as a risk factor of ectasia; and second: PRK does not interrupt with RK incisions, saving the remaining corneal structural integrity.<sup>[20]</sup> Corneal ectasia has occurred neither in the present study nor in our daily practice over recent years. Taken together, based on the current literature on the management of post-RK hyperopia, PRK seems to be a reasonable method with a favorable safety profile. However, in this method, increased risk of

haze cannot be overlooked as a limitation in handling high hyperopia.<sup>[19]</sup> With administration of MMC in PRK, corneal haze has become less important.<sup>[20]</sup> In some reports, there had been a matter of uncertainty about the safety of using MMC in RK because increased permeability of the cornea for MMC due to deep RK incisions could cause excessive toxicity to the eye.<sup>[18]</sup> Notwithstanding, use of MMC for 60 s in a study and up to 40 s in another caused no endothelial cell loss after 1 year.<sup>[18,21]</sup>

In our study, 23% of patients achieved 20/20 UDVA, and 84% achieved 20/40. Such findings are in correspondence to other reports, in which a UDVA of 20/40 or better was observed in 70%,<sup>[19]</sup> 65%,<sup>[11]</sup> 82%,<sup>[9]</sup> 96%,<sup>[13]</sup> and 91%.<sup>[12]</sup>

In our study, over 61% of patients gained 1 line or more of CDVA, 29% had no change, and about 10% lost 1 line or more at 6 months of follow-up. This is in line with previous studies in which 68% of eyes gained at least 1 line after 1 year.<sup>[19]</sup> In studies on hyperopic LASIK, this value was 16%, 20%, 24%, 30%, and 56%.<sup>[8,9,11-13]</sup> Regarding the above-mentioned reports, the relative favorable safety profile PRK against LASIK may be due to the absence of flap-related complications.<sup>[19]</sup>

It is crucial for practitioners to warn their patients about the fact that refractive instability may still progress regardless of the use of the laser method of vision correction. Indeed, patients and practitioners should be aware that refractive correction is not in deal with the cornea structural stabilization.<sup>[20]</sup> In spite of an early reduction in hyperopia with corrective methods, hyperopic changes are shown to persist in most of the cases; and in this regard, factors that might play role are RK-induced progressive central corneal flattening, alterations in the lens, and post-PRK corneal healing.<sup>[21]</sup>

## CONCLUSION

This was the largest clinical study to have been undertaken on the management of post-RK refractive errors. PRK

seems to bring favorable outcome and safety profile in the management of post-RK hyperopia and astigmatism.

### Acknowledgment

We are grateful to Mr. Hossein Heidarian and Mr. Mohammad-Hassan Kargar for their kind helps.

### Financial support and sponsorship

This study was supported by Isfahan University of Medical Sciences (research project number: 393775).

### Conflicts of interest

There are no conflicts of interest.

### REFERENCES

- Radial keratotomy for myopia. American Academy of Ophthalmology. *Ophthalmology* 1993;100:1103-15.
- Sugar A. Has radial keratotomy finally come of age? *Ophthalmology* 1993;100:979-80.
- Waring GO 3<sup>rd</sup>, Moffitt SD, Gelender H, Laibson PR, Lindstrom RL, Myers WD, et al. Rationale for and design of the National Eye Institute Prospective Evaluation of Radial Keratotomy (PERK) Study. *Ophthalmology* 1983;90:40-58.
- Waring GO 3<sup>rd</sup>, Lynn MJ, McDonnell PJ. Results of the prospective evaluation of radial keratotomy (PERK) study 10 years after surgery. *Arch Ophthalmol* 1994;112:1298-308.
- McDonnell PJ, Garbus JJ, Salz JJ. Excimer laser myopic photorefractive keratectomy after undercorrected radial keratotomy. *Refract Corneal Surg* 1991;7:146-50.
- Jory WJ. Predictability of radial keratotomy after excimer laser photorefractive keratectomy. *J Cataract Refract Surg* 1998;24:312-4.
- Kwitko ML, Jovkar S, Yan H, Atas M. Radial keratotomy for residual myopia after photorefractive keratectomy. *J Cataract Refract Surg* 1998;24:315-9.
- Afshari NA, Schirra F, Rapoza PA, Talamo JH, Ludwig K, Adelman RA, et al. Laser *in situ* keratomileusis outcomes following radial keratotomy, astigmatic keratotomy, photorefractive keratectomy, and penetrating keratoplasty. *J Cataract Refract Surg* 2005;31:2093-100.
- Attia WH, Alió JL, Artola A, Muñoz G, Shalaby AM. Laser *in situ* keratomileusis for undercorrection and overcorrection after radial keratotomy. *J Cataract Refract Surg* 2001;27:267-72.
- Forseto AS, Nosé RA, Francesconi CM, Nosé W. Laser *in situ* keratomileusis for undercorrection after radial keratotomy. *J Refract Surg* 1999;15:424-8.
- Francesconi CM, Nosé RA, Nosé W. Hyperopic laser-assisted *in situ* keratomileusis for radial keratotomy induced hyperopia. *Ophthalmology* 2002;109:602-5.
- Lyle WA, Jin GJ. Laser *in situ* keratomileusis for consecutive hyperopia after myopic LASIK and radial keratotomy. *J Cataract Refract Surg* 2003;29:879-88.
- Oral D, Awwad ST, Seward MS, Bowman RW, McCulley JP, Cavanagh HD. Hyperopic laser *in situ* keratomileusis in eyes with previous radial keratotomy. *J Cataract Refract Surg* 2005;31:1561-8.
- Chan CC, Rootman DS. Localized midperipheral corneal steepening after hyperopic LASIK following radial keratotomy. *Cornea* 2003;22:679-83.
- Ghanem RC, Ghanem MA, Bogoni A, Ghanem VC. Corneal ectasia secondary to LASIK after arcuate keratotomy. *J Refract Surg* 2013;29:426-9.
- Perente I, Utine CA, Cakir H, Yilmaz OF. Complicated flap creation with femtosecond laser after radial keratotomy. *Cornea* 2007;26:1138-40.
- Myrowitz EH, Kurwa A, Parker J, Chuck RS. Wavefront-guided photorefractive keratectomy after radial keratotomy in nine eyes. *J Refract Surg* 2009;25:470-2.
- Anbar R, Malta JB, Barbosa JB, Leoratti MC, Beer S, Campos M. Photorefractive keratectomy with mitomycin-C for consecutive hyperopia after radial keratotomy. *Cornea* 2009;28:371-4.
- Ghanem RC, Ghanem VC, de Souza DC, Kara-José N, Ghanem EA. Customized topography-guided photorefractive keratectomy with the MEL-70 platform and mitomycin C to correct hyperopia after radial keratotomy. *J Refract Surg* 2008;24:911-22.
- Sher NA, Golben MP, Bond W, Trattler WB. A retrospective review of photorefractive keratectomy to enhance earlier radial keratotomy. *Int Ophthalmol Clin* 2011;51:39-49.
- Ghanem RC, Ghanem VC, Ghanem EA, Kara-José N. Corneal wavefront-guided photorefractive keratectomy with mitomycin-C for hyperopia after radial keratotomy: Two-year follow-up. *J Cataract Refract Surg* 2012;38:595-606.
- Clausse MA, Boutros G, Khanjian G, Wagner C, Garabet AL. A retrospective study of laser *in situ* keratomileusis after radial keratotomy. *J Refract Surg* 2001;17 2 Suppl: S200-1.
- Joyal H, Grégoire J, Faucher A. Photorefractive keratectomy to correct hyperopic shift after radial keratotomy. *J Cataract Refract Surg* 2003;29:1502-6.
- Razmjou H, Khalilian A, Peyman A, Abtahi SH, Abtahi MA, Akbari M, et al. Preoperative topical diclofenac and ketorolac in prevention of pain and discomfort following photorefractive keratectomy: A randomized double-masked placebo-controlled clinical trial. *Int J Prev Med* 2012;3 Suppl 1:S199-206.